



Sonographic Dimension of Fetal Nuchal Translucency in Kano Metropolis: A single Center Study

*Abba M.¹, J.A. Aisha¹, & M. Barde¹

¹Department of Medical Radiography, Faculty of Allied Health Sciences, College of Health Science, Bayero University, Kano.

*Corresponding Author: *Mohammed Abba*

Corresponding Email: *mabba.radg@buk.edu.ng*

Abstract

Background: Nuchal Translucency Thickness (NTT) is a hypo-echoic region of subcutaneous fluid accumulation in the posterior neck region at the level of the cervical spine between the skin and soft tissues and is mostly found at 11–13 weeks of fetal gestation. It is visualised with a mid-sagittal ultrasound view of the fetus in a neutral position. The NTT provides a risk assessment for chromosomal abnormalities which has been used as a marker of possible fetal abnormalities. Hence, the justification to conduct the present study. **Aim:** To establish the mean fetal nuchal translucency thickness with corresponding gestational age (GA) and to assess the correlation between Crown Rump Length (CRL), GA, and NTT among apparently healthy pregnant women. **Methods:** A cross-sectional study was conducted among 150 apparently normal consenting pregnant women in their late first trimester in the Radiology department of Muhammad Abdullahi Wase Teaching Hospital, Kano from February 2021 to May 2021. Ultrasonographic measurements of the crown-rump length (CRL), gestational age (GA), and NTT were performed on pregnancies within 11 to 13 weeks of gestation. Their 2.5th, 25th, median and 97.5th percentiles of the NTT, GA, and CRL were determined using SPSS version 23 (IBM, 2017). Indicate correlation... as part of the analysis. **Results:** Median NTT at 11-13+6 weeks of gestation was found as 3.0±0.10mm. The NT thickness increased with increasing CRL and gestational week in the first trimester. The correlation coefficient between NTT and CRL as well as GA were 0.472 and 0.451, respectively. **Conclusion:** The overall mean NTT in Kano fetuses was determined. These should be useful for first-trimester screening in ruling out potential fetal chromosomal abnormalities in Kano, Nigeria.

Keywords: *Crown-Rump Length, Gestational Age, Nuchal Translucency thickness, USS*

DOI: <https://dx.doi.org/10.4314/bjnhc.v4i1.7>

Introduction

Fetal nuchal translucency thickness (NTT) refers to the sonographic appearance of subcutaneous fluid in the posterior fetal neck at the level of the cervical spine within 10-14 weeks of gestation (Nafziger & Vilensky, 2014, Niknejadi & Haghighi, 2015). It is defined as the maximal thickness of the sonolucent zone between the inner aspect of the fetal skin and the outer aspect of the soft tissue overlying the cervical spine or the occipital bone. The measure of liquid is estimated during a nuchal translucency ultrasound scan between the 11th and 14th weeks of gestation (Niknejadi & Haghighi,

2015). At the point when the crown-rump length (CRL) is between 45-84mm, all the developing fetuses had liquid at the rear of their neck. The accuracy of NTT measurement is dependent upon the gestation period and plane of image accusation which should be in a mid-sagittal ultrasound view of the fetus and in a neutral position (fetal neck flexion decreases and neck extension increases translucency) (Nafziger ., 2014).

The first trimester covers the period from conception to the end of the 13th menstrual week. This is a time of dynamic growth, differentiation, and development of most

organs. The embryo has the greatest risk of mal-development, injury and death during this period because of external factors such as infection, drugs, radiation, and chromosome aberration tendencies (Nafziger & Vilensky, 2014, Niknejadi & Haghighi 2015). Numerous fetuses with chromosomal, heart, or abdominal deformities have reported an increase in their nuchal fluid (Khair, 2019). Thus, fetal nuchal translucency thickness (NTT) has easily been related to some chromosomal and fetal variations (Junich ., 2012). The presence of a thickened NTT, even if the karyotype is normal, can be associated with structural abnormalities (Niknejadi & Haghighi 2015). Having an abnormal screening of NTT, parents, and physicians could face a dilemma over abortion, particularly in a case of invitro fertilization or intracytoplasmic sperm (ICSI) fetuses. Similarly, patients presenting with vaginal bleeding or pelvic pain in early pregnancy require urgent and accurate diagnosis (Brant, 2001).

Due to its numerous advantages ranging from relative availability, affordability and non-ionizing radiation, Ultrasonography (US) has a popular application in obstetrics and gynecology (Callen 2011). It has a tremendous impact on patient care, as it allows imaging of the fetus, placenta, and maternal internal organs with such clarity to allow advanced diagnosis and also to guide various lifesaving interventions (Khair, 2019). Ultrasound is used as the first-line imaging modality for determining and evaluating NTT. In conjunction with maternal age, NTT has been established across different populations across the world as an indicator of risks of chromosomal defects (Newey ., 2003, Sharifzadeh ., 2015).

To establish the mean fetal nuchal translucency thickness with corresponding gestational age (GA) and to assess the correlation between Crown Rump Length (CRL), GA, and NTT among apparently healthy pregnant women.

Despite the establishment of NTT measurement as a tool for screening fetal chromosomal aberrations, its popularity and application vary within different societies (Park et al., 2016). In our society, however, there is an obvious paucity of its application. Added to that, the inadequacy of trained manpower to undertake genetic counseling, screening, and follow-up diagnostic procedures when necessary further compounds the existing problem. Thus leaving innocent victims unattended. Using the transabdominal ultrasound approach, this study aims to establish the mean fetal nuchal translucency thickness with corresponding gestational age (GA) and to assess the correlation between Crown Rump Length (CRL), GA, and NTT among apparently healthy pregnant women.

Methods and Materials

This was a cross-sectional and prospective study among apparently normal pregnant women from January 2020 to June 2021. Only consenting women that were in their 11th to 13th week of gestation who reported for routine obstetrics and gynecology ultrasound examination in the radiology department of Muhammad Abdullahi Wase Teaching Hospital, Kano, Kano state were recruited. Ethical clearance to conduct the study was sought from the Kano state human research and ethics committee with reference number: MOH/Off/797/T.I/2174. Purposive sampling was used to conveniently recruit potential participants. Any pregnancy with history, suspicious or abnormal fetal or maternal anomaly, abnormal fetal position, or gestational age outside the scope of the study were all excluded.

The obstetric ultrasound examination was performed with an optimal full urinary bladder with the participants in the supine position on the ultrasound couch. A [Mindray (DC-3) - China] diagnostic ultrasound machine with 3.5 MHz transducer which were manufactured in April 2012 was used for the examination.

The measurement of NTT was strictly according to the guidelines issued by Fetal Medicine Foundation (FMF) criteria (Nicolades, 2004). Conditions that must be met include: CRL of 45–84 mm (corresponding to 11weeks-13weeks GA); mid-sagittal plan; image magnified until the fetal head and trunk occupy at least 75% of the screen; calipers calibrated to 0.1 mm; fetus in the neutral position; a clear distinction between fetal skin and an amniotic membrane is ensured; NTT was measured as the maximum thickness of the anechoic space between the skin and subcutaneous tissue that covers the spine (Nicolaidis, 2004). Measurement was performed by a qualified Sonographer with postgraduate and professional qualifications in ultrasonography. For the sake of reproducibility, internal consistencies were assessed using Intra class

correlation (ICC) and a Cronbach's alpha of 0.88 was obtained. Other technical aspects prior to taking measurement include, margins of NTT are ensured with good contrast. Horizontal crossbars of calipers are placed perpendicular to the long axis of the fetus and on the NTT lines (Figure 1). Following normality testing, most of the data were normally distributed. Hence, data were expressed as mean and standard deviation. The values of NTT were expressed in percentiles and compared with their corresponding GA. The correlation between CRL and GA with NTT was assessed using Pearson's correlation. The level of significance was set at less than 0.05. Analysis was done using SPSS for IBM version 21.

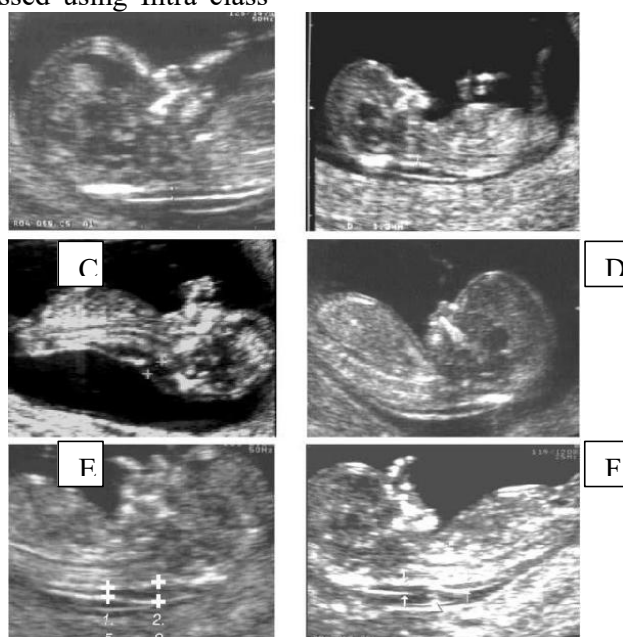


Fig. 1: Sonogram of a 12 weeks fetus (a-f). Good fetal sagittal section (A-F), nuchal membrane separate from the amniotic membrane (A-F), fetal neck hyper-extended (B, C, E), and cursors placed at the fluid-membrane interface (A, E, F).

Results

One hundred and fifty (150) pregnant women that satisfied the inclusion criteria were recruited. Maternal age ranged from 16-45

years with an overall mean age of 26 ± 5.41 years. Participants were grouped into age categories. The age group with the highest age group was 21-25 years and the least was 36 years and above (Figure 2).

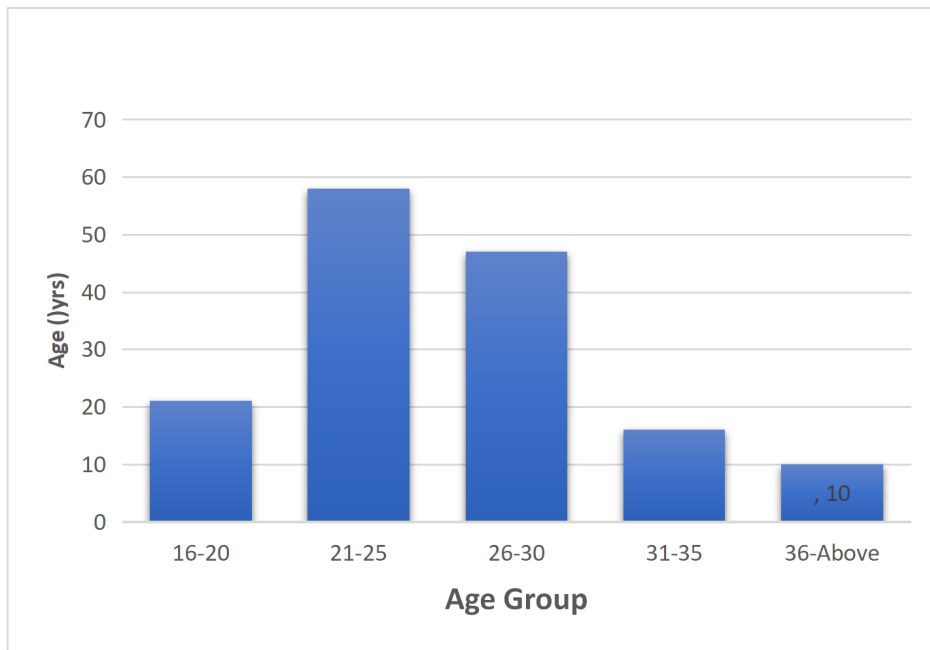


Figure 2: Participants' frequency distribution based on age group

The mean values of maternal age (years), CRL (mm), NTT (mm), and GA (weeks) with their standard deviations (SD) is presented in table 1.

Table 1: Mean and standard deviation for maternal age, crown-rump length, nuchal trans. thickness and gestational age

S/N	Statistics	MA (Years)	CRL (mm)	NTT (mm)	GA (weeks)
1	Mean	26	60	3	12
2	±SD	5.41	1.10	0.10	0.73

Key: MA: Maternal Age, CRL: Crown Rump Length, NTT: Nuchal Translucency Thickness, GA: Gestation Age

Similarly, the percentile distribution of NTT was also determined and compared with the corresponding GA. The 2.5th, 25th, 50th, 75th, and 97.5th indicated consistent linear patterns across the scale (Table 2).

Table 2: Percentile distribution of NTT with corresponding gestational age

S/N	Percentiles	NTT	GA
1	2.5	1.3	11
2	25	2.2	12
3	50	3.0	12
4	75	3.6	13
5	97.5	4.7	13

Key: NTT: Nuchal Translucency Thickness, GA: Gestation Age

Similarly, the correlation between NTT and CRL with their corresponding GA was assessed using Pearson's Correlation

Coefficient. A significant but weak correlation was observed between the variables (Table 3).

Table 3: Correlation between CRL and NT thickness

Statistic	CRL & NTT	GA & NTT
Correlation Coefficient (<i>r</i>)	0.472	0.451
Level of Significance (<i>p</i>)	0.001	0.001

Key: CRL: Crown Rump Length, NTT: Nuchal Translucency Thickness, GA: Gestational Age

Discussion

Several reports from different parts of the world and Nigeria have demonstrated the utility of NTT measurement for screening different chromosomal and non-chromosomal abnormalities (Chung et al., 2003, Oloyede et al., 2014, Eze et al., 2020, Sulaiman et al., 2020). Most of these studies have used the recommended definition for NTT by the fetal medicine foundation (Nicolades, 2004). The present study revealed the overall mean NTT of 3.0 mm. This is almost similar to a finding reported by Olufemi ., (2014) in Ogun state, Nigeria, where they reported a mean NTT of 2.2mm. Similarly, the median of NTT of a CRL value within 45 mm – 80 mm was lower than findings reported in Korea (Chung ., 2003), Japan (Junich ., 2012), and Brazil (Júnior ., 2014). However, this subtle variation may be attributed to either ethnic, geographic, or methodological differences between the studies.

The 97.5th percentile NTT from the present study was 4.7mm. Whereas, the 95th percentile NT thickness has been reported to be 2.1-3.2 mm, 2.14-2.3 mm, 1.57-2.10 mm, 1.00-2.90 mm, and 1.84-2.35 mm for a CRL between 45 mm and 80 mm in Japan, Korea, Brazil, Thailand, and China, respectively. Reported variations in the index measurements in the different studies might have been due to factors such as the Sonographers experience, technical parameters utilized while performing the ultrasound, measurement method, and an inappropriate fetal and nuchal cord position. In addition, as mentioned by Sharifzadeh . (2015) in Iran some investigators have considered the average of two or three measurements of NT thickness, whereas others considered the largest measurement.

The 97.5th percentile NTT from the present study was revealed to be 4.7mm. For a CRL that ranged between (45-80) mm, studies have reported the 95th percentile NTT range of (2.1-3.2) mm, (2.14-2.3) mm, (1.57-2.10) mm, (1.00-2.90) mm, and (1.84-2.35) mm in Japan, Korea, Brazil, Thailand, and China, respectively. The reason for these variations could be on account of numerous factors such as radiologist or sonographers experience, the image quality of the ultrasound scanner (gain setting, route of ultrasound fetal assessment, frequency and type of transducer used), method of measurement, and use inappropriate fetal and nuchal cord position (Sharifzadeh ., 2015). All these factors could explain the differences across various regions (Sharifzadeh ., 2015).

The present study revealed a significant but weak positive correlation between fetal NTT and CRL. This demonstrates at certain stage, fetal NTT increases with CRL (Jou et al., 2001, Sharifzadeh ., 2015). This is further supported by Spaggiari et al., (2016) that highlighted the use of a fixed cut-off value in NTT as misleading and recommends assessment NTT based on CRL (Spaggiari, et al., 2016). Factors known to affect CRL may include fetal age, maternal nutritional status, parity and psychosocial status among others. These factors could also affect NTT. Thus, the present study explored the correlation of CRL with fetal NTT and not gestational age for obvious reasons; the reliability of LMP in the study area is highly unreliable as most respondents are not sure of an accurate date. Secondly, the convenience of concurrently measuring NTT and CRL at the same time further justifies the use of CRL.

The present study revealed a significant but weak positive correlation between GA and NTT. Jou ., (2001) demonstrated a similar

finding and highlighted an increasing false positive rate with increasing GA in a low-risk Asian population. Thus, the use of a single cut-off value of NTT may be misleading at a particular GA and may require to further explore the CRL measurement also.

The paucity of documented fetal chromosomal abnormalities is largely due to the absence of reliable monitoring data. This study has therefore provided a baseline NTT thickness suitable for use in the study locality to the best of researchers' knowledge is not available. Furthermore, its relationship with other compounding factors has also been highlighted.

The relatively smaller sample size used and being a single-center study may limit the generalization of the findings of the study. However, the findings are still relevant and could form a basis for a further large-scale population study of the most populated state in Nigeria.

Conclusion

Existing NTT values used for diagnosis were from the Caucasian population which has been shown to vary across regions. This study reports mean NTT values specific to the study population.

Furthermore, NTT is not a reliable predictor of GA and will require the use of CRL for a more precise prediction. Nonetheless, NTT can be used as a reliable index to identify and monitor fetuses with chances of chromosomal abnormalities using the local values peculiar to the study population.

Conflict of Interest

The authors declare openly the absence of any conflict of interest during the entire course of the study.

References

Brant, W. E. (2001). Core Curriculum Ultrasound. Lippincott Williams & Wilkins. 530 Walnut Street, Philadelphia, PA 19106 USA

- Callen, P.W., 2011. Ultrasonography in Obstetrics and Gynecology E-Book. Elsevier Health Sciences.
- Chung, J.-H., Jae-Hyug, Y., Mi-Jin, S., Jeong-Yeon, C., Young-Ho, L., So-Yeon, P.,& Hyun-Mee, R. (2003). The distribution of fetal nuchal translucency thickness in normal Korean fetuses.pdf. *Journal of Korean medical sciences*, 19(1); 32-36.
- Eze, C. U., Okenwa, S. N., Obinna Abonyi, E., Agbo, J. A., Onwuzu, S. W. I., & Nwadike, I. U. (2020). Normal Reference Range of Fetal Nuchal Translucency Thickness Among Pregnant Women of Igbo Extraction in Enugu, South-East Nigeria. *Research Square*, (1):1-15
- Junich, H., Masamitsu, N., Shoko, H., Ryu, M., Kiyotake, I., Akihiko, S., & Takashi, O. (2012). Distribution of nuchal translucency thickness. *Journal of Obstetrics and Gynaecology Research*, 39(4): 766-769.
- Júnior, E.A., Pires, C.R., Martins, W.P., Nardoza, L.M.M. and Zanforlin Filho, S.M., 2014. Reference values of nuchal translucency thickness in a Brazilian population sample: experience from a single center. *Journal of Perinatal Medicine*, 42(2):255-259.
- Khair, S. M. O. M. (2019). Variation of nuchal translucency measurements in first trimester.pdf. *European journal of biomedical and pharmaceutical sciences* 6(2):524-527.
- Nafziger, E., & Vilensky, J. A. (2014). The anatomy of nuchal translucency at 10-14 weeks gestation in fetuses with trisomy 21: An incredible medical mystery. *Clinical anatomy (New York, N.Y.)*, 27(3), 353-359
- Newey, V. R., Nassiri, D. K., Bhide, A., & Thilaganathan, B. (2003). Nuchal translucency thickness measurement: repeatability using a virtual ultrasound scanner. *Ultrasound in obstetrics & gynecology: the official journal of the*

- International Society of Ultrasound in Obstetrics and Gynecology, 21(6): 596–601.
<https://doi.org/10.1002/uog.124>
- NICOLAIDES, K., 2004. The 11-13⁺ 6 weeks scan. Fetal Medicine Foundation, London. <http://www.fetalmedicine.com/pdf/11-14/english/FMF-English.pdf>.
- Olufemi Adebari, O., Mkpe, A., Adeniyi Adebawale, O., & Onyinye, N. (2014). Fetal nuchal translucency scan in Nigeria. *Pan African Medical Journal*, 18. <http://www.panafrican-med-journal.com>
- Oloyede, O. A., Abbey, M., Oloyede, A. A., & Nwachukwu, O. (2014). Fetal nuchal translucency scan in Nigeria. *The Pan African Medical Journal*, (18): 62.
- Park, S. Y., Jang, I. A., Lee, M. A., Kim, Y. J., Chun, S. H., & Park, M. H. (2016). Screening for chromosomal abnormalities using combined test in the first trimester of pregnancy. *Obstetrics & Gynecology Science*, 59(5): 357-366.
- Niknejadi, M., & Haghghi, H. (2015). Chromosomally and Anatomically Normal Fetuses With Increased First Trimester Nuchal Translucency Conceived by ICSI. *Iranian journal of radiology: a quarterly journal published by the Iranian Radiological Society*, 12(2):7157.
<https://doi.org/10.5812/iranradiol.7157>
- Sharifzadeh, M., Adibi, A., Kazemi, K., & Hovsepian, S. (2015). Normal reference range of fetal nuchal translucency thickness in pregnant women in the first trimester, one center study. *Journal of research in medical sciences: the official journal of Isfahan University of Medical Sciences*, 20(10), 969.
- Spaggiari, E., Czerkiewicz, I., Sault, C., Dreux, S., Galland, A., Salomon, L. J., ... & Muller, F. (2016). Impact of including or removing nuchal translucency measurement on the detection and false-positive rates of first-trimester down syndrome screening. *Fetal Diagnosis and Therapy*, 40(3), 214-218.
- Sulaiman, B., Shehu, C. E., Panti, A. A., Saidu, S. A., Onankpa, B., & Ekele, B. A. (2020). Prevalence and outcome of increased nuchal translucency in usmanu danfodiyo university teaching hospital, Sokoto, Nigeria: A cohort study. *Nigerian Journal of Clinical Practice*, 23(6), 864-869.