

Atrio ventricular block and COVID 19 infection

Bloc atrio ventriculaire et infection par COVID 19

Hanane Zouzou

Cardiology Department, Batna University Hospital - Algeria

Corresponding author:

Hanane ZOUZOU

hanane_zouzou@yahoo.fr

DOI :<https://doi.org/10.48087/BIMScr.2022.S912>

Received : Marsh 23, 2021

Accepted : October 10, 2021

Published : January 25, 2022

This is an open access article distributed under the terms of the Creative Commons Attribution International License ([CC BY 4.0](https://creativecommons.org/licenses/by/4.0/)), which permits unrestricted use, distribution, and reproduction in any medium or format, provided the original author and journal are appropriately credited.

ABSTRACT

Several degrees of Atrio-Ventricular Block, have been reported, in some patients with corona virus disease 2019 (COVID-19) infection, we report three cases of female patients referred to our center for implantation of pacemaker, because of Atrio Ventricular block. The diagnostic of COVID-19 infection has been made before the diagnostic of Atrio Ventricular block for one patient, and after implantation for the two others.

Key words: Atrio-Ventricular Block; COVID-19; Bundle Branch Block.

RÉSUMÉ

Différents degrés de Bloc auriculo-ventriculaire ont été rapportés chez certains patients présentant une infection à Coronavirus 19 (COVID-19). Nous rapportons les cas de trois patientes orientées vers notre centre pour implantation de pacemaker, à cause du bloc auriculo ventriculaire. Le diagnostic de l'infection COVID-19 a été posé avant l'implantation du pacemaker chez une patiente et après l'implantation pour les deux autres.

Mots clés : Bloc Auriculo Ventriculaire, COVID -19, Bloc de Branche.

BACKGROUND

Corona virus disease 2019 infection exhibits a tropism for the respiratory tract, however several cardiac damages have been reported, such as coronary artery disease, myocarditis, and cardiac arrhythmias.

Atrio Ventricular Block has been reported, but its mechanism isn't clear; assessment of its prognosis, requires long-term follow-up.

CASE 1

An 81-year-old, female patient, with past medical history of hypertension, she has been on Amlodipine treatment, she had cataract surgery seven months ago, and she had a normal surface ECG.

In the 5th of august, she presented, dizziness, asthenia with fever, and cough; she was hypoxemic with an oxygen saturation of 85% on room air. Chest radiography revealed interstitial pulmonary syndrome.

High-resolution chest computed tomography scan, showed severe lung damage, and with multiple patchy ground glass opacity (GGO). CT severity index of COVID-19 pulmonary infection was more than 75 %. She had inflammatory test abnormalities (elevated erythrocytes sedimentation rate: 50/98, C reactive protein: 42 mg/l, Fibrinogen 5.15 g/l).

COVID-19 nasal swab reverse transcription polymerase chain reaction (RT-PCR) tested positive for the infection.

The diagnostic of COVID-19 infection has been maintained, and ECG tracing performed before instauration of Hydroxychloroquine (Plaquenil) treatment, showed Complete Atrio Ventricular Block (CAVB) with ventricular frequency was about 45 beats /min. (**Figure 1**), so she was referred to our centre for pace maker implantation in the 9th of august 2020. Echocardiography showed normal left ventricular ejection fraction.

High-sensitivity Troponin-T and electrolytes were within normal limits.

Citation :

Zouzou H. Atrio ventricular block and COVID 19 infection. Batna J Med Sci. 2022;9(S1):4-7.<https://doi.org/10.48087/BIMScr.2022.S912>

A single chamber pacemaker was implanted to her, one week after implantation, her clinical status has improved, and after

three months, she had a persistent complete AV block with paced rhythm (Figure 2).

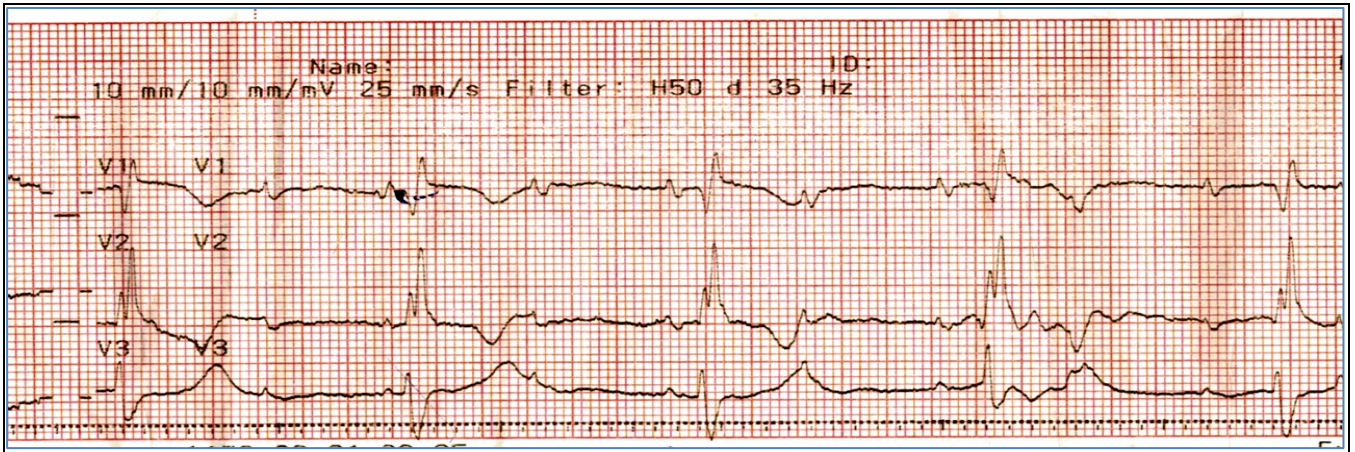


Figure 1. Surface ECG of first patient at admission, showed complete AVB. AVB: Atrio Ventricular block

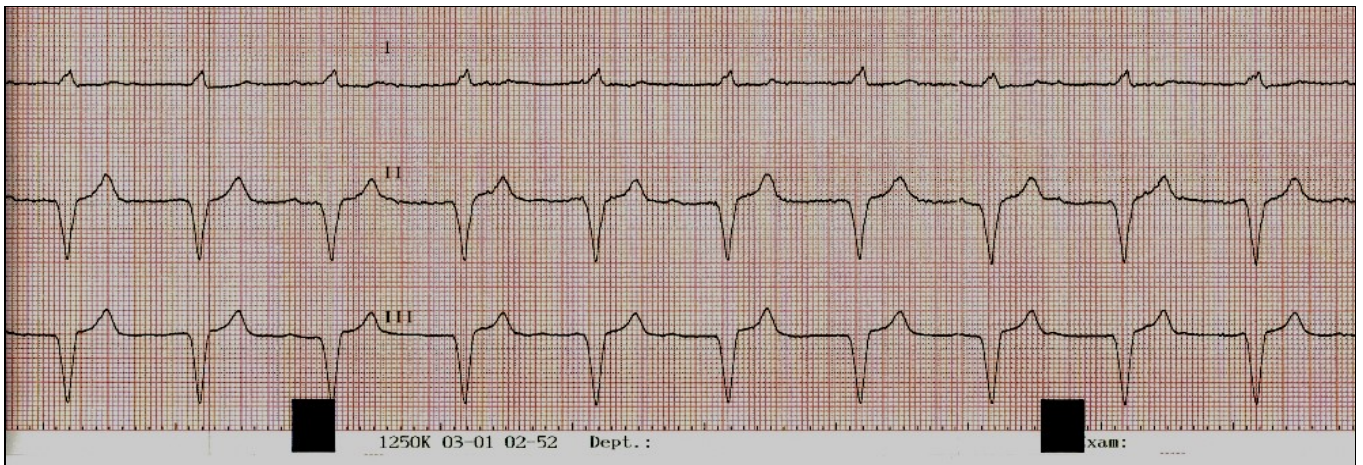


Figure 2. Surface ECG of first patient after implantation showed Paced rhythm.

CASE 2

A 66-year-old, female patient, with past medical history of type II diabetes mellitus, she has been on oral anti diabetic medications for 10 years, admitted in our cardiology department for syncope, in the 7th of September 2020.

She also presented fever, and cough, for one week, she had an oxygen saturation of 98 % on room air, but her surface ECG showed sinus rhythm, with complete right bundle branch block and left anterior hemi block (Figure 3).

On the first day of hospitalization, she experienced several episodes of syncope and surface ECG, showed paroxysmal AV block (Figure 4).

A single chamber pacemaker was implanted to her on the

same day. She had inflammatory test abnormalities (elevated erythrocytes sedimentation rate: 49; C reactive protein: 7.3 mg/l, Fibrinogen 4.72 g/l), but High-sensitivity Troponin-T and electrolytes were within normal limits. High-resolution chest computed tomography scan wasn't performed for this patient.

Echocardiography showed normal left ventricular ejection fraction, PCR was negative, but one month after implantation, serology tests for COVID 19 were positive (IgG > 2.99AU/ml and IgM > 1.56 AU/ml), so we concluded that she had the covid-19 infection, at the same time as paroxysmal AV Block.

Three months after pacemaker implantation, she had spontaneous sinus rhythm with persistent complete right bundle branch block and left anterior hemi block.

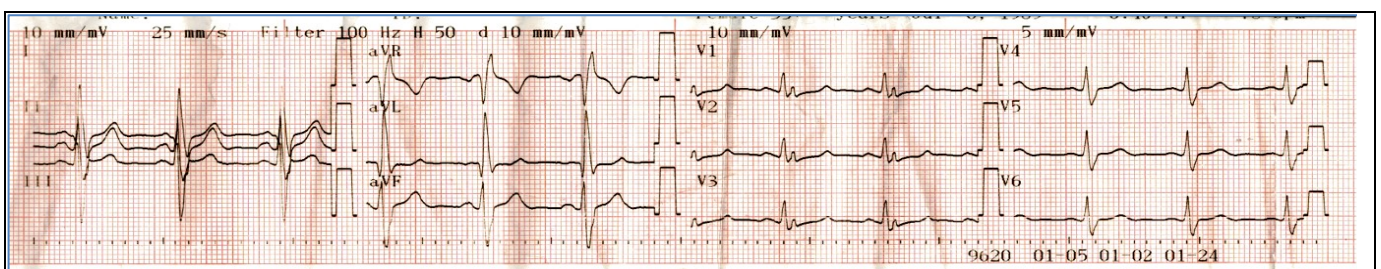


Figure 3. Surface ECG of the second patient, showed complete right bundle branch bloc and left anterior hemi block.

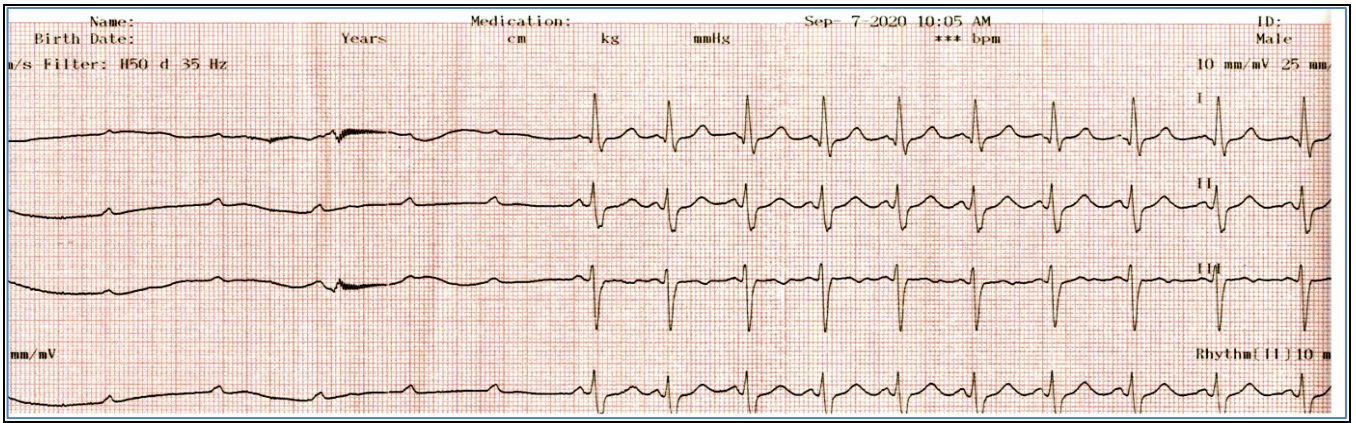


Figure 4. Surface ECG of the second patient, showed paroxysmal Atrio-Ventricular Block.

CASE 3

A 71-year-old, female patient, with past medical history of bronchial asthma and type II diabetes mellitus, she has been on oral anti diabetic medications for 4 years, she was admitted in our cardiology department for syncope, in the 7th of September 2020, in the same day as the second patient.

She reported that last month, she suffered from shortness of breath, cough and fever, but she didn't visit the doctor.

At admission her surface ECG, showed paroxysmal 2/1 AV block, and complete left bundle branch block (Figures 5 and 6).

Inflammatory tests (C reactive protein: 2.1 mg/l, Fibrinogen 3.07 g/l), High-sensitivity Troponin-T, and electrolytes were within normal limits, but serology tests for COVID 19 were positive (IgG/IgM > 13).

Le diagnosis of COVID-19 infection was maintained, because of clinical manifestations one month before AV block occurrence, with positive serology result.

Echocardiography showed normal left ejection fraction. She was implanted with single chamber pacemaker, on the first day of her hospitalization.

Three months after implantation, she had spontaneous sinus rhythm with persistent complete left bundle branch block.

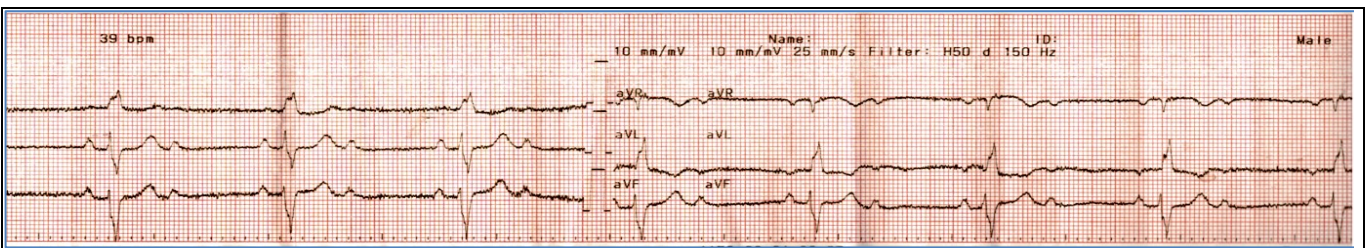


Figure 5. Surface ECG of the third patient, showed paroxysmal 2/1 Atrio-Ventricular Block.

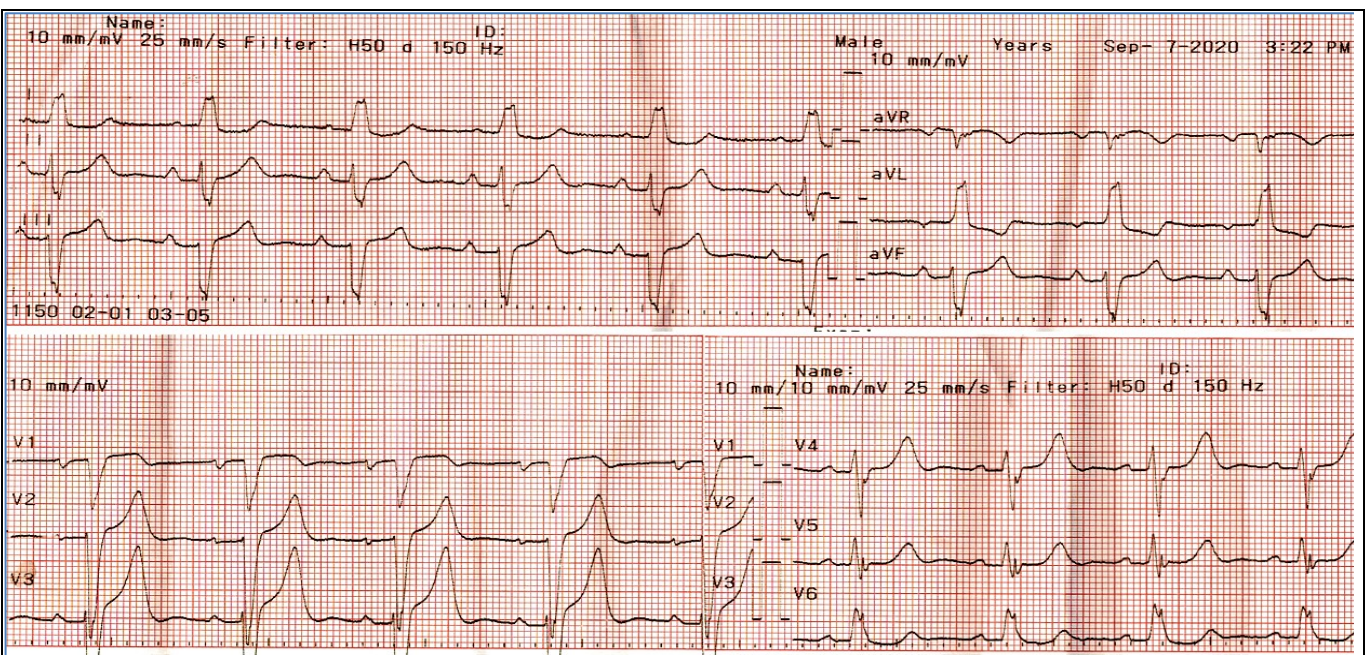


Figure 6. Surface ECG of the third patient, showed complete left bundle branch block.

DISCUSSION

COVID-19 is a pandemic viral infectious disease; first cases were recorded in China, in December 2019 [1], and then spread globally all over the world. The disease was announced as pandemic by the World Health Organization in March 2020.

Several organ damage, have been reported in COVID-19 infection, including kidney failure, liver and heart injury, implying multiple organ involvement [2, 3, 4].

Cardiac damage has been reported in up to 19.7% of patients with COVID-19 [4, 5], arrhythmia has been noted in 16.7% of patients. [6]. The new onset AV block, have been reported, [7, 8, 9, 10] but the mechanisms are not clear.

In general population, the most common causes of AV block include degeneration of conduction system, infection, ischemia, inflammation, electrolytes abnormalities, and medications.

In the setting of SARS-CoV-2 infection, several causes are possible, such as hypoxemia, micro embolism, electrolytes abnormalities, drugs, and inflammatory surge from the cytokine storm or direct invasion of system conduction by COVID-19 virus, via Human angiotensin-converting enzyme 2 (ACE2) that provides a direct binding site for the S proteins of the SARS-CoV-2, and facilitates its cell entry [11].

For our first patient, the surface ECG was normal, 6 months before infection, Amlodipine is a calcium channel blocker with no effect on the cardiac conduction system, also neither Troponin elevation nor ventricular dysfunction was associated with AV block, but hypoxemia and inflammatory surge are the most likely causes of Atrio ventricular block, the block was permanent, may be because of extensive damage of her cardiac conduction system.

For the second patient, the diagnosis of COVID-19 infection was made retrospectively, after a positive serology result; like the first patient, AV block may be related to inflammation, and even more, AV block was temporary and has regressed with only persistence of complete right bundle branch block, so we believe that COVID 19 infection may worsen pre-existing conduction system disturbances.

For the third patient, the diagnosis of COVID-19 infection was maintained, because of clinical manifestations one month before AV block occurrence with positive serology result, the pathogenesis of AV block may be related to autoimmune disorders like Lyme carditis.

CONCLUSION

COVID-19 could be responsible of cardiac conduction system disorders, the mechanisms are not clear yet, continuous monitoring of cardiac rhythm is required, especially in elderly patients with past history of diabetes or hypertension.

Conflict of interest

The authors declare that they have no conflict of interests.

REFERENCES

1. Wang D, Hu B, Hu C, et al. Clinical characteristics of 138 hospitalized patients with 2019 novel coronavirus-infected pneumonia in Wuhan, China. *JAMA* 2020; 323:1061–1069. DOI: [10.1001/jama.2020.1585](https://doi.org/10.1001/jama.2020.1585)
2. Cheng, Y.; Luo, R.; Wang, K. Kidney impairment is associated with in-hospital death of COVID-19 patients. medRxiv 2020. medRxiv preprint <https://doi.org/10.1101/2020.02.18.20023242>.
3. Guan, G.W.; Gao, L.; Wang, J.W. Exploring the mechanism of liver enzyme abnormalities in patients with novel coronavirus-infected pneumonia. *Chin. J. Hepatol.* 2020, 28, E002. DOI: [10.3760/cma.j.issn.1007-3418.2020.02.002](https://doi.org/10.3760/cma.j.issn.1007-3418.2020.02.002)
4. Shi S, Qin M, Shen B, et al. Association of cardiac injury with mortality in hospitalized patients with COVID-19 in Wuhan, China. *JAMA Cardiol* 2020; e200950. DOI: [10.1001/jamacardio.2020.0950](https://doi.org/10.1001/jamacardio.2020.0950)
5. Zhou F, Yu T, Du R, et al. Clinical course and risk factors for mortality of adult inpatients with COVID-19 in Wuhan, China: a retrospective cohort study. *Lancet* 2020; 395: 1054–1062. DOI: [10.1016/S0140-6736\(20\)30566-3](https://doi.org/10.1016/S0140-6736(20)30566-3)
6. Zheng YY, Ma YT, Zhang JY, Xie X. COVID-19 and the cardiovascular system. *Nat Rev Cardiol* 2020; 17: 259–260. DOI: [10.1038/s41569-020-0360-5](https://doi.org/10.1038/s41569-020-0360-5)
7. Tala Eneizat Mahdawi, Haoyang Wang, Faris I. Haddadin, and all. Heart block in patients with coronavirus disease 2019: A case series of 3 patients infected with SARS-CoV-2. *HeartRhythm Case Rep.* 2020 Sep; 6(9): 652–656. DOI: [10.1016/j.hrcr.2020.06.014](https://doi.org/10.1016/j.hrcr.2020.06.014)
8. Faris I. Haddadin, Tala Eneizat Mahdawi, Laith Hattar and all. A case of complete heart block in a COVID-19 infected patient. *Journal of Cardiology Cases* 23 (2021) 27–30 DOI: [10.1016/j.jccase.2020.08.006](https://doi.org/10.1016/j.jccase.2020.08.006).
9. Azarkish M, Laleh Far V, Eslami M, Mollazadeh R. Transient complete heart block in a patient with critical COVID-19. *Eur Heart J* 2020;41: 2131. DOI: [10.1093/eurheartj/ehaa307](https://doi.org/10.1093/eurheartj/ehaa307)
10. El Assaad I, Hood-Pishchany MI, Kheir J, Mistry K, Dixit A, Halyabar O, et al. Complete heart block, severe ventricular dysfunction and myocardial inflammation in a child with COVID-19 infection. *JACC Case Rep* 2020 Jul 15; 2(9): 1351–1355. DOI: [10.1016/j.jaccas.2020.05.023](https://doi.org/10.1016/j.jaccas.2020.05.023)
11. Yuefei Jin, Haiyan Yang, Wangquan Ji, Review Virology, Epidemiology, Pathogenesis, and Control of COVID-19. *Viruses* 2020, 12, 372. DOI: [10.3390/v12040372](https://doi.org/10.3390/v12040372)

This article was published in the "Batna Journal of Medical Sciences" **BJMS**, the official organ of "Pharmaceutical Research Association - Batna".

The content of the Journal is Open Access and allows the reader to download, use the content for personal or teaching purposes, without seeking permission from the publisher/author.

Benefits of publishing in **BJMS**:

- Open access: once published, your article is available for free download
- Free submission: no submission fees, unlike most Open Access journals
- Possibility to publish in 3 languages: French, English, Arabic
- Quality of review: geographically independent reviewers, respecting anonymity, to guarantee the neutrality and quality of the manuscripts.

For more information, contact BatnaJMS@gmail.com or visit the journal's website: www.batnajms.net

