



ORIGINAL ARTICLE

Partial axillary dissection in early breast cancer

Tarek Abdel Halim El-Fayoumi *

Department of General Surgery, Faculty of Medicine, Alexandria University, Egypt

Received 16 October 2012; accepted 7 January 2013

Available online 7 March 2013

KEYWORDS

Breast cancer;
Axillary lymph nodes
clearance

Abstract *Background:* In order to reduce the probability of later clinical involvement of the axilla and at establishing a sound basis for adjuvant treatment planning axillary dissection is an important operative procedure. So, partial axillary dissection has been applied to decrease the morbidity and postoperative axillary complications.

Aim of the work was to study the reliability of partial axillary lymph node dissection in patients with breast carcinoma with clinically negative axilla.

Methods: Eighteen patients underwent modified radical mastectomy, while the other two patients who were fulfilling the criteria for conservative breast surgery underwent lumpectomy. All patients did complete axillary lymph nodes dissection. Intraoperative leveling of the axilla was performed and level I axillary lymph nodes were identified according to their relation to pectoralis minor muscle; then they were subjected to intraoperative pathological examination by frozen section examination followed by complete axillary clearance. Then post operative histopathological examination of the tumor and all lymph nodes was done.

Results: By intraoperative pathological examination; five patients (25%) were found positive for malignant invasion, while 15 patients (75%) were pathologically free. While paraffin section showed six patients (30%) with malignant invasion, and 14 patients (70%) were pathologically free. There was a false negative rate of 5% in level I axillary lymph nodes by intraoperative pathological examination which was positive for metastasis by paraffin section that revealed microinvasion in one lymph node out of 8 in level I. Only two cases out of 20 were found positive for metastasis in level II and III.

Conclusion: Partial axillary lymph node dissection is a minimally invasive, feasible and sufficient technique that can predict the axillary lymph node status.

© 2013 Production and hosting by Elsevier B.V. on behalf of Alexandria University Faculty of Medicine.

Abbreviations: LN, lymph node; RT, radiotherapy; IDC, invasive ductal carcinoma.

* Present address: 21 Moshir Ahmed Ismail St., Sidi Gaber, Alexandria, Egypt. Tel.: +20 35440094/0127435762.

E-mail address: tarekfayoumi@yahoo.com

Peer review under responsibility of Alexandria University Faculty of Medicine.



Production and hosting by Elsevier

1. Introduction

The trend toward less radical breast surgery was attributable to two important factors. Firstly, surgeons during the latter half of the 20th century were seeing patients with smaller tumors, and these were often amenable to local excision. Secondly, there were improvements in radiotherapy (RT) techniques, enabling tumoricidal doses to be delivered effectively

without significant damage to surrounding tissues. Thus, many surgeons developed an interest in breast-conserving surgery (BCS), undertaken in conjunction with breast RT. Surgical management of the axilla in breast cancer patients has been a subject of intense debate and controversy. The main prognostic predictor of survival in breast cancer is the axillary nodal involvement as regards the number and level of nodes in relation to pectoralis minor muscle. If there is axillary involvement, the 10-year disease-free survival rate is close to 70–80%, which falls to 35–40% with one to three positive nodes and 10–15% in the presence of more than 10 positive nodes.^{1,2}

Standard policy for management of the axilla is complete axillary dissection with removal of axillary lymph nodes below the axillary vein including levels I and II as in partial axillary dissection as well as level III dissection which involves the complete removal of all nodal tissues located medial to or above the upper border of pectoralis minor. The dissection extends superomedially to the lateral border of the first rib and costoclavicular (Halsted's) ligament, including the subclavicular group.³

This leads to axillary complications such as seroma which is the commonest postoperative complication after axillary clearance in which different causes have been involved but interruption of axillary lymphatics is highly responsible of all,^{4,5} Petrek et al.,⁶ found that the more the axillary dissection the more liability to seroma occurrence. Some authors consider seroma as "necessary evil" that occurs unpredictably.^{4,5}

Also, lymphedema of the arm may lead to functional and psychological disability and may lead to the development of cellulites and repeated infection of the upper arm.^{7,8} Dull aching pain and paresthesia are due to intercostalbrachial nerve injury. This may remain for a long postoperative period and may be improved by conservative treatment and physiotherapy.⁹ Rarely, motor injury may occur due to the thoracodorsal, long thoracic or pectoral nerves involvement and if it happens it is treated also by conservation and physiotherapy.¹⁰

Aim of the work was to study the reliability of partial axillary lymph node dissection in patients with breast carcinoma with clinically negative axilla for avoidance of postoperative complications induced from unnecessary complete axillary dissection.

2. Patients and methods

The study included 20 female patients suffering from early breast cancer (stages I and II) with clinically negative axilla. After informed patient consent, 18 patients underwent modified radical mastectomy, while the other two patients who were fulfilling the criteria for conservative breast surgery underwent lumpectomy. All patients did complete axillary lymph node dissection. Intraoperative leveling of the axilla was performed and level I axillary lymph nodes were identified according to their relation to pectoralis minor muscle; then they were subjected to intraoperative pathological examination by frozen section examination followed by complete axillary clearance. (Figs. 1 and 2) Then post operative histopathological examination of the tumor and all lymph nodes was done; regarding type, grade (including nuclear core, differentiation and mitotic index), presence of necrosis, vascular, lymphatic invasion and tumor typing are assessed according to WHO classification and Bloom and Richardson system. The results are tabulated and analyzed by

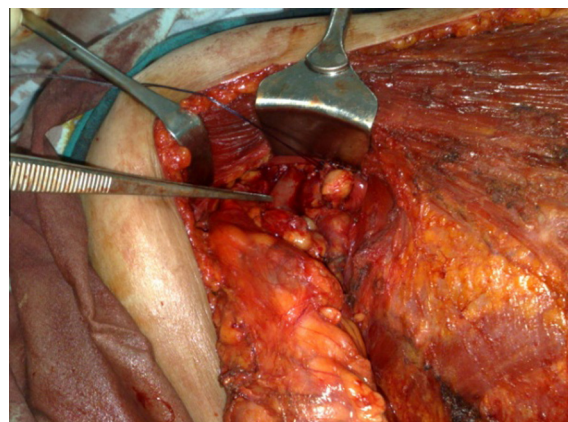


Figure 1 Intraoperative leveling of level I axillary lymph node in order to perform partial axillary dissection to be sent for frozen section before the completion of axillary clearance as a part of modified radical mastectomy in a female patient with early breast cancer.

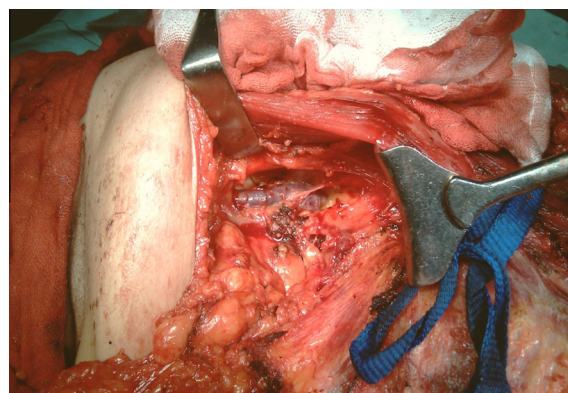


Figure 2 Showing axillary dissection as a part of modified radical mastectomy in a case of early breast cancer with identification of the axillary vein.

The Statistical Package for the Social Sciences (SPSS) software version 15 for windows. Qualitative data were analyzed using Fisher Exact and Monte Carlo tests. Also comparison between quantitative data was analyzed using Student's *t*-test and *F*-test.

3. Results

Eighteen patients were operated upon by modified radical mastectomy while only two patients were operated upon by breast conservative surgery. Histopathological type of the tumor revealed invasive ductal carcinoma not otherwise specified (NOS) in 16 patients, and invasive ductal carcinoma with predominant comedo component in four patients. According to Scarff, Bloom and Richardson classification; two patients (15%) were grade I, 14 patients (65%) were grade II, and four patients (20%) were grade III. Five patients had lympho-vascular and peri-neural invasion around the tumor and in 15 patients, the tumor was not associated with lympho-vascular invasion.

The mean number of dissected LN was 4.7 ± 2.5 ranging from 1 to 12 lymph nodes. In six patients (30%), level I was

found positive for malignant invasion while in 14 patients (70%) level I was found negative for malignancy. According to the pattern of lymph node metastasis in the six cases: two cases (33.3%) presented as microinvasion (≤ 2 mm) while four cases (66.6%) presented as macroinvasion (> 2 mm).

Intraoperative pathological examination of level I axillary LN (Imprint cytology and frozen section) revealed that 15 cases were negative and five cases were positive for metastasis. On reviewing these results by paraffin section; 14 cases were negative and six cases were positive for metastasis, this was significant **Table 1** ($X^2 = 0.88$ P value = 0.001*) only one case was failed to be detected by intraoperative pathological examination and was detected by paraffin section. This case showed: micrometastasis (≤ 2 mm), number of LN involved was only one out of eight, levels II and III were negative, histopathological criteria of the resected tumor were invasive ductal carcinoma, grade III with lymphovascular invasion.

The sensitivity of intra-operative pathological examination of level I axillary lymph nodes was 83.39%, the accuracy is 95%, the negative predictive value is 93.33%, both the specificity and positive predictive value were 100%. Levels II and III axillary LN were positive in only two cases while 18 cases were negative for metastasis.

So in summary patients were divided according to the results of intraoperative pathological examination of level I and paraffin section: first group was negative intra-operative pathology with negative paraffin section (14 cases). Second group was positive intra-operative pathology with positive paraffin section (five cases). Third group was negative intra-operative pathology with positive paraffin section (One case).

The relation between intra-operative pathological examination of level I axillary LN and paraffin section of levels II and III LNs was: 15 cases which were negative for level I were also negative for levels II and III. While out of the five positive cases for level one only two were positive for level II and III and this was significant. **Table 1** ($X^2 = 0.509$, $p = 0.012^*$). The two cases that showed metastasis in levels II and III were as follows: first case; infiltrating ductal carcinoma grade III, with four infiltrated nodes in level I and II infiltrated nodes out of nine in levels II and III. The other case was infiltrating ductal carcinoma

Table 1 Relationship between lymphovascular invasion of the tumor, intra-operative pathological examination of level I axillary LN, and axillary lymph node status.

Lympho-vascular invasion	Lymph node metastasis		Total
	Yes	No	
Yes	5	0	5
No	1	14	15
Total	6	14	20
X^2 (P value)	0.88 (0.0001*)		
Intra-operative pathology of level I LN	Pathology of LN in level II and III		Total
	Positive	Negative	
Positive	2	3	5
Negative	0	15	15
Total	2	18	20
X^2 (P value)	0.509 (0.012*)		

* Significant.

Table 2 Relationship between tumor size, pathological type, grading and axillary lymph node status after paraffin section.

Tumor size	LN metastasis		Total
	Yes	No	
(T1)	1	6	7
(T2)	5	8	13
Total	6	14	20
X^2 (P value)	0.423 (0.0001*)		
Pathology of the tumor	LN metastasis		Total
	Yes	No	
(IDC)	6	10	16
IDC with comedo	0	4	4
Total	6	14	20
X^2 (P value)	0.327 (0.143)		
Tumor grade	LN metastasis		Total
	Yes	No	
GI	0	2	2
GII	3	11	14
GIII	3	1	4
Total	6	14	20
X^2 (P value)	0.324 (0.017)		

IDC = invasive ductal carcinoma.

* Significant.

grade II, with one infiltrated node out of six in level I and one positive out of 12 in levels II and III.

The relation between axillary lymph node metastasis and pathological features of the primary tumor: lymph node metastasis was frequently associated with bigger sized tumors. Five patients out of 13 presented with T2 tumor; (the minimum size was 2.5 cm and the maximum was 5 cm with a mean of 3.7 cm) had lymph node metastasis and 1 out of 7 patients who presented with T1 tumor had lymph node metastasis. This relation was statistically significant **Table 2** ($X^2 = 0.423$, $p < 0.0001$).

Six patients out of 16 with invasive ductal carcinoma IDC (NOS) had axillary lymph node metastases. None of the remaining four cases with IDC predominant comedo component type had axillary lymph node metastases. This relation was statistically insignificant **Table 2** ($X^2 = 0.327$, $p < 0.143$). No lymph node metastasis was encountered in two patients having grade I, while 3 patients out of 13 with grade II had LN metastasis and 3 patients out of 5 with grade III had LN metastasis. This relation was statistically insignificant **Table 2** ($X^2 = 0.324$, $p < 0.017$). Patients with lympho-vascular invasion were more likely to have lymph node metastasis. All patients with lympho-vascular invasion had positive axillary lymph node metastasis, while only 1 patient out of 15 with absent lympho-vascular invasion had positive lymph node metastasis on histopathological examination and this relation was statistically significant **Table 1** ($X^2 = 0.88$, $p < 0.0001$).

4. Discussion

As a part of breast cancer surgery complete axillary dissection can result in several complications such as lymph-edema; which is a bad complication that produces upper limb handi-cappness and manifests itself very late, also other complications including nerve injury, shoulder dysfunction, resistant seroma

formation that may compromise functionality and quality of life; this has led to the development of limited axillary dissection techniques. Although there is a general agreement that for larger tumors and clinically involved nodes, conventional axillary dissection is recommended, in T1 and T2 lesion without clinical disease in the axilla, the extent of surgery is controversial.¹¹

This study was conducted on 20 female patients with T1 and T2 with clinically non palpable axillary lymph nodes. These patients underwent dissection of level I axillary lymph nodes before proceeding to complete axillary clearance and this level was subjected to intraoperative pathological examination in the form of imprint cytology and frozen section, and after that it was submitted to ordinary histopathological examination.^{12,13}

Chen et al.¹⁴ had studied some of the tumor characteristics in an attempt to identify a correlation between them and axillary lymph node metastasis such as histopathological type, presence or absence of ductal carcinoma in situ (DCIS), comedo carcinoma, or lobular carcinoma they did not find any statistically significant relations between these features and lymph node metastasis, they concluded that all of these factors were equivocal in predicting lymph node metastasis. In our study the relation between histo-pathological types and axillary lymph node metastasis was also statistically insignificant. In our study there was a statistically significant relation between tumor grading with axillary lymph node metastasis this was coinciding with the study of Roderick et al.¹⁵, but was not compatible with the results of Ishikawa et al.¹⁶ and Rahusen et al.¹⁷ who found a non significant relation between the tumor grade and lymph node metastasis.

Woo et al.¹⁸ and Dewar et al.¹⁹ found that lympho-vascular invasion highly correlated with the presence of axillary lymph node metastasis. In the present study, five patients (25%) presented with lympho-vascular invasion around primary tumor, all of them had axillary lymph node metastasis while among the other 15 patients who presented without lympho-vascular invasion only one case of them had lymph node metastasis.

Veronesi et al.²⁰ studied 539 node positive cases in which they did complete axillary dissection; 98.5% had metastases in level I nodes. Level I was skipped by metastases in eight patients, while both lower levels (I, II) were skipped in only two patients. In another study they found seven of 80 node-positive patients had metastases that skipped level (I) but were observed in other levels II and III. The positive predictive value of a level (I) axillary dissection is actually higher than 91.3% because over half of axillary dissections (60% in their series) prove to have no nodal involvement and hence would have been predicted correctly by the examination of only level (I) nodes.¹⁹⁻²¹

Other investigators have studied axillary lymphadenectomy of a lesser scope than a formal level (I) dissection. Only level (I) dissection was noted to be accurate for qualitative analysis in one randomized study from the Scottish Cancer Trials. In 417 randomized patients, similar rates of node positive were found with limited level (I) dissection and with complete levels (I) and (II) nodal clearance. A mean of four axillary nodes was found in limited level (I) axillary dissection specimens. There was a similarity in rates of node positive noted between level I dissection and the complete dissection. Each of the 16 patients who underwent both level I and complete axillary dissection was correctly recognized by the limited dissection data. Only one patient in the entire

series failed to have lymph nodes identified in the limited dissection specimen.²²

However, the diagnostic accuracy of limited level (I) axillary dissection critically depends on the surgical technique. Also a study from the Scottish data, found no nodes to be identified in 116 (25%) of 473 patients with early breast cancer treated by level (I) axillary dissection. Others found a qualitative error for nodal sampling in 18% of 50 mastectomies in which preoperative sampling preceded axillary node clearance.^{23,24}

In the current study 20 patients with clinically negative nodes were treated by complete axillary clearance (Levels I, II and III); there were six patients (30%) showing metastasis to axillary lymph node, 100% of these metastases (six cases) were found in level (I) axillary lymph nodes with no skip metastasis to other levels II and III. Four cases of them (66.6%) showed metastases to level (I) LNs only, while two cases (33.3%) showed metastases to level II and III in addition to level I as all patients underwent level I axillary dissection followed by completeness of the axilla .

The study of Bonn Chua et al.²⁵ showed level (I) was positive in 45% of cases, 78% of these cases had metastasis in only level (I) nodes while both level II and III in addition to level (I) nodes were positive in 21% of cases, skip metastasis were 0.6 of cases. This denotes the necessity to do complete axillary lymph node dissection if level (I) axillary LNs were found positive by intraoperative pathological assessment.

As the number and level of axillary nodes are of a significant prognostic value; less than three node involvement is of a better prognosis than more than four node involvement. Five-year survival proved to be approximately 75% in patients without lymph node metastases, falling to approximately 60% in the presence of one to three positive lymph nodes and falling to 30% or less with four or more metastatic axillary lymph nodes. Thus, the decreased morbidity of a limited level I dissection, even if qualitatively accurate, must be weighed against the information from quantization of metastatic nodes.²⁶

In this study, the sensitivity of intra-operative pathological examination of level I axillary lymph nodes in detection of metastasis is 83.39%, the accuracy is 95%, both specificity and positive predictive value are 100% while negative predictive value is 93.33%. There were five cases detected by frozen section and imprint cytology as positive for metastasis, on matching these results with paraffin section, there was only one case out of 15 cases that was negative by FS and imprint cytology but positive by paraffin section, hence the false negative rate was 5%. The study of Van Deist et al.²⁷ observed combined sensitivity of frozen section and imprint cytology was 91% in detection of axillary lymph node metastasis as the frozen section and imprint cytology sensitivity in detection of micro-metastasis is 27%.

Using standardized method and careful pathologic review, we found that these methods are highly effective in identifying macrometastasis and far less effective in finding micrometastasis; Turner et al.²⁸ found that combination of FS and imprint cytology identified only 28% of micrometastasis. In our patients, only one type of intraoperative assessment would have been sufficient for detection of macrometastasis because the sensitivity of frozen section is 96% and 93% for imprint cytology. However to detect micrometastatic lesions in examined LNs both techniques have to be used in combination to relatively improve the diagnostic yield as the sensitivity for detection of micrometastasis is 27% for each.

Reviewing the literature no mentioned studies about intraoperative assessment of level (I) axillary LNs were encountered for comparing our results. However the available studies were considered with studying SLN biopsy. Veronesi et al.²⁹ and Viale et al.³⁰ have described a method of exhaustive frozen section of SLN that offers a near perfect sensitivity. It entails a work load of (60 sections per node, stained with H and E and rapid IHC). Detailed histopathological work-ups of axillary lymph nodes using serial or step sectioning and immunohistochemistry (IHC) increased the rate at which metastatic cells and micrometastases are detected and hence less FNR. This has been proved by examination of multiple permanent sections.^{31,32}

5. Conclusions

Partial axillary lymph node dissection is a minimally invasive, feasible and sufficient technique that can predict the axillary lymph node status. Intraoperative pathological examination of level I axillary lymph node is a reliable procedure in the assessment of axilla in early breast cancer with clinically non palpable axillary LNs. Routine intraoperative pathological examination of axillary lymph nodes can detect metastatic disease, allowing immediate axillary dissection, if necessary and avoiding the need for reoperation.

References

- Fisher B, Anderson S, Redmond CK, Wolmark N, Wickerham WM, Cronin WM. Reanalysis and results after 12 years of follow-up in a randomized clinical trial comparing total mastectomy with lumpectomy with or without irradiation in the treatment of breast cancer. *N Engl J Med* 1995;**333**:1456–61.
- Margolese R. Surgical considerations in selecting local therapy. *J Natl Cancer Inst Monogr* 1992;**11**:41–8.
- Senofsky G, Moffat FJ, Davis K, Masri M, Clark K, Robinson D, et al. Total axillary lymphadenectomy in the management of breast cancer. *Arch Surg* 1991;**126**:1336–41.
- Chilson T, Chan F, Lonser R, et al. Seroma prevention after modified radical mastectomy. *Am Surg* 1992;**58**:750.
- Magnant CM. Management of primary carcinoma and the axilla. In: Spear SL, editor. *Surgery of the Breast*. Philadelphia: Lippincott-Raven; 1998.
- Petrek J, Peters M, Nori S, et al. Axillary lymphadenectomy: a prospective, randomized trial of thirteen factors influencing drainage, including early or delayed arm mobilization. *Arch Surg* 1991;**125**:378.
- Hladiuk M, Huchcroft S, Temple W, Schnurr BE. Arm function after axillary dissection for breast cancer: a pilot study to provide parameter estimates. *J Surg Oncol* 1992;**50**(1):47–52.
- Ivens D, Hoe AL, Podd TJ, Hamilton CR, Taylor I, Royle GT. Assessment of morbidity from complete axillary dissection. *Br J Cancer* 1992;**66**(1):136–8.
- Assa J. The intercostobrachial nerve in radical mastectomy. *J Surg Oncol* 1974;**6**(2):123–6.
- Gerber L, Lampert M, Wood C, Duncan M, D'Angelo T, Schain W, et al. Comparison of pain, motion, and edema after modified radical mastectomy vs. local excision with axillary dissection and radiation. *Breast Cancer Res Treat* 1992;**21**(2):139–45.
- Tabar L, Fagerberg GJG, Gad A, et al. Reduction in mortality from breast cancer after mass screening with mammography. *Lancet* 1985;**1**:829–32, 13. Tabar L, Fagerberg G, Duffy SW et al. Update of the Swedish.
- Hutter RV. The role of pathologist in breast cancer management. *Cancer* 1990;**38**:1363–72.
- Mansaur EG, Ravdin PM and Dressler: prognostic factors in early. *Breast Cancer* 1994;**374**:381.
- Chen M, Palleschi S, Khoynzhad A, Gecelter G, Marini CP, Simms HH. Role of primary breast cancer characteristics in predicting positive sentinel lymph node biopsy results: a multivariate analysis. *Arch Surg* 2002;**137**(5):606–9.
- Turner Roderick R, Chu Kyo V, Qi Karen, Botnick Leslie E, Hansen Nora M, C-Glass Edwin, et al. Pathological Features associated with nonsentinel lymph node metastasis in patients with metastatic breast carcinoma in a sentinel lymph node. *Am Cancer Soc* 2000;**2**:564–81.
- Ishikawa H, Sato K, Mochizuki H. Optimal sentinel node examination and a new strategy for axillary control in breast cancer. *Breast J* 2002;**8**(1):10–4.
- Rahusen FD, Torrenga H, van Diest PJ, Pijpers R, Van der WE, Licht J, et al. Predictive factors for metastatic involvement of nonsentinel nodes in patients with breast cancer. *Arch Surg* 2001;**136**(9):1059–63.
- Woo CS, Silberman H, Nakamura SK, Ye W, Sposto R, Colburn W, et al. Lymph node status combined with lymphovascular invasion creates a more powerful tool for predicting outcome in patients with invasive breast cancer. *Am J Surg* 2002;**184**(4):337–40.
- Dewar JA, Sarrazin D, Benhamou e, et al. Management of the axilla in conservatively treated breast cancer: 592 patients treated at Institut Gustave-Roussy. *Int J Rad Oncol Phys* 1987;**13**:475–81.
- Veronesi U, Rilke F, Luini A, et al. Distribution of axillary node metastases by level of invasion: an analysis of 539 cases. *Cancer* 1987;**59**:682–7.
- Boova RS, Bonanni R, Rosato FE. Patterns of axillary nodal involvement in breast cancer. Predictability of level one dissection. *Ann Surg* 1982;**196**:642–4.
- Steele RJ, Forrest AP, Gibson T, et al. The efficacy of lower axillary sampling in obtaining lymph node status in breast cancer: a controlled randomized trial. *Br J Surg* 1985;**72**:368–9.
- Forrest AP, Stewart HJ, Robert MM, et al. Simple mastectomy and axillary sampling (pectoral node biopsy) in the management of primary breast cancer. *Ann Surg* 1982;**196**:371–8.
- Kissin MW, Thompson EM, Price AB, et al. The inadequacy of axillary sampling in breast cancer. *Lancet* 1982;**1**:1210–2.
- Chua Boon, Ung O, Taylor Ritchard, Boyazer John. Is there a role for axillary dissection for patients with operable breast cancer in this era of conservatism? *ANZ J Surg* 2002;**72**:786–92.
- Barth Jr RJ, Danforth Jr. DN, Venzon DJ, et al. Level of axillary involvement by lymph node metastases from breast cancer is not an adequate predictor of survival. *Arch Surg* 1991;**126**:574–7.
- Van Diest PJ, Van TorrengaH, Borgstein PJ. Reliability of intraoperative frozen section and imprint cytological investigation of sentinel lymph nodes in breast cancer. *Histopathology* 1999;**35**:14–8.
- Turner RR, Hansen NM, Stern SL, Giuliano AE. Intraoperative examination of the sentinel lymph node for breast carcinoma staging. *Am J Clin Pathol* 1999;**112**:627–34.
- Veronesi U, Paganelli G, Viale G, et al. Sentinel lymph node biopsy and axillary dissection in breast cancer: results in a large series. *J Natl Cancer Inst* 1999;**91**:368–73.
- Viale G, Bosari S, Mazzarol G, et al. Intraoperative examination of axillary sentinel lymph nodes in breast carcinoma patients. *Cancer* 1999;**85**:2433–8.
- Creager AJ, Geisinger KR, Shiver SA, et al. Intraoperative evaluation of sentinel lymph nodes for metastatic breast carcinoma by imprint cytology. *Mod Pathol* 2002;**15**:1140–7.
- Smidt ML, Besseling R, Wauters CA, Strobbe LJ. Intraoperative scrape cytology of sentinel lymph node in patients with breast cancer. *Br J Surg* 2002;**89**:1290–3.