



ORIGINAL ARTICLE

The applicability of D2 gastrectomy in operable gastric cancer patients: A trial of Alexandria Surgical Oncology Unit

Tarek Abdel Halim El-Fayoumi *, Haytham M. Fyed, Mohammad El Mesiry, Ahmed Tarek Awad

Department of General Surgery, Faculty of Medicine, Alexandria University, Alexandria, Egypt

Received 16 October 2012; accepted 20 December 2012

Available online 7 March 2013

KEYWORDS

Gastric cancer;
D2 gastrectomy

Abstract *Background:* There is ongoing controversy in patients with early gastric cancer over whether a lymph node resection beyond a D1 lymphadenectomy is beneficial. Experienced gastric surgery centers, especially in Japan and Korea, have argued that a more extensive lymph node dissection that incorporates the next echelon of lymph nodes (D2 lymphadenectomy) improves staging and outcome in gastric cancer patients.

Aim of the work: Was to assess the feasibility and safety of D2 gastrectomy in patients presented by operable gastric cancer.

Patients and Methods: The study included thirty patients with operable gastric cancer who were treated by D2 gastrectomy after preoperative assessment by laboratory and radiological investigations. They were followed post operatively for complications and hospital stay and the histopathological criteria were assessed and analyzed.

Results: Twenty six patients had pyloric tumors and four having gastric body tumors were included. Postoperative complications occurred in 20% of cases, these included wound infection, bile leak, ascites and chest infection.

* Corresponding author. Address: Alexandria University, Department of General Surgery, Faculty of Medicine, 21 Moshir Ahmed Ismail St., Sidi Gaber, Alexandria, Egypt. Tel.: +203 5440094.

E-mail addresses: tarekfayouim@yahoo.com (T.A.H. El-Fayoumi), haytham.fayed@alexmed.edu.eg (H.M. Fyed), mohmessiry@hotmail.com (M.E. Mesiry), atfawad@yahoo.com (A.T. Awad).

Peer review under responsibility of Alexandria University Faculty of Medicine.



Conclusion: D2 gastrectomy for gastric cancer is a safe procedure for patients with operable gastric cancer.

© 2013 Production and hosting by Elsevier B.V. on behalf of Alexandria University Faculty of Medicine.

1. Introduction

The incidence of gastric cancer is declining and inspite of this fact; it remains the fourth most common cancer and the second most common cause of cancer-deaths worldwide.¹ Over the previous several decades, controversy over whether the added morbidity and mortality of total gastrectomy over subtotal gastrectomy was accompanied by any improved survival persuaded most surgeons to use radical subtotal excisions for all but proximal cancers. The only hope for the cure of stomach cancer remains complete surgical extirpation of the cancer with an adequate margin of normal tissue.² The addition of enbloc removal of affected organs, such as the spleen, pancreas, colon, and lateral segment of the left lobe of the liver (Segments II and III), is considered appropriate for contiguous spread of the primary as long as no dissemination is apparent. Recent work from Memorial Sloan-Kettering Cancer Center in New York City demonstrates equivalent mortality for gastric resection with and without en-bloc resection of adjacent organs.³ However, the morbidity rates were higher in the group requiring splenectomy and distal pancreatectomy. More postoperative interventions were also necessary to treat complications in this group. Other retrospective reviews and randomized controlled trials have demonstrated increased morbidity and mortality from splenopancreatectomy.⁴ There is ongoing controversy over whether a lymph node resection beyond a D1 lymphadenectomy is beneficial. Experienced gastric surgery centers, especially in Japan and Korea, have argued that a more extensive lymph node dissection that incorporates the next echelon of lymph nodes (D2 lymphadenectomy) improves staging and outcome in gastric cancer patients. (Figure 1)^{5,6}

Aim of the work: Was to assess the feasibility and safety of D2 gastrectomy in patients presented by operable gastric cancer.

2. Patients and methods

The study included thirty patients admitted to the Surgical Oncology Unit of the Alexandria University Hospital presented with operable gastric cancer in the period between April 2010 and August 2012. They were diagnosed preoperatively by esophago-gastro-duodenoscopy and biopsy, CT scan of the abdomen and pelvis. Patients with CT findings of liver metastasis, peritoneal seedlings, malignant ascites or extensive involvement of adjacent organs beyond respectability were excluded from the study. After informed consent all patients were treated by D2 dissection i.e. D1 dissection in addition to the removal of the omental bursa with the front leaf of the transverse mesocolon, and the left gastric, common hepatic, celiac and splenic artery nodes are cleared. The type of gastrectomy (distal or total) was done according to the site of the tumor; distal gastrectomy was done if there is a free safety margin of five cm beyond the proximal resection line otherwise total gastrectomy was done.

The steps of the operation were follows: an upper midline incision extending below the umbilicus was done in all cases, exploration was done to detect metastatic disease in the liver, Douglas pouch or other organs that were not detected by pre-operative CT examination.

The tumor itself was assessed to determine: (1) its position in the stomach (antral, body or cardia); (2) The extent of the tumor (circumferential and involvement of more than one sector of the stomach) and (3) The depth of invasion (involvement of the serosa or otherwise, direct invasion of adjacent structures). The latter finding dictated the performance of an adjoining organ resection (transverse colon, tail of the pancreas or a lobe of the liver) in addition to D2 lymphadenectomy. Then the duodenum was widely 'Kocherized'. The omentum was separated from the colon and dissection was continued onto the transverse mesocolon, taking the anterior layer of the mesocolon with the omentum and taking care not to damage the colonic vasculature. It was important to ensure that the correct plane was entered at the beginning of this

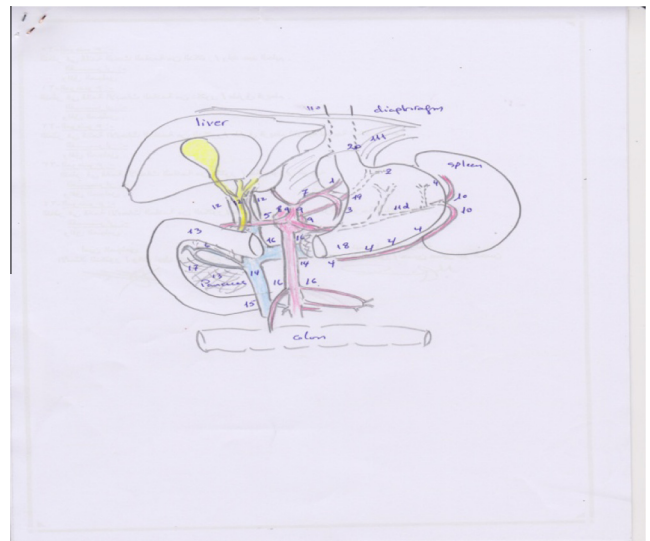


Figure 1 Sixteen stations of lymph nodes are arranged according to the location and extension of the primary tumor (N0–N4) and (D1–D4) means extent of lymphadenectomy: D1 (N1 level): the perigastric nodes along the greater and lesser curvatures (stations 1–6). D2 (N2 level): nodes along the left gastric artery (station 7), common hepatic artery (station 8), celiac trunk (station 9), splenic hilus, and splenic artery (station 10 and 11). D3 (N3 level): lymph nodes at stations 12–14, along the hepatoduodenal ligament and the root of the mesentery. D4 (N4 level) up to 15 and 16 in the paraaortic and the paracolic region. (According to Japanese classification).⁶ R6: adopted from: Kim H.J., Karpeh M.S., Brennan M.F. Standardization of the extent of lymphadenectomy for gastric cancer: impact on survival. *Advances in Surgery* 2001, 35: 203–223 (0065–3411).

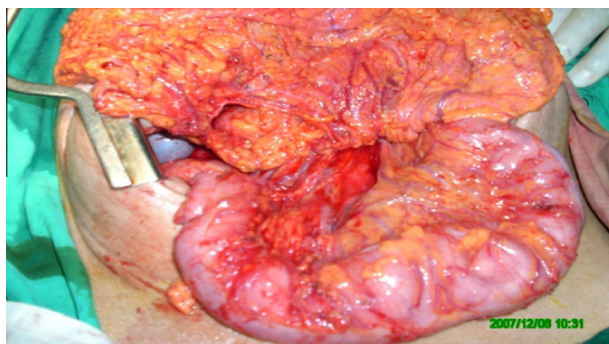


Figure 2 Separation of the anterior 2 leaflets of the transverse mesocolon together with the greater omentum from the posterior 2 leaflets of the transverse mesocolon.

dissection. To this end, it was often useful to start separating the omentum at the mid-colonic level and be guided by the middle colic vessels. This dissection was carried to the right with identification of the right gastroepiploic vessels, the surrounding lymphatics (including the sub-pyloric lymph nodes) were swept up with the vessels; these were ligated with 2/0 vicryl at their origin. The dissection was carried onto the pancreas taking the pancreatic capsule with the specimen. (Figure 2)

If it is proving difficult to separate the pancreatic capsule at this point, attention is directed to the lesser omentum. The omentum is placed back in the abdomen and an assistant retracts the liver in a cephalic direction; it may be helpful to have a reverse trendelenberg tilt on the table at this time. The reflection of the lesser omentum on the liver is divided, starting at the hiatus and working to the right side. In dissecting from above downward the right gastric artery is ligated at its origin and divided.

If a total gastrectomy is being performed for a more proximal tumor then after division of the lesser omentum it is often helpful to dissect the hiatus mobilizing the lower esophagus. After ligation of the right gastric artery, the duodenum is mobilized from the pancreas. At this stage, a number of small vessels are often encountered and should be ligated and not diathermised. The duodenum (> 2 cm from the pylorus) can now be divided between two crushing clamps. The duodenal stump is closed with a continuous 3/0 vicryl suture which is then inverted with a second 3/0 prolene layer of closure.

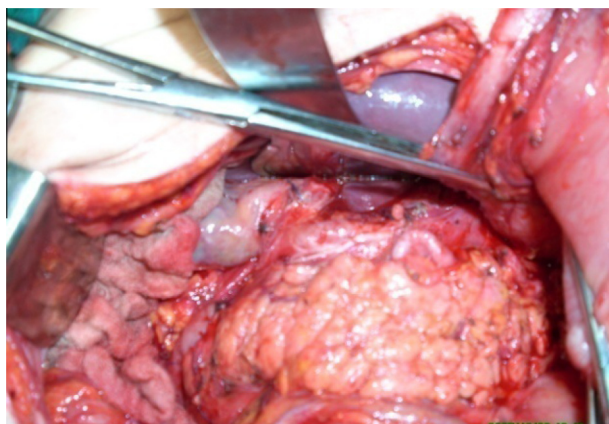


Figure 3 Splenic artery completely skeletonized.

Alternatively, a linear cutting/stapling device can be used to divide the duodenum; however, it is our practice to bury the staple line with a continuous 3/0 prolene suture. Separation of the pancreatic capsule and dissection along the common hepatic artery is now carried out. The transected duodenum and stomach are lifted out of the wound and to the left, the common hepatic artery identified and cleared, removing the tissue inferior to this with the pancreatic capsule. The left gastric vein is identified and ligated. The left branch of the gastroepiploic arcade is divided and the lowest short gastric vessels ligated and divided. The stomach and omentum can then be lifted forwards exposing the celiac axis and left gastric artery from below. The tissue from around the celiac axis and splenic artery are swept forward and included with the left gastric artery which is double ligated with 2/0 vicryl and divided. (Figure 3)

At the end of this dissection the pancreas is skeletonised as are the hepatic and splenic arteries. The stomach, at this point, is prepared for the transection by ensuring that it is cleaned to its wall, this will involve dividing tissue adherent to the high lesser curve which will include the right cardiac nodes. On the greater curve side of the stomach the remaining short gastric vessels supply the gastric remnant. If a total gastrectomy is planned the remaining short gastric vessels are ligated as close to the spleen as possible and the remainder of the pancreatic capsule stripped from the pancreatic tail. After distal gastrectomy, gastrojejunostomy was done and after total gastrectomy, roux en-Y esophagojejunostomy was done.

As regards postoperative management: the initial postoperative care focused on the administration of adequate analgesia, maintenance of fluid and electrolyte balance and chest physiotherapy. The patients were routinely nursed in a high dependency unit and monitored with hourly blood pressure, pulse, urinary volumes and central venous pressure recordings for the first 24 h. Humidified oxygen was administered at an appropriate concentration to ensure an oxygen saturation of > 95 mm Hg. The gastric lumen was decompressed by nasogastric tube which is left on free drainage until bowel motion was regained; thereafter, feeding was introduced. Drains were removed on the 6th postoperative day routinely and the patient was discharged on the seventh postoperative day unless postoperative complications occurred. Sutures were removed 15 days after surgery. Postoperative complications were searched for and recorded.

The results are tabulated and analyzed by The Statistical Package for the Social Sciences (SPSS) software version 15 for windows. Qualitative data was analyzed using Fisher Exact and Monte Carlo tests. Also comparison between quantitative data was analyzed using student t-test and F-test (ANOVA).

3. Results

The majority of the studied patients were males (26 males and 4 females). The male to female ratio was 6.5: 1. The ages ranged from 29 to 70 years and the mean age was 50.93 ± 9.77 years. Gastric outlet obstruction was the presentation in 10 patients (33.3%). One case presented acutely with gastric perforation that was initially explored and diagnosed by biopsy. The subsequent definitive procedure of D2 gastrectomy was performed 3 weeks later. The tumor was located in the pyloric antrum in 26 patients (87%) while 4 cases of gastric body tumors were included in the study.

Table 1 Relation of N stage with age site and T stage of the tumor and the relation between postoperative complications with Type of gastrectomy.

	N stage						F (p)			
	N0 (n = 19)		N1 (n = 10)		N2 (n = 1)					
Age (years)										
Range	29–70		42–66		38					
Mean ± SD	50.74 ± 10.55		52.60 ± 7.95		38.00 ± –		1.028 (0.371)			
Tumor site (cms)										
Range	3–8		4–8		8					
Mean ± SD	5.26 ± 1.22		5.90 ± 1.20		8.00 ± –		2.995 (0.067)			
	N stage						No	Test of sig.		
	N0		N1		N2					
	No.	%	No.	%	No.	%				
Tumor site										
Pylorus	18	69.2	7	26.9	1	3.9	26	<i>MCp</i> = 0.649		
Body	1	25	3	75	0	0.0	4			
T stage										
T2a	1	100.0	0	0.0	0	0.0	1	<i>MCp</i> = 0.714		
T2b	10	68.8	5	31.3	0	0.0	15			
T3	7	53.8	5	38.5	1	7.7	13			
T4	1	100.0	0	0	0	0	1			
	Postoperative complications								No	Test of sig.
	No		Bile leak		Ascites		Minor wound infection			
	No.	%	No.	%	No.	%	No.	%		
	No.	%	No.	%	No.	%	No.	%		
Type of gastrectomy										
Distal	20	76.92	2	7.7	1	3.85	3	11.53	26	<i>MCp</i> = 1.000
Total	4	100.0	0	0.0	0	0.0	0	0.0	4	

In the course of D2 gastrectomy detected operative findings were as follows: in 16 patients the tumor did not reach the serosa, while the serosa was apparently involved without invading nearby organs in 13 patients. Invasion of the transverse colon was encountered in one patient. Omental bursectomy was easily performed in all cases. The celiac trunk and its branches were identified and dissected with ligation of the left gastric vessels and skeletonisation of the splenic and hepatic arteries. And multiple palpable lymph nodes were identified along the course of the left gastric artery in 10 cases. The areolar tissue around the common hepatic artery was free of any palpable lymph nodes in all cases. There were no enlarged nodes along the course of the splenic artery or around the celiac trunk. The splenic hilar lymph nodes were not enlarged in any of the cases who had pyloric tumors although they were enlarged in 2 cases with gastric body tumors. The right paracardial tissue was removed in all cases while both the left and right paracardial tissue was removed in cases with gastric body tumors. In all patients there were no palpable lymph nodes. For pyloric tumors, distal gastrectomy with 5 cm safety margin proximally and to the first part of the duodenum distally was done with D2 lymphadenectomy and reconstruction by antecolic gastrojejunostomy. Total gastrectomy with D2 lymphadenectomy was done for tumors involving the gastric body with reconstruction by roux en y esophagojejunostomy. The spleen was removed in all cases that had total

gastrectomy because of enlargement of splenic hilar nodes (2 cases) or proximity of the tumor to the spleen (2 cases) and was preserved in all cases that had distal gastrectomy. In one case transverse colectomy was done in which case the tumor was found to invade the serosa of the transverse colon and the transverse mesocolon. The mean operative time was 2.64 ± 0.39 (ranging from 2.5 to 3.5) hours. No intraoperative complications were encountered.

The postoperative period was smooth and unremarkable in 24 cases (80%). Postoperative complications occurred in 6 patients (20%) in the form of minor wound infection and gaping (3 cases: 10%) which stopped spontaneously after 5–7 days of conservative treatment. Bile leakage (2 cases: 6.67%) cases detected by bile stained fluid in the drain which was of small amount and closed spontaneously after 3 and 5 days of conservative treatment. Both cases had a history of cholecystectomy. Postoperative ascites was detected in one case (3.33%) which was ascribed to postoperative hypoalbuminaemia and retroperitoneal raw area. This was treated medically and relieved after one month. Chest infection occurred in 3 patients that required medical treatment and respiratory exercises. There were no postoperative complications related to associated organ resection. In addition, the hospital mortality rate was nil.

The mean tumor size was 5.57 ± 1.29 (range from 3–8) cms. According to TNM staging system, 1 case had T2a tumor (3.3%), 15 cases had T2b tumor (50%), 13 cases had T3 tumor (43.3%) and 1 case had T4 tumor (3.3%). As regards tumor

grading, 3 cases (10%) had well differentiated adenocarcinoma, 22 cases (73.33%) had moderately differentiated adenocarcinoma and 5 cases (16.67%) had poorly differentiated adenocarcinoma

The mean number of lymph nodes dissected and examined pathologically was 19.00 ± 2.68 (range from 15–25) LNs. Metastatic deposits in lymph nodes were detected in 11 cases; eight of them had pyloric tumor and three cases had gastric body tumor. The number of involved lymph nodes ranged from 3 to 9 lymph nodes. According to TNM staging system, 19 patients had N0 stage, 10 patients had N1 stage and one patient had N2 stage. The N stage was studied in relation to tumor size and age of the patient and although was statistically insignificant (P value: 0.067 and 0.371, respectively), the relation was borderline with tumor size. Studying the N stage of the tumor in relation to tumor site and T stage was statistically insignificant (P values were 0.649 and 0.714, respectively). N stage was significantly correlated with histological grade of the tumor (p value: 0.009). Studying the occurrence of postoperative complications in relation to the type of gastrectomy (distal or total) and was insignificant (P value: 1.000). On the other hand, the postoperative hospital stay was significantly prolonged when postoperative complications occurred (P value: <0.001). Table 1.

4. Discussion

Patients with larger tumors had more invasion into the gastric wall in terms of depth of invasion and more frequent lymph node metastasis than did patients with smaller tumors. Tumor size clinically serves as a simple predictor of tumor progression and survival of patients in gastric carcinoma.⁷ The incidence of lymph node metastases increases with invasive tumors larger than 30 mm as there was increased incidence of lymphatic-vascular involvement with an increased risk of LN metastases.⁸ Previous studies indicated the significance of tumor diameter by dividing patients into three groups: <40 mm, ≥ 40 to <100 mm, and ≥ 100 mm. Another study defined a large gastric tumor as one ≥ 100 mm in diameter. However, other reports have defined the optimal cutoff value of tumor diameter as 80 mm. These conflicting results might be due to differences in the number of patients, lymph node dissections, or treatments after surgery. In the same study, larger tumors were associated with increased incidence of lymph node metastases and poor prognosis.⁹

From the present study and Takeo et al.¹⁰ study, it was noted that lymph node metastases were located mainly in the perigastric nodes (N1 nodes) then to N2 nodes mainly the left gastric artery nodes (group 7), common hepatic nodes (group 8) and splenic hilar nodes (group 10). The incidence of metastases to any perigastric node station was highest when the tumor was located close to it, even though there was little variation in the metastatic pattern along the lesser curvature between tumors in the different thirds (upper, middle or lower thirds). Station numbers 2 (left paracardial) and 5 (suprapyloric) had the lowest incidence of metastatic deposits for all locations of tumors. The position of the tumor on different parts of the stomach circumference had a similar impact. Proximal third tumors along the lesser curvature or on the anterior or posterior walls had splenic hilar node metastases in up to 6%, compared to 32% for tumors at the greater

curvature.¹¹ Total gastrectomy has a higher morbidity and hospital stay than distal gastrectomy and there is no survival benefit from a total gastrectomy if resection margins are free of tumor. The resection of the spleen or the pancreas in association with total gastrectomy is an important risk factor for morbidity and hospital mortality after D2 dissection.¹²

In the Turkish study¹³, postoperative complications in patients treated by D2 gastrectomy occurred in 35% of cases (there was lymphatic leakage resulted from retroperitoneal dissection in 29 patients, wound infection in one patient, anastomotic leakage in one, ileus in two, and nonsurgical complications in six patients). In the same study, surgical complications in the D1 group were found in 8.8% (wound infection in three patients, duodenal stump dehiscence in one, anastomotic leakage in one, ileus in one, and four patients had nonsurgical complications i.e. pulmonary and cardiac). 10.46% of patients who were treated by D2 gastrectomy in Kunisaki et al.¹⁴ study had postoperative complications (pulmonary disorders, renal dysfunction, anastomotic leakage, hemorrhage, injury of the biliary tract, pancreatic fistula, wound infection, ileus and heart failure) while 39.3% of patients who were treated by D3 gastrectomy had postoperative complications (pulmonary disorders, renal dysfunction, anastomotic leakage, hemorrhage, injury of the biliary tract, pancreatic fistula, wound infection, ileus and heart failure).

5. Conclusion

D2 gastrectomy is a safe procedure in patients with operable gastric cancer in well trained hands. The higher the size of the tumor the higher incidence of lymph node metastasis also this was not significant. Splenic hilar nodes were the most commonly involved among the N2 nodes in gastric body tumors.

References

1. Liu X, Cai H, Shi Y, Wang J. Prognostic factors in patients with node-negative gastric cancer: a single center experience from china. *Gastrointest Surg* 2012;**16**:1123–7.
2. Sewart JR, Fink U, Sendler A, et al. Gastric Cancer. *Curr Probl Surg* 1997;**34**(835):942.
3. Martin 2nd RC, Jacques DP, Brennan MF, et al. Achieving R0 resection for locally advanced gastric cancer: is it worth the risk of multi-organ resection? *J Am Coll Surg* 2002;**194**: 568–77.
4. Piso P, Bellin T, Aselmann H, et al. Results of combined gastrectomy and pancreatic resection in patients with advanced primary gastric carcinoma. *Dig Surg* 2002;**19**(4):281–5.
5. Massachusetts general hospital cancer center. Extent of stomach and lymph node resection for gastric (stomach, cancer 2007).
6. Kim HJ, Karpeh MS, Brennan MF. Standardization of the extent of lymphadenectomy for gastric cancer: impact on survival. *Adv Surg* 2001;**35**:203–23, 0065–3411.
7. Yokota T, Ishiyama S, Saito T, Teshima S, Yamada Y, Iwamoto K, et al. Is tumor size a prognostic indicator for gastric carcinoma? *Anticancer Res.* 2002;**22**(6B):3673–7.
8. Gotoda T, Yanagisawa A, Sasako M, Ono H, Nakanishi Y, Shimoda T, et al. Incidence of lymph node metastasis from early gastric cancer: estimation with a large number of cases at two large centers. *Gastric Cancer* 2000;**3**:219–25.
9. Kunisaki C, Makino H, Takagawa R, et al. Tumor diameter as a prognostic factor in patients with gastric cancer. *Ann Surg Oncol* 2008;**15**(7):1959–67.

10. Takao M, Fukuda T, Iwanaga S, et al. Gastric cancer: evaluation of triphasic spiral CT and radiologic-pathologic correlation. *J Comput Assist Tomogr* 1998;**22**:288-94.
11. Maruyama Keiichi, Gunven Peter, Okbayashi Kenzo, Sasako Taira, Kinoshita Taira. Lymph node metastases of gastric cancer general pattern in 1931 patients. *Ann Surg* 1989;**210**: 284-8.
12. Hartgrink HH, van de Velde CJ, Putter H, et al. Extended lymph node dissection for gastric cancer: who may benefit? Final results of the randomized Dutch gastric cancer group trial. *J Clin Oncol* 2004 Jun 1;**22**(11):2069-77, Epub 2004 Apr 13.
13. Emin Yildirim, Orhan C, Uğur Berberoğlu elen. The Turkish Experience with Curative Gastrectomies for Gastric Carcinoma: Is D2 Dissection Worthwhile? *J Am Coll Surg* 2001;**192**:25-37.
14. Kunizaki C, Akiyama H, Nomura M, et al. Comparison of surgical results of D2 versus D3 gastrectomy (para-aortic lymph node dissection) for advanced gastric carcinoma: a multi-institutional study. *Ann Surg Oncol* 2006;**12**:7-15.