



ORIGINAL ARTICLE

# Management of spastic hand by selective peripheral neurotomies

Wael Fouad

Alexandria Faculty of Medicine, Neurosurgery Department, Sultan Hussein Street, Azarita, Alexandria, Egypt

Received 23 June 2011; accepted 17 July 2011

Available online 20 August 2011

## KEYWORDS

Spastic hand;  
Selective peripheral  
neurotomies

**Abstract** *Introduction:* Selective peripheral neurotomies (SPN) are proposed when spasticity is focalized on muscles that are under the control of a single or few peripheral nerves.

*Objective:* This study was done to evaluate the functional results of SPN of median and ulnar nerves in 10 patients who had spastic hyperflexion of the wrist and fingers.

*Methods:* All patients preoperatively had spasticity either G3 or G4 as measured by modified Ashworth scale. All cases underwent surgery in the form of variable combination of SPN of median and ulnar nerves depending on the pattern and distribution of spasticity. Depending on the degree of preoperative spasticity, 50–80% of the isolated motor branches of fascicles were resected under the operating microscope. Mean postoperative follow up examination period was 21 months.

*Results:* There was no operative mortality. One patient had wound infection. Transient paresis of flexors of the wrist and fingers because of excessive nerves sectioning occurred in one patient that responded well to physiotherapy. Postoperatively, all the patients had immediate improvement of their spasticity grade. After initial improvement, recurrence of spasticity occurred in one patient

E-mail address: [wael Fouad\\_67@hotmail.com](mailto:wael Fouad_67@hotmail.com)

2090-5068 © 2011 Alexandria University Faculty of Medicine.  
Production and hosting by Elsevier B.V. All rights reserved.

Peer review under responsibility of Alexandria University Faculty of Medicine.

doi:10.1016/j.ajme.2011.07.012



Production and hosting by Elsevier

6 months postoperatively and that might be due to insufficient amount of nerve sectioning. Abnormal hand posture that was present in all cases improved in 9 patients (90%) postoperatively, while pain that was present in 50% of cases improved in all these cases postoperatively as measured by visual analogue scale. Assessment of outcome after surgery was done by comparing modified Ashworth scale preoperatively and postoperatively. At the last follow up examination period, excellent results were obtained in 40% of patients, good results in 40% of patients, fair results in 10% of patients, and poor results in 10% of cases. Conclusion: In well-selected patients, SPN can yield good effects on refractory spasticity of the hand and its consequences.

© 2011 Alexandria University Faculty of Medicine. Production and hosting by Elsevier B.V. All rights reserved.

## 1. Introduction

Selective peripheral neurotomies (SPN) were first introduced for the treatment of spastic deformities of the foot by Stoffel.<sup>1</sup> Selectivity is required to suppress the spasticity without excessive weakening of motor power and without producing exaggerated amyotrophy.<sup>2</sup> To achieve this goal at least one fifth of the motor fibers are preserved. Selective fascicular neurotomies can be performed in the median and ulnar nerves for spastic hyperflexion of the wrist and fingers.<sup>1,3</sup> A temporary local anesthetic block with xylocaine can be useful. Such test can determine if articular limitation results from spasticity or musculotendinous contractures and/or articular ankylosis.<sup>4</sup>

Selective peripheral neurotomies are proposed when spasticity is focalized on muscles that are under the control of a single or few peripheral nerves.<sup>5</sup> Careful selection of patients is crucial to obtain worthwhile outcomes. SPN aims at re-equilibrating the tonic balance between agonist and antagonist muscles by reducing excess spasticity.<sup>6</sup> The surgical procedure therefore must be as selective as possible; that is, it must not abolish useful muscular tone and must not decrease residual motor and sensory functions.<sup>7</sup> Reduction of spasticity is obtained by sectioning both afferents and efferents fibers of the stretch-reflex at the level of the muscular nerve.<sup>8</sup> Selectivity of the lesion is assured when using fine microsurgical dissection and accurate localization of motor nerves with intraoperative electrical nerve stimulation.<sup>9</sup>

The aim of this work was to evaluate the functional results of selective peripheral neurotomies of median and ulnar nerves in 10 patients who had spastic hyperflexion of the wrist and fingers. Also to compare these results with the results of the other authors reported in the literature.

## Methods

This retrospective study was carried out on 10 patients who had spastic hyperflexion of the wrist and fingers. This study

was done in Alexandria hospitals over a period of 4 years starting from January 2006 to December 2009. The male to female ratio was 1 to 1 (5 males and 5 females) and their ages ranged from 15 to 58 years with mean age of 34 years.

Selection and assessment of patients were performed carefully that included observation of posture, assessment of passive range of motion, orthopedic status (musculoskeletal contractures), and quantification of the degree of spasticity using modified Ashworth scale. In this study all patients preoperatively had spasticity either G3 or G4 as measured by modified Ashworth scale (Table 1). The determination of the respective involvement in the abnormal posture of spasticity (treated with SPN) and only articular, muscular, tendinous, and/or ligamentous limitations (relieved by orthopedic procedures) was important. If doubt persisted after detailed clinical examination, nerve blocks with 3 mL of 0.25% xylocaine were used for testing of passive articular mobility. When spasticity plays the larger role in the articular limitations, abnormal postures were significantly diminished after the test. If this was not the case, orthopedic surgery may be the initial or the only treatment. Also functional outcome was assessed using Oswestry scale of spasticity grading (Table 2).

All cases underwent surgery in the form of selective peripheral neurotomies of median and ulnar nerves under general anesthesia but without long-lasting muscle relaxants so that the motor responses elicited by bipolar electrical stimulation of motor branches could be detected to identify the motor nerve.

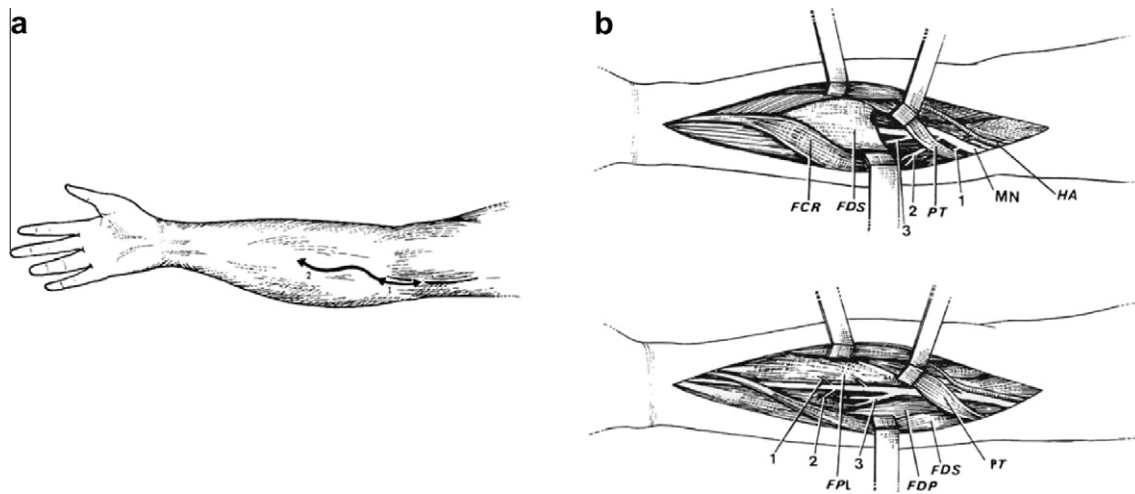
The skin incision began 3 cm above the flexion line of the elbow, medial to the biceps brachii tendon; both median and ulnar nerves were exposed with the same incision.

The identification of motor branches of pronator teres (PT), flexor carpi radialis (FCR) and to the flexor digitorum superficialis (FDS) was done. The muscular branches of flexor digitorum profundus (FDP), the flexor pollicis longus (FPL) and the pronator quadratus (PQ) might be individualized as separate branches or remain together in the distal trunk of

**Table 1** Modified Ashworth scale.

Grade	Patient's status
0	No increase in muscle tone
1	Slight increase in tone with a catch and release or minimal resistance at end of range of motion
1+	Slight increase in tone but with minimal resistance through range of motion following catch
2	More marked increase in tone but limb easily moved
3	Considerable increase in tone, passive movement is difficult
4	Affected part is rigid

All patients had spasticity either G3 or G4 preoperatively.



**Figure 1** Schematic representation of median nerve neurotomy.<sup>3</sup> (a) S-shaped skin incision on the right forearm. (b) Dissection of the median nerve in two stages. First stage of the dissection (upper figure), the PT is retracted upward and laterally and the FCR medially. Branches from the median nerve (MN), before it passes under the fibrous arch of the FDS, are dissected: to the PT(1) and two nerve trunks to the FCR, PL and FDS(2), (3). Second stage of the dissection (lower figure), the fibrous arch of the FDS is sectioned to allow a more distal dissection of the median nerve. The FDS is retracted medially and branches from the median nerve are identified: (1) to the FPL; (2) to the FDP; (3) the interosseous nerve and its proper branches to these muscles.

the anterior inter-osseous nerve. The ulnar nerve was identified medially to the medial epicondyle, where it enters between the two heads of the flexor carpi ulnaris. There, the two motor branches to the flexor carpi ulnaris (FCU) muscle were identified. More distally, the branches to the medial half of the FDP were found. (Fig. 1) This was an essential step to avoid sensory impairment and usually requires the use of the operating microscope and intra-operative nerve stimulation at low intensity (1 mA) to avoid electrical diffusion and an incorrect interpretation.

Depending on the degree of preoperative spasticity, 50–80% of the isolated motor branches of fascicles were resected under the operating microscope. The resection was 5 mm long from the proximal stump, which was coagulated with bipolar forceps to prevent re-growth of fibers. When there were several nerve branches for one muscle, one or more branches could easily be sectioned completely until the global amount needed for the considered muscle was attained.

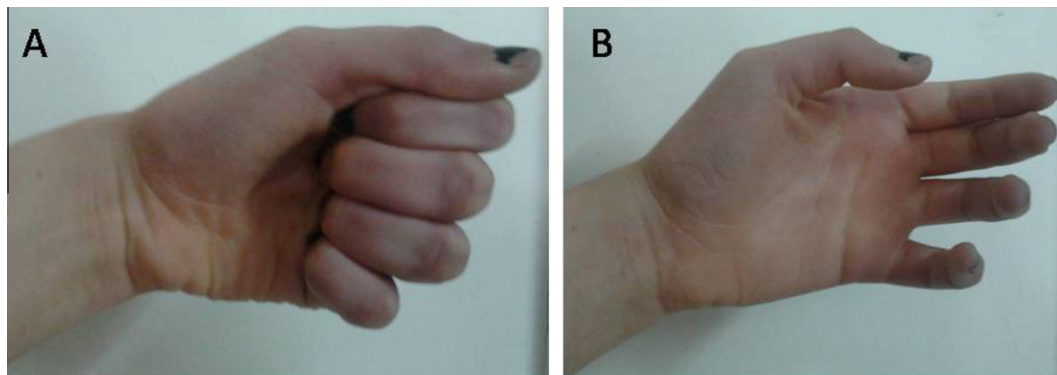
The evaluation of treatment outcome was done by measuring some of the clinical consequence of spasticity like pain,

abnormal posture and reduced functional ability. Mean post-operative follow up examination period was 21 months (range from 1 to 3, 5 years).

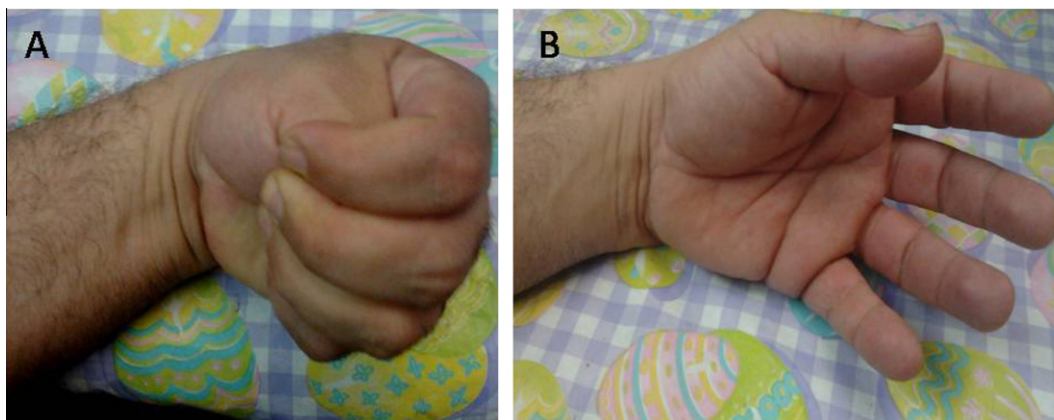
## 2. Results

SPN was performed on both ulnar and median nerves in all cases at the same setting using the same incision. All patients were followed up after surgery, at the discharge from the hospital then at 3 months postoperatively. The last postoperative follow-up examination period was from 1 to 3, 5 years.

Postoperative mortality and morbidity: There was no peri-operative mortality. As regard the morbidity, one patient had wound infection that responded well to antibiotics after culture and sensitivity. Paresis of flexors of the wrist and fingers because of excessive nerves sectioning occurred in one patient that was transient, and responded well to physical therapy. Recurrence of spasticity due to insufficient amount of sectioning could be observed in one case (10%) that was shifted to other modalities of treatment (Botulinum toxin



**Figure 2** Abnormal spastic hand posture (flexion of wrist and fingers). Before (A) and after (B) surgery.



**Figure 3** Abnormal spastic hand posture (thumb in hand deformity). Before (A) and after (B) surgery.

injection). Recurrence occurred 6 months postoperatively after initial improvement of the spasticity.

Assessment of outcome after surgery was done by comparing modified Ashworth scale preoperatively and postoperatively. The patients were classified into four groups according to their results. Group 1: Reduction of three or more grades was considered excellent, group 2: reduction of two grades was considered good, group 3: reduction of one grade was considered fair and group 4: no grade reduction was considered poor. All patients had immediate initial improvement of their spasticity.

At the last follow up examination period, excellent results were obtained in 40% of patients, good results in 40% of patients, fair results in 10% of patients, and poor results in 10% of cases.

In excellent and good results, the reduction of spasticity was accompanied by complete withdrawal of medications.

Abnormal hand posture that was present in all cases improved in 9 patients (90%) postoperatively, while pain that was present in 50% of cases improved in all these cases as measured by visual analogue scale (Figs. 2 and 3). Summary data and outcome of these 10 patients are listed in Table 3.

Also, performance and functional outcome of these 10 patients was assessed by comparing both preoperative and postoperative Oswestry scale<sup>6</sup> as shown in Table 2.

### 3. Discussion

Hypertonia of the upper limb due to spasticity causes pronation of the forearm and flexion of wrist and fingers resulting in reduction, or even loss of neuro-functional capacities.<sup>10</sup> Treatments of hypertonia of spastic origin are various and thus necessitate multidisciplinary management. Along with medication and reeducation, injections of botulinum toxin and selective neurotomies are two therapeutic options frequently chosen.<sup>11</sup> Selective fascicular neurotomy is appropriate in cases of localized spasticity, with absence of associated muscle-tendon retraction, and when a motor block using anesthetic or first test using botulinum toxin has given good functional results.<sup>12</sup> In the literature, fascicular neurotomy has essentially been used for the treatment of spastic drop foot.<sup>13,14</sup> Few precise studies have been undertaken to propose these techniques for the ventral compartment of the forearm.<sup>15,16</sup>

Generally patients do not complain about spasticity; they are more likely to be aware of stiffness, deformity and limitations in functional abilities. After a period of time, the patients will have a mixture of spasticity and muscle shortening or contracture. There are two types of hand deformities, dynamic caused by spasticity and fixed described as contracture that remains present under local blocks or anesthesia. The differentiation between dynamic from fixed deformities is of prime importance before deciding any surgical treatment. The dynamic range of motion measures are useful starting points, supplemented with instrumental measures of spasticity and its effects on function, such as motion. Spasticity should only be treated when excess muscular tone leads to further functional losses, impairs locomotion, or induces deformities, or chronic pain.<sup>17</sup> This should be explained carefully to patients what can be gained and what will not be obtained by surgery.<sup>18</sup> The strategy of using pre-operative injection tests for motor block, allows the patient to appreciate the benefit that can follow a selective neurotomy. Objectives may be cosmetic.<sup>19</sup>

In this study, the most common cause of spastic hand was cerebrovascular stroke that was found in 5 patients (50%). Also, cerebral palsy was the cause in two cases, cervical cord injury in two cases and traumatic brain injury in one case. In this study, the male to female ratio was 1 to 1 (5 males and 5 females) and their ages ranged from 15 to 58 years with mean age of 34 years. Cerebral palsy occurred in young age while cerebrovascular stroke in old age and both of them had equal sex distribution.

Assessment of the degree of spasticity in each muscle (or group of muscles) of the upper limb is essential to plan the surgical procedure. Spasticity of the pronators and flexors of the wrist and fingers mediated by the median and ulnar nerves. Thus, a variable combination of SPN can be performed, depending on the pattern and distribution of spasticity. The operative program includes designation of the spastic muscles to be targeted and the amount of denervation of the respective muscles needed.<sup>1,5</sup> For measuring the spasticity, Ashworth developed a standardized scale to document resistance to passive movements (Table 1).<sup>20</sup> It is a simple, easy to use test. The scale has been shown to correlate with other more reliable measures such as electromyography measurements. The disadvantage of this scale is the fact that it measured the combined effect of both biochemical and neural components of tone also the lack of standardization technique in performing the tone



**Table 2** Functional outcome of 10 patients who underwent SPN using Oswestry scale.<sup>6</sup>

Oswestry scale of spasticity grading (Functional outcome)	No of case Preop.	No of case Postop.
<i>G0 = Solely spastic:</i> No willed movement. Tonic reflexes or spinal reflexes present	2	
<i>G1 = Very severe spasticity:</i> Movement very poor, being a total spastic synergy and in one pattern only, i.e. either only total extension if the limb is passively flexed or only total flexion from an extended position	5	
<i>G2 = Sever spasticity:</i> Movement poor, being a marked total spastic synergy but in both flexion and extension patterns, i.e. the patient can reflex the extended limb and extend the flexed limb, with or without some isolated proximal control	3	2
<i>G3 = Moderate spasticity:</i> Movement fair, spastic synergy, but some isolated control in a small range of movement at a distal joint (ankle or wrist)		6
<i>G4 = Mild spasticity:</i> Movement good with isolated distal control possible in a good range although spastic synergy is still apparent on reinforcement by resistance to the movement, or by effort exerted in another part of the body		2
<i>G5 = No spasticity:</i> Movement normal. No spastic synergy		
Total	10	10

Preop. = Preoperative  
Postop. = Postoperative

measurements. Repetitive movement of the limb may modify stretch reflex and influence more dynamic biochemical properties of the muscle. The force applied in moving the limb should also be standardized.<sup>21</sup> Also, preoperative assessment of the patients by measuring functional disability related to their spasticity was done using Oswestry scale of Spasticity (Table 2). This scale is based on the common assumption that spasticity interferes with the quality of movement. Although other positive features of UMN syndrome may interfere with function, it is the negative features which are the most disabling. Thus, functional impairment in the UMN syndrome is multifactorial and so functional measures should not be portrayed as measurement of spasticity. In practice the scale is sensitive to change in the acute setting but has not been subjected to formal validity or reliability studies.<sup>6,21</sup>

Surgery should be performed so that excessive hypertonia is reduced without the suppression of useful muscular tone or impairment of residual motor and sensory functions.<sup>1</sup> SPN aims at re-equilibrating the tonic balance between agonist and antagonist muscles by reducing excess spasticity. Decreased spasticity is obtained by sectioning both afferents and efferent fibres of the stretch-reflex at the level of a motor nerve.<sup>5</sup>

The microsurgical selective neurotomies concerning the motor branches originating from the median nerve and ulnar nerve can be performed by one surgical approach alone since all of them originate in a short interval located between 0,5 to 13,5 cm from the horizontal line drawn through the top of the medial epicondyle. This surgical approach must be S-shaped, with a transversal incision in the cubital fossa to avoid scar adhesion here, with a short proximal curve at the bicipital medial groove and a longer distal curve following the medial edge of the brachioradialis.<sup>22</sup>

The median nerve and its collateral branches can be isolated above the PT. It then enters distally between the humeral head and the ulnar head of this muscle. This usual arrangement was found in all cases in this study, thus making it easy to dissociate the two muscle heads to expose the median nerve.

The dividing level between the humeral head of the PT and the FCR is determined. After spreading open the muscle bundles, the median nerve can be seen vertically descending through this space before running under the FDS arcade. Variations are rare.<sup>23</sup>

According to Von Lanz and Wachsmuth<sup>24</sup> the median perforates the humeral head in 2% of cases and in 3%, it runs behind the two heads. It is important to keep these particular arrangements in mind, as surgical dissection could need to be modified.<sup>23</sup>

Many authors reported their results concerning extra-muscular nerve supply in the front of forearm.<sup>24,25</sup> The PT is classically described as having extra-muscular nerve supply made by 2 branches from the median nerve. This is also what was found in 90% of the cases of this study.

Likewise, extra-muscular nerve supply of the FDS made by two or three branches at regular intervals is just as Brash described.<sup>26</sup> This organization of the nerves at regular intervals as well as the existence of two muscle heads probably explains the often unpredictable therapeutic results of injections of botulinum toxin into this muscle.<sup>27,28</sup>

For the ulnar nerve, it is possible to follow its course starting behind the medial epicondyle and continuing vertically, under the FCU arcade which can, at this level, be opened.

From the ulnar nerve, two branches, one proximal and one distal, are usually described for the FCU and one branch for the FDP. This is also what was found in all operated cases. The two branches for FCU originate in this study at 2.0 cm and at 2.5 cm on average respectively from the horizontal line drawn through the medial epicondyle.<sup>29</sup> The branch supplying the FDP is located at 4.3 cm on average from the horizontal line drawn through the top of the medial epicondyle and it divides into two.<sup>22</sup> This is also what was found in all the cases of this study.

This precise knowledge of the distribution of the median and ulnar nerves below the elbow makes selective fascicular neurotomies possible beyond the nerve trunk, by selecting collateral motor branches.<sup>15</sup> After identifying them by electri-

**Table 3** Summary data and outcome of 10 patients who underwent SPN of median and ulnar nerves.

No.	Age	Sex	Etiology	Abnormal posture of wrist and fingers	Operative program of SPN (Amount of denervation + spastic muscle)	complications	Outcome using Ashworth scale	
							Preop.	Postop. + follow up period (months)
1	18	M	Cervical cord injury	Spasticity of wrist and fingers with radial deviation + pronation	75% of motor fibers to PT, FCR, FDS, FDP + 50% of fibers to FCU		G 3	G1+ good result 22 m
2	50	M	Cerebral stroke	Spasticity of wrist and fingers with radial deviation + pronation	80% of motor fibers to PT, FCR, FDS, FDP + 50% of fibers to FCU	Wound infection	G 4	G1 excellent result 42 m
3	15	F	Cerebral palsy	Spasticity of wrist and fingers with ulnar deviation	75% of motor fibers to PT, FDS, FDP, FCU + 50% of fibers to FPL, FCR		G3	G1+ good result 23 m
4	31	M	Head injury	Spasticity of wrist and fingers with radial deviation + pronation	75% of motor fibers to PT, FCR, FDS, FDP + 50% of fibers to FCU		G 3	G1 excellent result 18 m
5	41	F	Cerebral stroke	Spasticity of wrist, fingers and thumb + pronation	75% of motor fibers to PT, FCR, FDS, FDP, FPL + 50% of fibers to FCU	Recurrence of spasticity	G 3	G 3 poor result 15 m
6	45	F	Cerebral stroke	Spasticity of wrist and fingers with radial deviation	80% of motor fibers to FCR, FDS, FDP + 65% of fibers to FCU		G 4	G1 excellent result 21 m
7	58	F	Cerebral stroke	Spasticity of wrist and fingers with radial deviation + pronation	75% of motor fibers to PT, FCR, FDS, FDP + 50% of fibers to FCU		G 3	G 2 fair result 12 m
8	49	M	Cerebral stroke	Spasticity of wrist, fingers and thumb with adduction- flexion	75% of motor fibers to , FCR, FDS, FDP, FPL, AP + 50% of fibers to FCU		G 3	G1+ good result 22 m
9	18	M	Cerebral palsy	Spasticity of wrist and fingers with ulnar deviation	80% of motor fibers to FDS, FDP, FCU + 65% of fibers to FPL, FCR		G 4	G0 excellent result 18 m
10	34	F	Cervical cord injury	Spasticity of wrist, fingers and thumb with flexion + pronation	75% of motor fibers to PT, FCR, FDS, FDP, FPL + 50% of fibers to FCU	Transient paresis of wrist flexors	G 3	G1+ good result 17 m

Preop . = preoperative Postop. = postoperative PT = pronators teres FCR = flexor carpi radialis FDS = flexor digitorum superficialis FCU = flexor carpi ulnaris.

cal stimulation, the neurotomy is performed under microscope. Each motor branch is partially sectioned (between 50% and 80%). The percentage of fibers to be sectioned depends on the degree of spasticity, and on the response to intraoperative electrical stimulation after sectioning 50% of the fibers.<sup>26</sup>

In the literature, few studies describe these selective neurotomies below the elbow. Decq et al.<sup>30</sup> have described selective neurotomy microsurgical techniques for the upper limb, but they only concern the pectoralis major and teres major. More recently, Bouttens and Delecourt<sup>31</sup> refer to neurotomy surgical techniques for the upper limb but give no practical details. Brunelli<sup>32</sup> perfectly describes this surgical approach at the cubital fossa, but extends it to the PQ or to the palm of the hand to denervate the intrinsic muscles. In this study denervation of the ulnar nerve was extended to the palm to denervate adductor pollicis in one case with thumb in palm deformity. Canovas et al.<sup>33</sup> have done a precise biometrical study of the collateral branches of the median nerve of the elbow. Segal et al.<sup>34</sup> have done partial morphological studies of some muscles in the ventral compartment of the forearm.

In this study the spasticity and abnormal hand posture had improved in 90% of cases, as measured by Ashworth scale and also by improvement in the functional score. Most patients in this study (90%) had more comfort, less pain and ability to resume physical therapy with more functional gain. The same results were reported by Sindou et al.<sup>2</sup> who performed SPN of median and ulnar nerves in 25 patients with spastic hand. The muscular tone was diminished after SPN due to interruption of the afferent component of the both afferents and efferent fibres of the stretch-reflex at the level of a motor nerve. Recurrence of spasticity occurred in one patient after initial improvement because of insufficient amount of sectioning and was treated by botulinum toxin injections and physiotherapy. The recurrence could be explained by the fact that the nerve endings of intact  $\alpha$  motor neurons sprout in an attempt to compensate for the partial denervation as regrowth has been prevented by the resection performed during neurotomy. New motor endplates appear, and the size of motor units increases in proportion to the degree of denervation.<sup>3</sup> On average, motor units increase by about five times their original size, allowing them to compensate for a loss of as much as 80% of the motoneuron pool.<sup>8</sup>

The outcome of SPN also intimately depends on the post-operative care after a successful surgery. The hand can be raised to avoid edema and mobilized as soon as possible, physical therapy beginning on the second post-operative day. An anti-thrombotic therapy is administered for 5 days after surgery, and the patient is discharged on the seventh post-operative day. Immediately thereafter, a programme of physical and occupational therapy is undertaken for at least 6 weeks.<sup>15</sup>

#### 4. Conclusion

In well-selected patients, SPN can yield good effects on refractory spasticity of the hand and its consequences. SPN can unmask residual motor function of muscles, make easier passive movements, increase comfort in daily activity, decrease pain because of spasticity and improve cosmetic appearance of the hand. Operative planning with a detailed clinical assessment of each spastic muscle is essential to determine the degree of nerve section, thus avoiding insufficient

surgery or the loss of motor strength in the concerned muscles. Neurotomy performed distally on the muscular branches warrants selectivity of the procedure, to avoid sensitive and painful complications.

#### References

1. Stoffel A. The treatment of spastic contractures. *Am J Orthop Surg* 1912;**10**:611–44.
2. Sindou M, Simon F, Mertens P, et al. Selective peripheral neurotomy (SPN) for spasticity in childhood. *Childs Nerv Syst* 2007;**23**:957–70.
3. Mertens P, Sindou M. Selective peripheral neurotomies for the treatment of spasticity. In: Sindou M, Abbott R, Keravel Y, editors. *Neurosurgery for Spasticity: A Multidisciplinary Approach*. New York: Springer; 1991, pp. 119–132.
4. Lagalla G, Danni M, Reiter F, et al. Post stroke spasticity management. *Am J Phys Med Rehab* 2000;**79**:377–84.
5. Hodgkinson I, Sindou M. Decision making for treatment of disabling spasticity in children in “Neurosurgical Management of Disabling Spasticity” (Sindou ed.). *Oper Tech Neurosurg* 2004; **7**:120–3.
6. Mertens P, Sindou M. Surgical management of spasticity. In: Barnes MP, Johnson GR, editors. *Clinical Management of Spasticity*. Cambridge UK: Cambridge University Press; 2001, pp. 239–65.
7. Decq P, Cuny E, Filipetti P, et al. Peripheral neurotomy in the treatment of spasticity Indications, techniques and results in the lower limbs. *Neurochirurgie* 1998;**44**:175–82.
8. Dengler R, Konstanzer A, Hesse S, et al. Collateral nerve sprouting and twitch forces of single motor units in conditions with partial denervation in man. *Neurosci Lett* 1989;**97**:118–22.
9. Decq P, Filipetti P, Cubillos A, et al. Soleus neurotomy for treatment of the spastic equinus foot Groupe d’Evaluation et de Traitement de la Spasticite et de la Dystonie. *Neurosurgery* 2000;**47**:1154–60.
10. O’ Dwyer NJ, Ada L, Neilson PD. Spasticity and muscle contracture following stroke. *Brain* 1996;**119**(5):1737–49.
11. Tardieu G. Spasticity: an ill-defined condition abstract retrospective neurology in the central and peripheral nervous. *Venice World Federation Neurol* 1983;**1**:24–6.
12. Taira T, Hori T. Selective peripheral neurotomy for spasticity in cerebral palsy. *No Shinkei Geka* 2001;**29**(12):1137–50.
13. Berard C, Sindou M, Berard J, et al. Selective neurotomy of the tibial nerve in the spastic hemiplegic child: an explanation of the recurrence. *J Pediatr Orthop B* 1998;**7**:66–70.
14. Deltombe T, Gustin T, Laloux P, et al. Selective fascicular neurotomy for spastic equinovarus foot deformity in cerebral palsy children. *Acta Orthop Belg* 2001;**67**:1–5.
15. Maarrawi J, Mertens P, Sindou M. Surgery in the Peripheral Nerves for Upper Limb Spasticity. *Oper Tech Neurosurg* 2005; **7**:147–52.
16. Msaddi AK, Mazroue AR, Shahwan S, et al. Microsurgical selective peripheral neurotomy in the treatment of spasticity in cerebral palsy children. *Stereotact Funct Neurosurg* 1997;**69**:251–8.
17. Decq P, Filipetti P, Feve A, et al. Peripheral selective neurotomy of the brachial plexus collateral branches for treatment of the spastic shoulder: anatomical study and clinical results in five patients. *J Neurosurg* 1997;**86**:648–53.
18. Garland DE, Thompson R, Waters RL. Musculocutaneous neurotomy for spastic elbow in flexion in non-functional upper extremities in adults. *J Bone Joint Surg (Am)* 1981;**62**:108–12.
19. Purohit AK, Raju BSV, Shiv Kumar K, et al. Selective musculocutaneous fasciculotomy for spastic elbow in cerebral palsy: a preliminary study. *Acta Neurochir (Wien)* 1998;**140**:473–8.

20. Pisano F, Miscio G, Del CC, et al. Quantitative measures of spasticity in post stroke patients. *Clin Neurophysiol* 2000;**111**(6):1015–22.
21. Pandyan AD, Johnson GR, Price CL, et al. A review of the properties and limitations of the Ashworth and modified Ashworth scales as a measure of spasticity. *Clin Rehab* 1999; **13**(5):373–83.
22. Lepage D, Parratte B, Tatu L, et al. Extra- and intramuscular nerve supply of the muscles of the anterior antibrachial compartment: applications for selective neurotomy and for botulinum toxin injection. *Surg Radiol Anat* 2005;**27**:420–30.
23. Gunther SF, DiPasquale D, Martin R. The internal anatomy of the median nerve in the region of the elbow. *J Hand Surg (Am)* 1992;**17**:648–56.
24. Lanz T V, Wachsmuth W P. Anatomie. Arm. Springer; Berlin-Göttingen-Heidelberg 1959; 144.
25. Gros C, Frerebeau P, Benezech L, et al. Selective radicular neurotomy. In: Simon L, editor. *Actualities in functional physical therapy*. Paris: Masson; 1977, pp. 230-235.
26. Brash JC. Neuro-vascular hila of limb muscles. E&S Livingstone, Edinburgh 1955; 100.
27. O'Brien CF. Injection techniques for botulinum toxin using electromyography and electrical stimulation. *Muscle Nerve* 1997; **6**:176–80.
28. Rousseaux M, Kozlowski O, Froger J. Efficacy of botulinum toxin A in upper limb function of hemiplegic patients. *J Neurol* 2002; **249**:76–84.
29. Lim AY, Kumar VP, Hua J, et al. The neuromuscular of the flexor carpi ulnaris. *Plast Reconstr Surg* 1999;**103**:1046–51.
30. Decq P. Peripheral neurotomies for the treatment of focal spasticity of the limbs. *Neurochirurgie* 2003;**49**:293–305.
31. Bouttens D, Delecourt C. Les traitements orthopédiques des conséquences de la spasticité au membre supérieur. *Neurochirurgie* 2003;**49**:353–7.
32. Brunelli G, Brunelli F. Partial selective denervation in spastic palsies (hyponeurotization). *Microsurgery* 1983;**4**:221–4.
33. Canovas F, Moulleron P, Bonnel F. Biometry of the muscular branches of the median nerve to the forearm. *Clin Anat* 1998;**11**:239–45.
34. Segal RL, Catlin PA, Krauss EW, et al. Anatomical partitioning of three human forearm muscles. *Cells Tissues Organs* 2002; **170**:183–97.