



ORIGINAL ARTICLE

Management of essential hyperhidrosis of upper limbs by radiofrequency thermocoagulation of second thoracic ganglion

Wael Fouad

Alexandria Faculty of Medicine, Neurosurgery Department, Sultan Hussein Street, Azarita, Alexandria, Egypt

Received 5 June 2011; accepted 1 July 2011

KEYWORDS

Essential hyperhidrosis;
Thoracic sympathectomy;
Radiofrequency
thermocoagulation

Abstract *Introduction:* Essential hyperhidrosis is an idiopathic condition characterized by markedly excessive sweating especially in the hands.

Objective: This study was done to evaluate the functional results of radiofrequency thermocoagulation of T2 ganglion in 10 patients suffered from essential hyperhidrosis of both upper limbs.

Methods: This retrospective study was carried out on 10 patients suffered from essential hyperhidrosis of both upper limbs. The male to female ratio was 2 to 3 (4 males and 6 females) and their ages ranged from 16 to 28 years. Simultaneous palmar and plantar sweating was present in five patients (50%), simultaneous palmar and craniofacial hyperhidrosis in two patients (20%), and simultaneous palmar and axillary hyperhidrosis in one patient (10%), while palmar hyperhidrosis alone was found only in two patients (20%). All cases underwent surgery in the form of radiofrequency thermocoagulation (RFT) of T2 on both sides under local anesthesia and sedation using C-arm radiological guidance. Mean postoperative follow up examination period was 24 months.

Results: There was no operative mortality. Pneumothorax occurred on left side in one patient. Transient partial Horner's syndrome occurred on the right side in another patient. Postoperatively, 9 patients (90%) had clinical improvement of their palmar sweating. The last patient had partial

Keywords: Essential hyperhidrosis; Thoracic sympathectomy; Radiofrequency thermocoagulation

E-mail address: waelfouad_67@hotmail.com

2090-5068 © 2011 Alexandria University Faculty of Medicine.
Production and hosting by Elsevier B.V. All rights reserved.

Peer review under responsibility of Alexandria University Faculty of Medicine.

doi:10.1016/j.ajme.2011.07.006



Production and hosting by Elsevier

improvement on right side and no improvement on the left side. The operation was repeated in one case with recurrence on the right side who improved. At the last follow up, excellent results were obtained in 90% of limbs, fair results in 5% of limbs, and poor results in 5% of limbs.

Conclusion: The results of this study indicate that second thoracic ganglionectomy and sympathectomy performed with the use of percutaneous RFT is a very effective treatment for palmar hyperhidrosis that provide excellent immediate and long-term results as well as a low complication rate.

© 2011 Alexandria University Faculty of Medicine. Production and hosting by Elsevier B.V. All rights reserved.

1. Introduction

Essential hyperhidrosis is characterized by excessive eccrine sweating (watery and nonodorous) beyond that required for cooling and sufficiently heavy so as to be considered an impairment of good health.^{1,2} The excessive sweating most commonly involves the hands or a combination of the hands and feet. Axilla is not uncommonly involved as well. Facial sweating can occur as a relatively isolated phenomenon or as part of the palmar plus plantar presentation, and occasional patients experience excessive sweating over the trunk as well.³ In 70% of patients, the onset of excessive sweating is noted in infancy, but 20% note the onset in adolescence.⁴

The congenital variant has a slight female predominance. Perhaps 25% of patients may have one or more involved close relatives, warranting the designation of this as a familial variant. Those with a familial variant seem to be more likely to experience widespread excessive sweating and may be at higher risk of developing compensatory hyperhidrosis after surgery.^{1,5}

Essential hyperhidrosis seems to be especially prevalent in Taiwan and Israel, where the familial variant seems to be more common than elsewhere, but the disorder is encountered worldwide.⁶

The condition can present both an occupational and a social handicap to affected person. The diagnosis is easily made by history and examination of the patient.⁷ Although mild cases can be treated with drying agents or anticholinergic drugs, severe cases are usually resistant to conservative treatment and the most effective permanent treatment is surgical sympathectomy.⁸ Opinions differ regarding the extent of sympathectomy. Recent experience has demonstrated that complete sympathetic denervation of upper limbs can be achieved by removal of the second thoracic ganglion alone.^{9,10}

The aim of this work was to evaluate the functional results of radiofrequency thermocoagulation of second thoracic

ganglion in 10 patients suffered from essential hyperhidrosis of upper limbs and to compare these results with the results of the other authors reported in the literature.

2. Methods

This retrospective study was carried out on 10 patients suffered from essential hyperhidrosis of both upper limbs. This study was done in Alexandria hospitals over a period of 3 years starting from January 2006 to December 2008. The male to female ratio was 2 to 3 (4 males and 6 females) and their ages ranged from 16 to 28 years with mean age of 21 years.

Simultaneous palmar and plantar hyperhidrosis was present in 5 patients (50%), simultaneous palmar and craniofacial hyperhidrosis in 2 patients (20%), and simultaneous palmar and axillary hyperhidrosis in 1 patient (10%), while palmar hyperhidrosis alone was found only in 2 patients (20%) (Table 1).

All cases underwent surgery in the form of radiofrequency thermocoagulation (RFT) of second thoracic ganglion on both sides under local anesthesia and sedation using C-arm radiological guidance. Only in 1 patient with hyperhidrosis of palm and axilla an additional RFT of T3 ganglion was done. The patient was positioned prone on the operating table. The site of needle puncture was 3 cm lateral from the midline of the base of the spinous process of the second thoracic vertebra. The needle was introduced through the second intercostal space. The angle of orientation was 101° from the horizontal plane and directed medially towards the midline. The depth of penetration was approximately from 6 to 6.5 cm (Fig. 1). Under C-arm radiological control we checked the optimal position of the needle relative to the second thoracic vertebra both in P–A and lateral views. (Figs. 2 and 3). On P–A view the needle was positioned first 2–5 mm adjacent to T2–T3 vertebral interspace, then repositioned 2–5 mm adjacent to the

Table 1 Extent of hyperhidrosis, extent of RFT and outcome of cases.

Extent of hyperhidrosis	No.	Extent of RFT	Outcome			
			Palmar	Planter	Facial	Axillary
Palmar	2	T2	1 Excellent 1 Fair + poor			
Palmar + planter	5	T2	5 Excellent	1 Excellent 2 Fair 2 Poor		
Palmar + facial	2	T2	2 Excellent		2 Excellent	
Palmar + axillary	1	T2 + T3	1 Excellent			1 Excellent
Total	10		10	5	2	1

One patient with palmar and planter hyperhidrosis had hyperhidrosis over all his body.

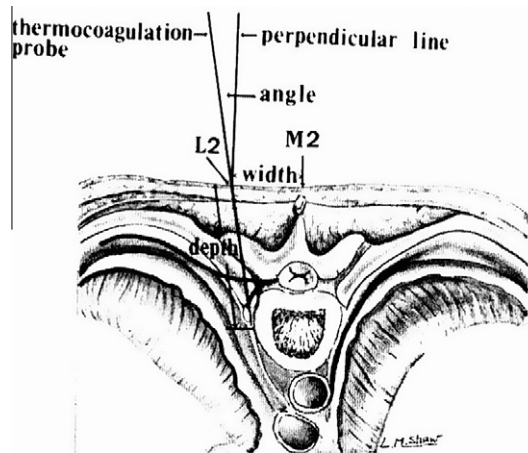


Figure 1 Cross section at the level of second thoracic ganglion shows the entry point (L2), direction and depth of the probe M2 = mid point between the second and third dorsal spinous processes.²²

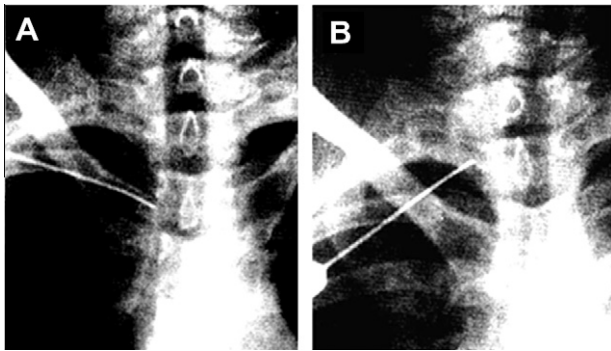


Figure 2 Radiological placement of electrode for RFT of T2 ganglion. (A) The electrode is initially placed adjacent to the T2–T3 interspace. (B) The electrode is placed alongside the T3 vertebral body beneath the head of the second rib.

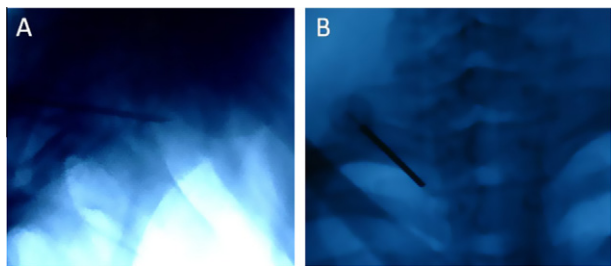


Figure 3 Radiological placement of electrode for RFT of T2 ganglion. (A) Lateral view showing the electrode is placed at the mid vertebral body of T2. (B) P–A view showing the electrode is placed alongside the T3 vertebral body.

mid to rostral portion of the body of T2 beneath the head of the second rib. On lateral radiological view the tip of the needle was at the middle of the body of the second thoracic vertebra. The generator of radiofrequency used was RFG-3C from

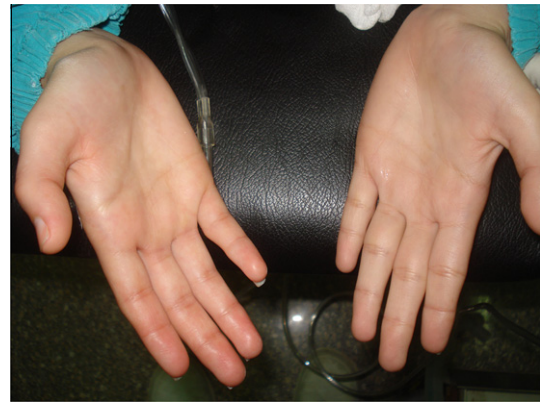

Figure 4 Right palmar flushing and sweating during RFT (stimulation mode) of right T2 ganglion.



Figure 5 The right hand is dry and flushed after the completion of RFT of right T2 ganglion.

Radionics. Before lesion making, low voltage stimulation of 0, 1–0, 5 V at 50–75 Hz, for 1 min duration was done and the patient was observed for radicular pain or development of Horner's syndrome. An increase in hand temperature during stimulation was a good sign that the electrode in a good position.

The straight temperature monitoring electrode (10 mm tip length) was used to perform an initial lesion at 80–90 °C for 180 s for each location, then the lesion was repeated at the same temperature and duration after withdrawal the electrode by 0.5 cm in each location. A flush and sweating was usually noted in the hand during stimulation due to cutaneous vasodilatation (Fig. 4). After the completion of RFT the hand was dry and flushed (Fig. 5).

Postoperative follow up examination period ranged from 1 to 3 years with a mean of 2 years.

3. Results

The operation was performed on both sides for all 10 patients on the same setting. 18 sides were operated for RFT of T2 ganglion while two sides in 1 patient with simultaneous palmar

Table 2 Summary data of 10 patients with essential hyperhidrosis who underwent RFT of T2 ganglion.

No.	Age	Sex	Extent of hyperhidrosis	No. of RFT lesions		Operative time in minutes		Complications			Outcome (relief of hyperhidrosis)			Follow up period in months
				Right side	Left side	Right side	Left side	Excellent	Fair	Poor				
1	19	F	Palm and sole	4 Lesions	3 Lesions	45 min				Both sides			12 months	
2	28	M	Palm and craniofacial	3 Lesions	2 Lesions	40 min				Both sides			26 months	
3	21	F	Palm and sole	3 Lesions	2 Lesions	35 min				Both sides			23 months	
4	20	M	Palm and axilla	4 Lesions	2 Lesions	40 min		Partial right Horner's syndrome		Both sides			36 months	
5	19	F	Palm	4 Lesions	4 Lesions	50 min		Left side Pneumothorax		Both sides	Right side	left side	25 months	
6	21	M	Palm, sole and all body	4 Lesions	2 Lesions	45 min				Both sides			23 months	
7	23	F	Palm and sole	3 Lesions/4 lesions	3 Lesions	40 min		Recurrence on right side		Both sides			15 months	
8	19	M	Palm and craniofacial	3 Lesions	3 Lesions	40 min				Both sides			30 months	
9	24	F	Palm and sole	2 Lesions	2 Lesions	30 min				Both sides			24 months	
10	16	F	Palm	3 Lesions	3 Lesions	45 min				Both sides			30 months	

Patient number 7 had recurrence on the right side after 12 months, the operation was repeated and the patient had excellent result during 15 months after the second operation.

and axillary hyperhidrosis were operated for T2 and T3 ganglion.

3.1. Technical success

RFT was technically successful (completed) in all cases. If the patients could not localize or quantify the lesion during the procedure we could successfully complete the procedure on the basis of observation of palmar hyperemia in the affected side or by using radiological guidance.

3.2. Postoperative morbidity and mortality

There was no operative mortality. Pneumothorax occurred on left side in one patient Transient partial Horner's syndrome occurred on the right side in another patient (loss of ciliospinal reflex and miosis). Compensatory hyperhidrosis occurred in on patient with preoperative hyperhidrosis in all his body that responded well to anticholinergic drugs.

3.3. Outcome of cases

All the patients had immediate initial relief of sweating. Follow up of the patients was done at one month, three months, and thereafter each 6 months. The evaluation was done clinically. The patients were classified into 3 groups according to their results. Group1: excellent results: complete relief of sweating, Group 2: fair results: partial relief of sweating, Group 3: poor results: no improvement of sweating. Postoperatively, excellent results were obtained in 90% of sides, fair results in 5% of sides, and poor results in 5% of sides.

Before treatment, simultaneous palmar and plantar sweating was present in 5 patients (50%). After treatment, 20% of these patients had dramatic improvement in their plantar hyperhidrosis, 40% had decreased plantar hyperhidrosis, and another 40% of patients had no improvement or a slight increase in their plantar hyperhidrosis. The 2 patients with simultaneous palmar and facial had excellent results as regard both palmar and facial hyperhidrosis. The patient with simultaneous palmar and axillary hyperhidrosis had excellent improvement as regards both palmar and axillary hyperhidrosis after RFT of T2 and T3 ganglia (Table 1).

3.4. Recurrence

Recurrence occurred in 1 patient on the right side (5%) after 12 months. Another radiofrequency lesion of the T2 ganglion was done in this case with recurrence. This patient improved and had excellent results after the second RFT. Summary data and outcome of these 10 patients are listed in Table 2.

4. Discussion

The sympathetic supply of the upper limb is derived from the upper thoracic segments of the spinal cord from T2 to T6. These fibers are distributed up the sympathetic trunk and mainly via the cervicothoracic (stellate) ganglion to the brachial plexus and arteries of the upper limb. They innervate

all sweat glands, erector muscles of the hairs and the muscular walls of the blood vessels.¹¹

Thoracic sympathectomy has been found to be of value in the treatment of certain pain syndromes, vascular disorders, and hyperhidrosis affecting the upper extremities.¹² Hyperhidrosis of the upper extremity is one of the most common indications for thoracic sympathectomy.^{13–17} Hyperhidrosis can be a source of great embarrassment and considerable disability to the patient. It may involve the entire body, including the legs and head, but symptoms are most severe and of the greatest discomfort in the upper extremities. The patients have symptoms that often date from childhood or early adolescence. Such individuals report reluctance to shake hands or touch other people, and often wear gloves to disguise their condition.¹⁵ The diagnosis is readily confirmed by inspection of the extremities.¹⁶ Before surgery is considered for hyperhidrosis, all non surgical options should be tried. Also it is important to rule out other disorders such as thyrotoxicosis, pheochromocytoma and carcinoid syndrome as causes of excessive sweating.¹⁷ In this study, all patients had their symptoms dated since early adolescence. Also, in this study, the reasons for seeking treatment included job-related inconvenience (e.g., writing, painting, fine manual work) in 6 cases (60%), inconvenience in practical daily tasks (e.g., loose grip of objects) in two cases (20%) and psychological hindrance (e.g., sense of inferiority or embarrassment) in two cases (20%). Patients with hyperhidrosis had previously tried non surgical treatments, which turned out to be ineffective.

The use of transthoracic electrocoagulation for the treatment of essential hyperhidrosis was first described by Malone et al.¹⁴ The aim of this operation is to denervate the sympathetic supply to the upper limb without interfering with the stellate ganglion which supplies the head and neck. Division of the afferent or efferent fibers of the stellate ganglion will lead to Horner's syndrome.¹⁸ Recent clinical and laboratory findings indicate that T2 ganglionectomy is likely sufficient to treat palmar hyperhidrosis. If the hyperhidrosis includes the axilla, the T3 and possibly T4 ganglia should be thermocoagulated as well. Also the surgical intent was not to eliminate all sweating from their hands, because this tended to substitute undesirable excessive dryness and skin cracking for the excessive sweating.^{9,10}

The radiofrequency lesion has been claimed to be the most effective and widely used method for localized therapeutic destruction of neural tissue. The basic principle for radiofrequency ablation of a sympathetic lesion involves accuracy and precision. Sensory electrical stimulation occasionally elicits either a vague sensation or pain at the target area. Motor stimulation usually serves as an indicator of sufficient distance from the ventral root. To maximize the probability of success, the radiofrequency electrode must be located as close to the sympathetic ganglion as possible.^{19,20}

In 1984, a percutaneous, X-ray guided radiofrequency technique devised by Wilkinson²¹ has proved to be quite effective and safe for upper thoracic sympathectomy. In his series, the operation was conducted according to an expected anatomical location of the upper thoracic ganglia lying in the retropleural space.

In 1988, Chuang et al.²² reported a stereotactic procedure for percutaneous RFT of upper thoracic ganglion in 10 cases with palmar hyperhidrosis. In their results they reported the real anatomical relationship between the second

thoracic sympathetic ganglia and the tip of thermocoagulation probe that was revealed in cadaver studies and was adopted for thermocoagulation in a living human body. According to their study, the average size of the T2 ganglion in Chinese people is 9.8 mm in length, 7.4 in width, and 2.8 mm in thickness. They used a thermal probe with a 10-mm tip, that was applied to the T2 or T3 ganglion for 6 min at 85–90 °C in 10 patients with palmar hyperhidrosis that resulted in total neuronal death within the thoracic ganglia. They concluded that their technique should result in a better outcome compared to other methods, also it may be used to treat Buerger's disease, Raynaud's disease vasospastic/sympathetic pain of the upper extremities.

According to the anatomical study of Wilkinson²³ in 1988, the T2 ganglion is situated roughly in the middle of the vertebrae rostro-caudally and 1/3 dorso-ventrally. Others have indicated that approximately 90% of the T2 or T3 sympathetic trunks are located on the head of the corresponding rib.²⁴ Another study found that the second thoracic ganglion is usually located (in 92.5% of patients) in the second intercostal space at the level of the intervertebral disc, between the second and the third thoracic vertebrae.²⁵

Although a variation of 1–1.5 cm of exact anatomical position is not of great importance during a surgical sympathectomy, it is critical during radiofrequency electrode placement. Therefore, multiple radiofrequency lesions were done.²⁶ In this study three dimensional system of coordinates described by Chuang et al. was applied, also a thermal probe with a 10-mm tip, that was applied to the T2 or T3 ganglion for 9–12 min at 85–90 °C on each side of 10 patients with palmar hyperhidrosis. In this study an average of three lesions for 9 min duration were done on each side of the 10 patients.

Before anesthesia, during the introduction of the needle, patients were asked to take a light breath and to tell the doctor if they felt like coughing. The needle was elevated immediately when signs of pneumothorax (i.e., coughing, sensation of a need to cough) were suspected or were reported by the patient. In this study this occurred in 1 patient who developed Pneumothorax on the left side postoperatively.

During the procedure, palm skin temperature measurement was used to demonstrate sympathetic denervation. Other previous studies reported that the T2 sympathetic ganglion determines palm skin temperature in patients with essential palmar hyperhidrosis.^{9,10}

After the procedure, patients are out of bed and fully active and can be discharged on the same operative day.

Chuang et al.²⁷ reported final success rate of 99.9% in their series of 1742 (1688 palmar + 54 facial) hyperhidrotic patients with the use of this technique of ganglionectomy and sympathectomy. The facial innervation ascending from the T2 ganglion may be responsible for the effectiveness of T2 lesioning in patients with facial hyperhidrosis. In their study during a long-term follow-up assessment ranging from 1 to 8 years, recurrence had developed in 268 sides, and retreatment was successful in all of these sides. This result was similar to the final success rate that Rex et al.²⁸ reported in 1152 cases. The final cure rate using this percutaneous technique is higher than that described in reports in which other methods were used. The postoperative complication rates of 0.2% for pneumothorax and 0.15% for partial Horner's syndrome are very low. In this study the final success rate was 99, 5% and postoperative complication rate 5% for pneumothorax and 5% of partial

Horner's syndrome. All of these patients returned to normal within 6 months. Also, open surgical removal of T2 and T3 ganglia produced many postoperative complications, such as pneumothorax, Horner's syndrome, intercostal artery bleeding, gustatory sweating, and paravertebral muscular atrophy.^{27,28}

Chuang et al.²⁷ reported that most patients with palmar hyperhidrosis also have sole hyperhidrosis which is problematic. After the use of the same technique for the control of palmar and craniofacial hyperhidrosis, however, they found that 24% of plantar hyperhidrosis improved dramatically, 68% of plantar hyperhidrosis improved partially, and only 8% plantar hyperhidrosis did not improve or became worse. Thus, they reported a dramatic or partial improvement was achieved in 92% of patients. This result is similar to the success rate of Lin et al.²⁹ but still higher than the 23.3–44% rate of improvement reported in other studies.^{30–32}

In this study, before treatment, simultaneous palmar and plantar sweating was present in five patients 50% of patients. After treatment, 20% of these patients had dramatic improvement in plantar hyperhidrosis, 40% had decreased plantar hyperhidrosis, and another 40% of patients had no improvement or a slight increase in their plantar hyperhidrosis.

It is well established that compensatory hyperhidrosis often occurs after thoracic sympathectomy.³³ The extent of compensatory hyperhidrosis in the present study was not assessed, however, because this was not the original purpose for the study, and an adequate analysis would have required additional planning and follow-up that would have exceeded the scope of this study. The pathologic form of compensatory hyperhidrosis (excessive sweating over the trunk, inguinal area, or face severe and persistent enough even at rest or in a cool environment) is considered a significant complication. It seems to develop in patients with the familial type of the disease or with wide spread areas of heavy sweating before surgery.³⁴ In this study one case (10%) developed compensatory hyperhidrosis, but the pathological form did not occur.

Although the number of cases in which this procedure has been used was small, the procedure offers such a major advance over presently available alternative open surgical techniques that presentation seems warranted. This technique is effective, safe, has fewer side effects, and is certainly easier with less cost effective than presently available surgical alternative. This is especially true for patients who require bilateral sympathectomy. Patients no longer need to be hospitalized and to undergo a major surgical intervention under general anesthesia to achieve satisfactory thoracic sympathectomy. The ability to achieve sympathectomy without the need for general anesthesia and major surgical intervention is especially important for patients with hyperhidrosis, whose disease is not considered life-endangering, and for patients who are candidates for sympathectomy because of cardiac problems but who may be poor surgical risks.^{22,35} Because of few complications and a high success rate, it should be considered an attractive first-line alternative in the management of severe hyperhidrosis.^{27,36}

5. Conclusion

The results of this study indicate that second thoracic ganglionectomy and sympathectomy performed with the use of per-

cutaneous RFT is a very effective treatment for palmar and craniofacial hyperhidrosis that provide excellent immediate and long-term results as well as a low complication rate. The technique is safe, has fewer side effects, and is certainly easier with less cost effect than other surgical alternative. The technique is also effective as a retreatment for recurrences.

References

1. Malone PS, Cameron AEP, Rennie JA. The surgical treatment of upper limb hyperhidrosis. *Br J Dermatol* 1986;**115**:81–4.
2. Golueke PJ, Garrett WV, Thomason JE, et al. Dorsal sympathectomy for hyperhidrosis: the posterior paravertebral approach. *Surgery* 1988;**103**:568–72.
3. Cohen Z, Levi I, Pinski I, et al. Thoracoscopic upper thoracic sympathectomy for primary palmar hyperhidrosis: the combined pediatric, adolescents and adult experience. *Eur J Surg Suppl* 1998;**580**:5–8.
4. Fox AD, Hands L, Collin J. The results of thoracoscopic sympathetic trunk transection for palmar hyperhidrosis and sympathetic ganglionectomy for axillary hyperhidrosis. *Eur J Vasc Endovasc Surg* 1999;**17**:343–6.
5. Graham AN, Owens WA, McGuigan JA. Assessment of outcome after thoracoscopic sympathectomy for hyperhidrosis in a specialized unit. *J R Coll Surg Edinb* 1996;**41**:160–3.
6. Kao MC. Laser endoscopic sympathectomy for palmar hyperhidrosis. *Lasers Surg Med* 1992;**12**:308–12.
7. Shih CJ, Lin MT. Thermoregulatory sweating in palmar hyperhidrosis before and after upper thoracic sympathectomy. *J Neurosurg* 1979;**50**:88–94.
8. R.W. Hardy, J.W. Bay, Surgery of the sympathetic nervous system. I: H.H. Schmidek, W.H. Sweet (Eds.), Operative neurosurgical techniques, Vol New York, Grune et Stratton, 1988, pp. 1271–1280.
9. O' Riordain DS, Maher M, Waldron DJ, et al. Limiting the anatomic extent of upper thoracic sympathectomy for primary palmar hyperhidrosis. *Surg Gynecol Obstet* 1993;**176**:151–4.
10. Herz DA, Looman JE, Ford RD, et al. Second thoracic sympathetic ganglionectomy in sympathetically maintained pain. *J Pain Symptom Mgt* 1993;**8**:483–91.
11. Masters A, Rennie JA. Endoscopic transthoracic sympathectomy for idiopathic upper limb hyperhidrosis. *Clin Auton Res* 1992;**2**:349–52.
12. Weale FE. Upper thoracic sympathectomy by transthoracic electrocoagulation. *Br J Surg* 1980;**67**:71–2.
13. Byrne J, Walsh TN, Hederman WP. Endoscopic transthoracic electrocautery of the sympathetic chain for palmar and axillary hyperhidrosis. *Br J Surg* 1990;**77**:1046–9.
14. Malone PS, Duignan JP, Hederman WP. Transthoracic electrocoagulation (T.T.E.C.)—a new and simple approach to upper limb sympathectomy. *Ir Med J* 1982;**75**:20–1.
15. Chu D, Shi PK, Wu CM. Transthoracic endoscopic sympathectomy for treatment of hyperhidrosis palmaris. *Kaohsiung J Med Sci* 1997;**13**:162–8.
16. Bass A, Inovrotzlavski S, Adar R. Upper dorsal sympathectomy for palmar hyperhidrosis. *Isr J Med Sci* 1983;**19**:112–5.
17. Mares AJ, Steiner Z, Cohen Z, et al. Transaxillary upper thoracic sympathectomy for primary palmar hyperhidrosis in children and adolescents. *J Pediatr Surg* 1994;**29**:382–6.
18. Gordon A, Zechmeister K, Collin J. The role of sympathectomy in current surgical practice. *Eur J Vasc Surg* 1994;**8**:129–37.
19. Hehir DJ, Brady MP. Long-term results of limited thoracic sympathectomy for palmar hyperhidrosis. *J Pediatr Surg* 1993;**28**:909–11.
20. Bay JW, Dohn DF. Surgical sympathectomy. In: Wilkins RH, Rengachary SS, editors. *Neurosurgery*, vol 2. New York: McGraw-Hill; 1985. p. 1912–7.

21. Wilkinson HA. Percutaneous radiofrequency upper thoracic sympathectomy: a new technique. *Neurosurgery* 1984;**15**:811–4.
22. Chuang KS, Liou NH, Liu JC. New stereotactic technique for percutaneous thermocoagulation upper thoracic ganglionectomy in cases of palmar hyperhidrosis. *Neurosurgery* 1988;**22**:600–4.
23. Wilkinson HA, Hardy RW. New stereotactic technique for percutaneous thermocoagulation upper thoracic ganglionectomy in cases of palmar hyperhidrosis. *Neurosurgery* 1988;**22**:603–4.
24. Yarzebski JL, Wilkinson HA. T2 and T3 sympathetic ganglia in the adult human: a cadaver and clinical–radiologic study and its clinical application. *Neurosurgery* 1987;**21**:339–42.
25. Rengachary S. T2 and T3 sympathetic ganglia in the adult human: A cadaver and clinical-radiographic study and its clinical application. *Neurosurgery* 1987;**21**:342.
26. Hashmonai M, Kopelman D, Kein O, et al.. Upper thoracic sympathectomy for primary palmar hyperhidrosis: long-term follow-up. *Br J Surg* 1992;**79**:268–71.
27. Chuang KS, Liu JC. Long-term Assessment of Percutaneous Stereotactic Thermocoagulation of Upper Thoracic Ganglionectomy and Sympathectomy for Palmar and Craniofacial Hyperhidrosis in 1742 Cases. *Neurosurgery* 2002;**51**(4):963–70.
28. Rex LO, Drott C, Claes G, et al.. The Boras experience of endoscopic thoracic sympathectomy for palmar, axillary, facial hyperhidrosis and facial blushing. *Eur J Surg Suppl* 1998;**580**:23–6.
29. Lin CL, Yen CP, Howng SL. The long-term results of upper dorsal sympathetic ganglionectomy and endoscopic thoracic sympathectomy for palmar hyperhidrosis. *Surg Today* 1999;**29**:209–13.
30. Gjerris F, Olesen HP. Palmar hyperhidrosis: long-term results following high thoracic sympathectomy. *Acta Neurol Scand* 1975;**51**:167–72.
31. Adar R. Surgical treatment of palmar hyperhidrosis before thoracoscopy: experience with 475 patients. *Eur J Surg Suppl* 1994;**572**:9–11.
32. Shih CJ, Wang YC. Thoracic sympathectomy for palmar hyperhidrosis: report of 457 cases. *Surg Neurol* 1978;**10**:291–6.
33. Adar R. Compensatory sweating after upper dorsal sympathectomy. *J Neurosurg* 1979;**51**:424–5.
34. Wilkinson HA. Percutaneous radiofrequency upper thoracic sympathectomy. *Neurosurgery* 1996;**38**:715–25.
35. Tan KK. Sympathectomy for wet dripping palms. *Singapore Med J* 1991;**32**:119–20.
36. Lucas A, Rolland Y, Journeaux N, et al.. Computed tomography guided thoracic sympathectomy for palmar hyperhidrosis. *J Cardiovasc Surg (Torino)* 1998;**39**:387–9.