

HOSTED BY



Contents lists available at ScienceDirect

# Alexandria Journal of Medicine

journal homepage: <http://www.elsevier.com/locate/ajme>

## Original Article

# The role of eugenol in the prevention of chromium-induced acute kidney injury in male albino rats

Ramez A.E. Barhoma

Physiology Department, Faculty of Medicine, Tanta University, Egypt

## ARTICLE INFO

### Article history:

Received 22 October 2017

Revised 10 April 2018

Accepted 31 May 2018

Available online 19 June 2018

### Keywords:

Eugenol

Potassium dichromate

Antioxidant

Acute kidney injury

## ABSTRACT

**Background:** Potassium dichromate induces nephrotoxicity mainly due to increased cellular oxidative stress.

**Objectives:** To evaluate the possible renoprotective effects of eugenol on the damage induced by potassium dichromate poisoning in male rats.

**Methods:** 30 male Wistar rats were divided into 3 groups, 10 rats in each group; Control group: given olive oil orally (5 mL/kg body weight) for 10 consecutive days. Potassium dichromate (PDC) group: received olive oil orally (5 mL/kg body weight) for 10 consecutive days, then a single s.c. injection of PDC (15 mg/kg) was given in the tenth day. And eugenol + PDC group: received eugenol orally (100 mg/kg body weight/day) for 10 consecutive days and a single s.c. injection of PDC (15 mg/kg) in the tenth day.

Then the animals were anaesthetized, blood samples were taken from the abdominal aorta, for measurement of serum urea and creatinine, and lactate dehydrogenase (LDH). Also reduced glutathione (GSH), malondialdehyde (MDA), superoxide dismutase (SOD) and tumor necrosis factor alpha (TNF- $\alpha$ ) were monitored in renal tissue.

**Results:** PDC caused significant increase in serum urea, creatinine and LDH levels; this was accompanied with significant decrease in renal GSH and SOD contents, and increase in renal MDA and TNF- $\alpha$ . Histopathological investigations provoked tubular necrosis associated with mononuclear cell infiltration. Pretreatment of rats with eugenol significantly change all previously mentioned PDC-induced effects.

**Conclusion:** The findings of the current study revealed that eugenol protected the kidney against PDC-induced acute kidney injury in rats by its antioxidant and anti-inflammatory properties.

© 2018 Alexandria University Faculty of Medicine. Production and hosting by Elsevier B.V. This is an open access article under the CC BY-NC-ND license (<http://creativecommons.org/licenses/by-nc-nd/4.0/>).

## 1. Introduction

Chromium (Cr) is a heavy metal that has several valence states; the most common one is the hexavalent chromium (CrVI), that is widely used in industries, e.g. leather tanning, stainless steel manufacturing, chrome plating (chromates added as anticorrosive agents to paints, primers, and other surface coatings), welding and wood preservation.<sup>1,2</sup> CrVI can also be found in drinking water and in public water systems.<sup>3</sup> Environmental and/or occupational exposure to CrVI-containing compounds is known to be toxic and carcinogenic to human beings and animals.<sup>4</sup> A major adverse effect of chromium poisoning is nephrotoxicity due to chromium excretion through the kidney, this increases its chromium content and subsequently, nephropathy occurs.<sup>5</sup> The toxic manifestations of

chromium are considered to be due to oxidative stress,<sup>6,7</sup> leading to serious damage to the vital organs.<sup>8,9</sup>

Potassium dichromate is used to induce oxidative kidney damage.<sup>10</sup> Nephrotoxicity induced by PDC in rat mimics the occupational hazard.<sup>11</sup>

Eugenol (1-allyl-4-hydroxy-3-methoxybenzene, C<sub>10</sub>H<sub>12</sub>O<sub>2</sub>) is a naturally occurring substance, extracted from certain essential oils especially clove oil as well as nutmeg, cinnamon, and basil oils.<sup>12,13</sup> It has many pharmacological properties such as antioxidant, analgesic, anti-inflammatory, and antipyretic actions,<sup>12,14</sup> while it has been shown to ameliorate kidney injury in streptozotocin-induced diabetic rats,<sup>15</sup> and in gentamycin induced nephrotoxicity,<sup>16</sup> but its effect on PDC induced nephrotoxicity has not been investigated yet. So, this study aimed to assess the possible protective effect of eugenol, in a PDC induced acute kidney injury rat model.

Peer review under responsibility of Alexandria University Faculty of Medicine.

E-mail address: [ramez.barhoma@gmail.com](mailto:ramez.barhoma@gmail.com)

<https://doi.org/10.1016/j.ajme.2018.05.006>

2090-5068/© 2018 Alexandria University Faculty of Medicine. Production and hosting by Elsevier B.V.

This is an open access article under the CC BY-NC-ND license (<http://creativecommons.org/licenses/by-nc-nd/4.0/>).

## 2. Material and methods

### 2.1. Animals

This study was conducted on 30 male Wistar rats, weighing 200–220 g. purchased from the Experimental Animal House of Faculty of Science, Tanta University. The rats were kept in plastic cages (5 rats per cage) under controlled environmental conditions, 12/12 h light/dark cycle, at room temperature ( $23 \pm 2^\circ\text{C}$ ), with free access to water and food. All protocols were approved by the Tanta University ethical committee, (code approval number: 40118/08/29).

### 2.2. Chemicals

In this study, eugenol and PDC were purchased from Sigma-Aldrich (USA). They were diluted and dissolved in olive oil and saline (0.9%) respectively for administration.

### 2.3. Study design

Rats were divided into 3 groups, 10 rats per each group.

**Control group:** Rats were gavaged with olive oil (5 mL/kg body weight/day) for 10 consecutive days.

**PDC group:** Rats were daily gavaged with olive oil, like control group, then intoxicated in the tenth day with a single s.c. injection of PDC (15 mg/kg) freshly dissolved in saline.<sup>17</sup>

**Eugenol (Eu) + PDC group:** Rats received eugenol orally (100 mg/kg body weight/day) for 10 consecutive days,<sup>16</sup> and a single s.c. injection of PDC (15 mg/kg) in the tenth day.<sup>17</sup>

The doses of eugenol and PDC employed were the effective doses that used in previous researches.

Twenty-four hours after the last treatment, rats in all groups were anaesthetized with ketamine (75 mg/kg). Midline laparotomy was performed. Blood samples were taken from the abdominal aorta, then serum was separated by centrifugation (3000 rpm for 10 min) for the immediate analysis of urea and creatinine, and aliquot was then stored until further analysis.

Also the kidneys were immediately dissected out for histopathological evaluation, and biochemical analysis of renal tissue. Finally, the rats were sacrificed by decapitation under general anesthesia.

### 2.4. Estimation of renal function biomarkers

Serum urea and creatinine were determined colorimetric, according to Bauer et al.<sup>18</sup> method.

### 2.5. Estimation of renal tissue damage marker in serum

Serum lactate dehydrogenase (LDH) was estimated colorimetric, according to Sharma, and Datta<sup>19</sup> method.

### 2.6. Estimation of oxidative stress markers in kidney

Weighed parts from both kidneys were homogenized in ice-cold 0.1 M sodium phosphate buffer (pH 7.4) to prepare a 10% (w/v) tissue homogenate. The homogenate was centrifuged for 30 min at 4000 rpm at  $4^\circ\text{C}$ . The resultant supernatant was used to measure reduced glutathione (GSH), malondialdehyde (MDA) and superoxide dismutase (SOD), using GSH, MDA and SOD assay kits, according to the methods described by Akerboom and Sies,<sup>20</sup> Janero,<sup>21</sup> and Kuthan et al.<sup>22</sup> respectively.

### 2.7. Estimation of inflammatory biomarker in kidney

Tumor necrosis factor alpha (TNF- $\alpha$ ) was determined in the kidney using TNF- $\alpha$  ELISA kit (obtained from Sigma chemical Co.), according to Navarro et al.<sup>23</sup> method.

### 2.8. Histopathological analysis

Parts of kidneys from all groups were fixed in 10% buffered formalin for 72 h. at room temperature then washed under running water, dehydrated in ascending concentrations of ethanol, cleared in xylene and finally, embedded in paraffin. Then sections of 5  $\mu\text{m}$  thickness were stained with hematoxylin and eosin and evaluated by light microscopy.<sup>24</sup>

### 2.9. Statistical calculations

Collected data were statistically analyzed by one-way ANOVA, followed by Tukey test, to determine statistical significance between different groups using SPSS software package 23.0. Data was presented as mean  $\pm$  SD, and  $P < 0.05$  was considered statistically significant.

## 3. Results

### 3.1. Effect of eugenol on kidney function and serum LDH

A significant elevation in serum urea, creatinine and LDH levels was observed in PDC group compared with those of control group. Pretreatment with eugenol, significantly decreased their levels when compared with PDC group, but still significantly elevated when compared with those of control group (Fig. 1).

### 3.2. Effect of eugenol on kidney oxidative stress markers

Renal GSH and SOD levels were significantly reduced, while a significant elevation of renal MDA content was detected following PDC administration. Treatment of rats with eugenol, prior to PDC injection significantly elevated GSH and SOD levels, with normalization of SOD level, while GSH level still significantly lower than normal control values. Also, MDA level was significantly reduced after pretreatment with eugenol, and still significantly higher than normal control values (Fig. 2).

### 3.3. Effect of eugenol on renal inflammatory biomarker

PDC injection significantly increased renal TNF- $\alpha$  level, compared to the control group. The rats treated with eugenol showed a significant decrease in renal TNF- $\alpha$  level compared to the PDC group, but its level still significantly higher compared to the control group (Fig. 2).

### 3.4. Histopathological observations

The kidney sections from the rats of control groups showed normal histological structures with normal glomeruli and renal tubules (Fig. 3a), PDC caused histopathological alterations in the form of diffuse coagulative necrosis in most of the renal tubules, congestion of interstitial blood vessel, associated with fibroblastic proliferation and mononuclear cell infiltration (Fig. 3b, c). These alterations were markedly reduced in **Eu + PDC group** as renal tubules showed mild tubular damage and very mild inflammatory cell infiltrates in addition to few regenerative renal tubules (Fig. 3d).

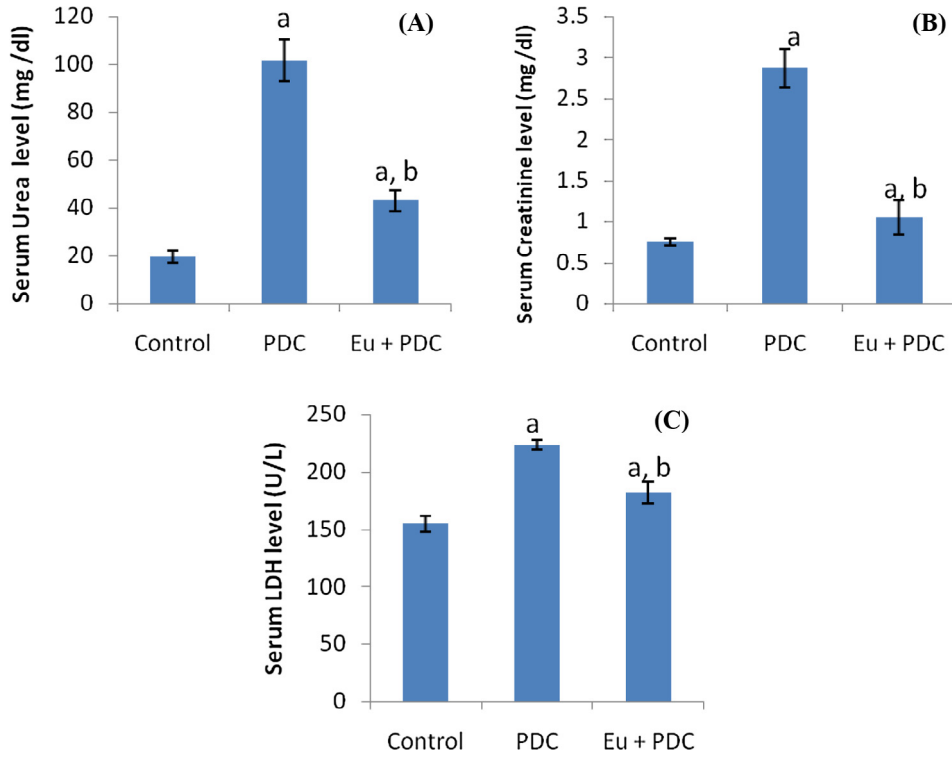


Fig. 1. Serum levels of urea (A), creatinine (B), and LDH (C) in all groups. <sup>a</sup>P < 0.05 vs group I. <sup>b</sup>P < 0.05 vs group II.

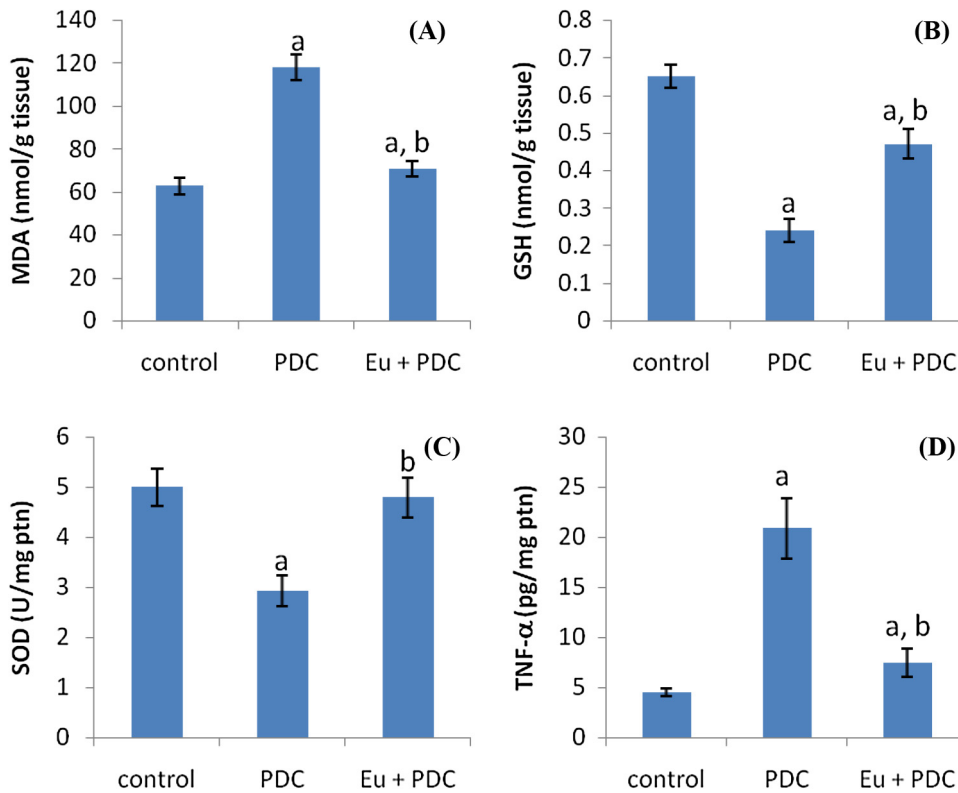
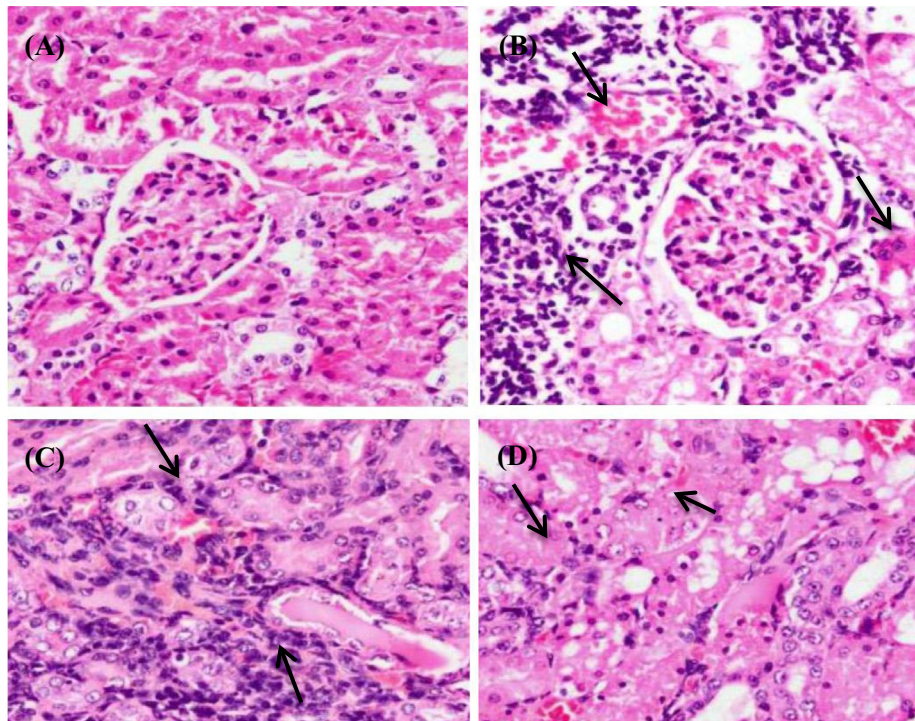


Fig. 2. Tissue levels of MDA (A), GSH (B), SOD (C), and TNF-α (D) in all groups. <sup>a</sup>P < 0.05 vs group I. <sup>b</sup>P < 0.05 vs group II.

#### 4. Discussion

Potassium dichromate was used to induce oxidative kidney damage.<sup>10</sup> The kidneys were considered to be the target organs

of systemically absorbed chromate, and nephrotoxicity could be the primary cause of death in cases of acute chrome exposure.<sup>5</sup> The massive reactive oxygen species production was considered to be the cause of toxic effect of PDC, and has been attributed to



**Fig. 3.** Kidney histopathology (X400). (A) Control group: normal histological structure of the glomeruli and tubules. (B) PDC group: congestion of interstitial blood vessel, diffuse coagulative necrosis in most of the renal tubules and mononuclear cell infiltration. (C) PDC group: fibroblastic proliferation and mononuclear cell infiltration (D) Eu + PDC group: focal necrosis of epithelial lining associated with uniformly arranged regenerative renal tubules.

the reduction of hexavalent chromium to trivalent one, which induces damage of cellular components.<sup>25</sup> The tubular damage and nephrotoxic effect of chromate resulted from its accumulation in vacuoles inside the cells of proximal convoluted tubules that lead to slow excretion and remaining of Cr in the kidney for a long time.<sup>26</sup>

In the present study, injection of a single dose of PDC, induced acute kidney injury in rats as evidenced by the significant alteration of the serum levels of urea, creatinine and LDH and confirmed with the severe changes in histopathology of PDC group, particularly tubular necrosis. These results are denoting the nephrotoxic effect of PDC, and are in accordance with those reported by Salama et al.,<sup>10</sup> Arreola-Mendoza et al.,<sup>27</sup> and Yam-Canul et al.<sup>28</sup>

This nephrotoxic effect of PDC could be attributed to the PDC induced oxidative stress, as evidenced by increased level of MDA and decreased levels GSH and SOD in the kidney tissues of PDC group. Another mechanism of nephrotoxic effect of PDC may be increased inflammatory process as evidenced by significant increase of the renal TNF- $\alpha$  level after PDC injection, and confirmed by histopathological findings especially, mononuclear cell infiltration, but this increased inflammatory process may be promoted by oxidative injury of the renal tissues itself.<sup>29</sup> These findings are in accordance with many other studies.<sup>10,27</sup> Also, Beaver et al.<sup>30</sup> reported induction of acute inflammatory reaction with neutrophils, macrophages, and lymphocytic cell infiltration induced by chromium.

In this study, pretreatment of rat with eugenol markedly protected the kidney against PDC-induced AKI and oxidative stress, as evidenced by the significant decrease in serum levels of urea, creatinine and LDH and improvement of histopathological changes occurred in PDC group as well as significant changes in renal contents of MDA, GSH and SOD. The anti-inflammatory effect of eugenol was confirmed by the significant decrease of TNF- $\alpha$  and by the histopathological findings that showed marked improvements of

renal tissues with mild degenerative changes in the epithelial lining of renal tubules with no evidence of interstitial inflammatory cell infiltrate in rats treated by eugenol.

The antioxidative potential of eugenol has been studied in a number of studies where it has been shown to bind to free oxygen radicals and attenuate the action of oxidative substances.<sup>16,31–33</sup>

Also, the anti-inflammatory effects of Eugenol has been described by Huss et al.,<sup>34</sup> it was also reported that eugenol acts as an anti-inflammatory substance<sup>35</sup> and reducing the release of proinflammatory mediators such as TNF- $\alpha$ , and PGE2.<sup>36,37</sup>

## 5. Conclusion

The present study confirmed that eugenol offers protection against PDC-induced AKI in rats by its direct antioxidant effect and by lowering the production of inflammatory mediators such as TNF- $\alpha$ .

## Conflict of interest

We have no conflict of interest to declare.

## Acknowledgments

The author would like to thank Dr. Eman El Saed, the assistant professor of pathology for her help in the histopathological part of this study.

## References

- Keane M, Siert A, Stone S, Chen BT. Profiling stainless steel welding processes to reduce fume emissions, hexavalent chromium emissions and operating costs in the workplace. *J Occup Environ Hyg.* 2016;13(1):1–8.
- Pesch B, Kendzia B, Hauptmann K, et al. Airborne exposure to inhalable hexavalent chromium in welders and other occupations: estimates from the German MEGA database. *Int J Hyg Environ Health.* 2015;218:500–506.

3. Xie Y, Holmgren S, Andrews DMK, Wolfe MS. Evaluating the impact of the U.S. national toxicology program: a case study on hexavalent chromium. *Environ Health Perspect*. 2017;125(2):181–188.
4. Mignini F, Tomassoni D, Traini E, et al. Immunological pattern alteration in shoe, hide, and leather industry workers exposed to hexavalent chromium. *Environ Toxicol*. 2009;24:594–602.
5. Hegazy R, Salama A, Mansour D, Hassan A. Renoprotective effect of lactoferrin against chromium-induced acute kidney injury in rats: involvement of IL-18 and IGF-1 inhibition. *PLoS ONE*. 2016;11(3):e0151486.
6. Jomova K, Valko M. Advances in metal-induced oxidative stress and human disease. *Toxicology*. 2011;283:65–87.
7. Stohs SJ, Bagchi D. Oxidative mechanisms in the toxicity of metal ions. *Free Radic Biol Med*. 1995;18:321–336.
8. Aruldas MM, Subramanian S, Sekar P, et al. Chronic chromium exposure-induced changes in testicular histoarchitecture are associated with oxidative stress: study in a non-human primate (*Macaca radiata* Geoffroy). *Hum Reprod*. 2005;20:2801–2813.
9. Nudler SI, Quinteros FA, Miler EA, Cabilla JP, Ronchetti SA, Duvilanski BH. Chromium VI administration induces oxidative stress in hypothalamus and anterior pituitary gland from male rats. *Toxicol Lett*. 2009;185:187–192.
10. Salama A, Elsayeh B, Ismael I, El-Shenawy S. Comparative evaluation of protective effects of green tea and lycopene in potassium dichromate-induced acute renal failure in rats. *J Chem Pharm Res*. 2014;6(12):168–177.
11. Zeng LN, Ma ZJ, Zhao YL, et al. The protective and toxic effects of rhubarb tannins and anthraquinones in treating hexavalent chromium-injured rats: the Yin/Yang actions of rhubarb. *J Hazard Mater*. 2013;246–247:1–9.
12. Pramod K, Ansari SH, Ali J. Eugenol: a natural compound with versatile pharmacological actions. *Nat Product Commun*. 2010;5(12):1999–2006.
13. Tiku AB, Abraham SK, Kale RK. Eugenol as an in vivo radioprotective agent. *J Radiat Res*. 2004;45:435–440.
14. Zhao X, Chen D, Gao P, Ding P, Li K. Synthesis of ibuprofen eugenol ester and its microemulsion formulation for parenteral delivery. *Chem Pharm Bull*. 2005;53:1246–1250.
15. Garud MS, Kulkarni YA. Eugenol ameliorates renal damage in streptozotocin-induced diabetic rats. *Flavour Fragr J*. 2017;32:54–62.
16. Said MM. The protective effect of eugenol against gentamicin-induced nephrotoxicity and oxidative damage in rat kidney. *Fund Clin Pharmacol*. 2011;25(6):708–716.
17. Khan MR, Siddiqui S, Parveen K, Javed S, Diwakar S, Siddiqui WA. Nephroprotective action of tocotrienol-rich fraction (TRF) from palm oil against potassium dichromate (K<sub>2</sub>Cr<sub>2</sub>O<sub>7</sub>)-induced acute renal injury in rats. *Chem Biol Interact*. 2010;186(2):228–238.
18. Bauer JH, Brooks CS, Burch RN. Renal function studies in man with advanced renal insufficiency. *Am J Kidney Dis*. 1982;11:30–35.
19. Sharma AK, Datta P. Spectrophotometric estimation of serum lactate dehydrogenase with semicarbazide in the reaction medium. *Clin Chim Acta*. 1971;32(1):134–136.
20. Akerboom TP, Sies H. Assay of glutathione, glutathione disulfide, and glutathione mixed disulfides in biological samples. *Methods Enzymol*. 1981;77:373–382.
21. Janero DR. Malondialdehyde and thiobarbituric acid-reactivity as diagnostic indices of lipid peroxidation and peroxidative tissue injury. *Free Rad Biol Med*. 1990;9:515–540.
22. Kuthan H, Haussmann HJ, Werringloer J. A spectrophotometric assay for superoxide dismutase activities in crude tissue fractions. *Biochem J*. 1986;237(1):175–180.
23. Navarro JF, Mora-Fernandez C. The role of TNF- $\alpha$  in diabetic nephropathy: pathogenic and therapeutic implications. *Cytokine Growth Factor Rev*. 2006;17:441–450.
24. Drury R, Wallington E. *Carleton's histology technique*. 4th ed. New York, Toronto: Oxford University Press; 1967. 432.
25. Flores A, Perez JM. Cytotoxicity, apoptosis, and in vitro DNA damage induced by potassium chromate. *Toxicol Appl Pharmacol*. 1999;161:75–81.
26. Pedraza-Chaverri J, Barrera D, Medina-Campos ON, et al. Time course study of oxidative and nitrosative stress and antioxidant enzymes in K<sub>2</sub>Cr<sub>2</sub>O<sub>7</sub>-induced nephrotoxicity. *BMC Nephrol*. 2005;6:4.
27. Arreola-Mendoza L, Reyes JL, Melendez E, et al.  $\alpha$ -Tocopherol protects against the renal damage caused by potassium dichromate. *Toxicology*. 2006;218:237–246.
28. Yam-Canul P, Chirino YI, Sanchez-Gonzalez DJ, et al. Nordihydroguaiaretic acid attenuates potassium dichromate-induced oxidative stress and nephrotoxicity. *Food Chem Toxicol*. 2008;46:1089–1096.
29. Homsí E, Andreazzi DD, Faria JB, Janino P. TNF- $\alpha$ -mediated cardiorenal injury after rhabdomyolysis in rats. *Am J Physiol Renal Physiol*. 2015;308(11):1259–1267.
30. Beaver LM, Stemmy EJ, Constant SL, et al. Lung injury, inflammation and Akt signaling following inhalation of particulate hexavalent chromium. *Toxicol Appl Pharmacol*. 2009;235:47–56.
31. Markakis C, Tsaroucha A, Papalois AE, et al. The role of eugenol in the prevention of acute pancreatitis-induced acute kidney injury: experimental study. *HPB Surg*. 2016;2016:3203147.
32. Criddle DN, Frota Madeira SV, De Moura RS. Endothelium-dependent and -independent vasodilator effects of eugenol in the rat mesenteric vascular bed. *J Pharm Pharmacol*. 2003;55(3):359–365.
33. Vidhya N, Devaraj SN. Antioxidant effect of eugenol in rat intestine. *Ind J Exp Biol*. 1999;37(12):1192–1195.
34. Huss U, Ringbom T, Perera P, Bohlin L, Vasänge M. Screening of ubiquitous plant constituents for COX-2 inhibition with a scintillation proximity based assay. *J Nat Prod*. 2002;65:1517–1521.
35. Lee YY, Hung SL, Pai SF, Lee YH, Yang SF. Eugenol suppressed the expression of lipopolysaccharide induced proinflammatory mediators in human macrophages. *J Endodontics*. 2007;33(6):698–702.
36. Sharma JN, Srivastava KC, Gan EK. Suppressive effects of eugenol and ginger oil on arthritic rats. *Pharmacology*. 1994;49(5):314–318.
37. Fujisawa S, Atsumi T, Kadoma Y, Sakagami H. Antioxidant and prooxidant action of eugenol-related compounds and their cytotoxicity. *Toxicology*. 2002;177(1):39–54.