

HOSTED BY



ELSEVIER

Contents lists available at ScienceDirect

# Alexandria Journal of Medicine

journal homepage: <http://www.elsevier.com/locate/ajme>

## Case Report

# Tracheotomy as a surgical access for removal of bullet in the trachea: A case report



Shankar Ramasundram<sup>a</sup>, Baharudin Abdullah<sup>a,\*</sup>, Sivakumar Kumarasamy<sup>b</sup>, Nurul Syamiza Shamsudin<sup>b</sup>

<sup>a</sup> Department of Otorhinolaryngology-Head & Neck Surgery, School of Medical Sciences, Universiti Sains Malaysia, 16150 Kubang Kerian, Kelantan, Malaysia

<sup>b</sup> Department of Otorhinolaryngology-Head & Neck Surgery, Hospital Tuanku Ja'afar, 74000 Seremban, Negeri Sembilan, Malaysia

## ARTICLE INFO

### Article history:

Received 8 February 2017

Accepted 21 May 2017

Available online 7 June 2017

### Keywords:

Gunshot injury

Bullet

Tracheotomy

## ABSTRACT

Gunshot tracheal injury with retained bullet fragment inside the trachea presents a challenge for removal. The treatment of the tracheal injury depends on the magnitude of the tracheal wound and the presence of injury to adjacent organs. The surgical removal may require both bronchoscopy and an open trachea exploration. We report a case of a gunshot injury to the trachea which requires a tracheotomy for a successful bullet removal.

© 2017 Alexandria University Faculty of Medicine. Production and hosting by Elsevier B.V. This is an open access article under the CC BY-NC-ND license (<http://creativecommons.org/licenses/by-nc-nd/4.0/>).

## 1. Introduction

Tracheal injury caused by gunshot is rare and can be associated with a wide range of injuries varying from trivial to death. The foreign body may travel through the soft tissues ending in unsuspected sites which may lead to diagnostic confusion and dilemmas in treatment.<sup>1</sup> In case this injury goes unidentified, the possible complications are lethal. Multiple complications arise due to this injury which includes development of airway strictures, as well as atelectasis, infection, and perforation.<sup>2</sup> As this is a rare occurrence, a standard procedure for the removal of foreign bodies within the airway in a trauma setting has yet to be established.<sup>2</sup>

## 2. Case report

A thirty five years old gentleman suffered from a penetrating neck injury by a fragment of spent bullet while in shooting training session. He was brought to the emergency room complaining of bleeding and mild discomfort from the anterior aspect of the neck. He denied any shortness of breath or voice change. There was also no history of loss of consciousness or retrograde amnesia in this gentleman. There was a small superficial wound measuring 0.2 cm × 0.4 cm over the anterior aspect of the neck. There was no active bleeding and no evidence of surgical emphysema. The trachea was palpable and centrally located. Flexible bronchoscope

revealed small foreign body embedded at the mucosa of posterior wall of trachea. No active bleeding was seen and the airway was patent. A contrast neck CT (Fig. 1) was performed and it revealed foreign body at cervical spine C6/C7 level on the posterior wall of trachea with subcutaneous and intermuscular emphysema around thyroid cartilage extending inferiorly to the sternoclavicular joint.

Rigid bronchoscopy was performed under general anesthesia. However, no foreign body was seen in the airway. Neck exploration was performed through the puncture wound. The wound was extended through the strap muscle and anterior wall of trachea. Injury over the posterior wall of trachea was also visible. However, no foreign body was visualized during the exploration. Tracheotomy was performed. Mucous secretion within the lumen sucked out carefully while looking for the foreign body. Initial inspection after a stoma was created on the trachea revealed no foreign body as well. However, palpation using a blunt probe felt grittiness along the posterior wall of trachea. Upon manipulation, a small piece of metal was seen projecting from the trachea. The metallic fragment was removed with forceps and tracheostomy tube was inserted. Inspection of the foreign body revealed metallic fragment of a bullet measuring around 0.8 cm in length (Fig. 2). He tolerated the procedure well and was nursed in general ward post operatively. Tracheostomy was decannulated on day 3 post surgery successfully and he was subsequently discharged.

## 3. Discussion

Penetrating laryngotracheal injuries are uncommon in general civilian population and more often seen in warfare.<sup>1</sup> Velocity of

Peer review under responsibility of Alexandria University Faculty of Medicine.

\* Corresponding author.

E-mail addresses: [baharudin@usm.my](mailto:baharudin@usm.my), [profbaha@gmail.com](mailto:profbaha@gmail.com) (B. Abdullah).

<http://dx.doi.org/10.1016/j.ajme.2017.05.007>

2090-5068/© 2017 Alexandria University Faculty of Medicine. Production and hosting by Elsevier B.V.

This is an open access article under the CC BY-NC-ND license (<http://creativecommons.org/licenses/by-nc-nd/4.0/>).

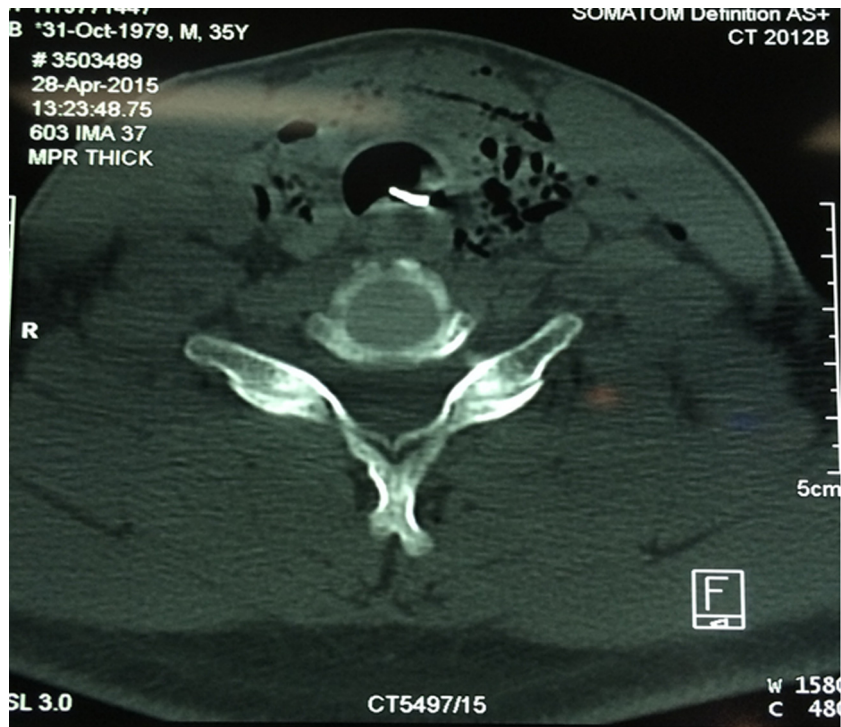


Fig. 1. Metallic foreign body seen projecting into tracheal lumen.

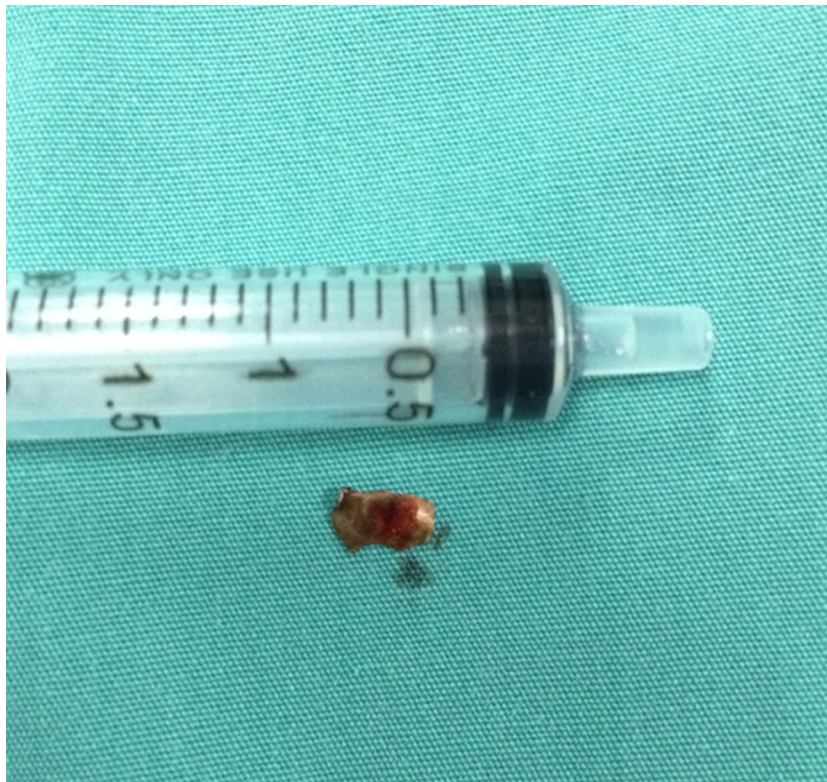

Fig. 2. Retained ballistic fragment removed from tracheal wall.

the explosion determines the depth of penetration and tissue damage. Assessment of the extent of damage based on the entry wound can be inaccurate. The foreign body may travel through the soft tissues ending in unsuspected sites, which may lead to diagnostic

confusion and dilemmas in treatment.<sup>1</sup> The urgency to identify and treat tracheal injuries is well documented; however a standardized technique for removal of foreign bodies during an emergency situation is not established. Patient may presents with signs

of airway compromise such as tachypnea, dyspnea, cyanosis, subcutaneous emphysema or an abnormal respiratory pattern.<sup>3</sup> However, the most common signs of airway injury are subcutaneous emphysema, pneumothorax and hemoptysis. A pathognomonic sign of airway laceration is air escaping from a penetrating wound in the neck.<sup>2</sup>

The use of CT scan can help in identifying the extent of damage and locating the foreign body and the type of material.<sup>4</sup> When the radiographic density of the foreign body is greater than the surrounding pulmonary parenchyma, CT scan may reveal the foreign body. Apart from that, diagnostic fiberoptic bronchoscopy may also be avoided.<sup>4</sup>

In a penetrating neck injury, the full potential course of the bullet should be carefully evaluated.<sup>5</sup> Though both the entry and exit point was seen on the trachea, the foreign body may not be visualized. Cases have been reported on retrieval of foreign body from tracheo-bronchial segments with the use of both rigid bronchoscopy and flexible fiberoptic bronchoscopy.<sup>1,2</sup> In case of a large foreign body or failure of endoscopic attempts of retrieval, tracheotomy should be considered.<sup>1</sup> Tracheotomy is also advised in large tracheal penetrating wound or when there is a severe distortion of the larynx making the intubation attempt extremely difficult. A thorough inspection should be performed within the lumen of trachea to avoid missing the foreign body as mucous plug or overlying mucosa can mask their visibility.

Our plan was to initially perform rigid bronchoscopy with neck exploration and removing the foreign body. However, during the bronchoscopy no foreign body was seen in the airway. As neck exploration revealed injury to the posterior wall of trachea, we proceeded with tracheotomy for this patient, to get a better view of tracheal lumen. Although the initial flexible bronchoscopy

demonstrated the foreign body, subsequent inspection of tracheal lumen and mucosa in the operation theater revealed no foreign body. There was a possibility of mucosal growth over the foreign body or migration of foreign body deeper into the posterior wall of trachea.

#### 4. Conclusions

Removal of foreign bodies from the airway is essential in order to avoid complications such as tracheal stenosis, pneumonia, bronchiectasis, and bullet migration. This case demonstrates the possibility of missing the foreign body within airway, especially when our view is limited and obscured.

#### Conflict of interest

All authors declared no conflict of interest.

#### References

1. Sayegh W, Golz A, Gordin A. Penetrating laryngotracheal injury in a child: an unusual case of firework fragment. *Int J Ped Otorhinolaryngol.* 2014;9:1–3.
2. Lax EA, Kiran SH, Lee MW. Bronchoscopic retrieval of a bullet using a Dormia basket: a case report. *J Med Case Rep.* 2014;8:358.
3. Kelly JP, Webb WR, Moulder PV, Everson C, Burch BH, Lindsey ES. Management of airway trauma I: tracheobronchial injuries. *Ann Thorac Surg.* 1985;40:551–555.
4. Bertolani MF. Extraction of a rubber bullet from a bronchus after 1 year: complete resolution of chronic pulmonary damage. *Chest.* 1999;115:1210–1213.
5. Smalls NM, Siram SM. The wandering bullet. *J Natl Med Assoc.* 1988;80:678–679.