



# Role of MRI in rectal carcinoma after chemo irradiation therapy with pathological correlation



Nehal Mohamed Elmashad <sup>a,\*</sup>, Manal Fathy Hamisa <sup>b</sup>,  
Dina Hazem Ziada <sup>c</sup>, Ola Nabih Abdel Fatah <sup>d</sup>, Waleed Arafat <sup>e</sup>

<sup>a</sup> Clinical Oncology Department, Tanta University, Egypt

<sup>b</sup> Radio Diagnosis and Medical Imaging Department, Tanta University, Egypt

<sup>c</sup> Tropical Medicine and infectious diseases Department, Tanta University, Egypt

<sup>d</sup> Clinical Oncology Department, Assiut University, Egypt

<sup>e</sup> University of Alexandria, Clinical Oncology Department, Egypt

Received 8 July 2014; accepted 1 November 2014

Available online 4 December 2014

## KEYWORDS

MRI;  
Rectal carcinoma;  
Chemo irradiation therapy

**Abstract** Rectal cancer is associated with a high risk of metastases and local recurrence; local recurrence rates after surgical treatment being up to 32% (1). Local recurrence is directly related to incomplete tumor resection (2, 3) and also related to the circumferential safety of resection (4, 5). An accurate local staging at the time of initial diagnosis is therefore very important.

**Aim:** The aim of this study is to use MRI in comparing the morphologic features of rectal cancer before and after 6 weeks of chemo irradiation treatment and to correlate the post treatment MRI appearances with the histological findings in resected tumors.

**Material and methods:** 68 patients with histopathologically proven rectal adenocarcinoma received standardized 5-week chemo radiation therapy and subjected to MRI before and after treatment for clinical staging. A correlation between pathological response and MRI findings was done.

**Result:** Sixty-eight patients with adenocarcinoma rectal cancer were included in the study. Preoperative MRI examination was performed. All patients subsequently underwent operation. The mean time lag between the MRI study and operation was 16.8 days.

After preoperative chemo-radiotherapy, MRI findings showed that, there is a significant shift toward downstaging. 16/59 (23.5%) patients achieved down-staging from clinical stage III (before therapy) to stage II after therapy ( $P = 0.001$ ) by achieving both tumor (T) downsizing and lymph node downstaging. MR images obtained after radiation therapy with concomitant chemotherapy have (100%) sensitivity, (78.7%) specificity, (100%) NPV in the differentiation of T1–2/T3–4 tumors with MRI, accuracy 80.9% with agreement 70.58% and 100% accuracy for node staging.

**Conclusion:** High resolution pre treatment MRI of the rectum has a high predictive value of treatment outcome either for neoadjuvant treatment or surgery.

© 2014 The Authors. Alexandria University Faculty of Medicine. Production and hosting by Elsevier B.V. This is an open access article under the CC BY-NC-ND license (<http://creativecommons.org/licenses/by-nc-nd/3.0/>).

\* Corresponding author.

E-mail address: [nehalelmashad@yahoo.com](mailto:nehalelmashad@yahoo.com) (N.M. Elmashad).

Peer review under responsibility of Alexandria University Faculty of Medicine.

<http://dx.doi.org/10.1016/j.ajme.2014.11.002>

2090-5068 © 2014 The Authors. Alexandria University Faculty of Medicine. Production and hosting by Elsevier B.V. This is an open access article under the CC BY-NC-ND license (<http://creativecommons.org/licenses/by-nc-nd/3.0/>).

## 1. Introduction

Rectal cancer is associated with a high risk of metastases and local recurrence; local recurrence rates after surgical treatment being up to 32%.<sup>1</sup> Local recurrence is directly related to incomplete tumor resection<sup>2,3</sup> and also related to the circumferential safety of resection.<sup>4,5</sup> An accurate local staging at the time of initial diagnosis is therefore very important. Tumor depth of invasion staging, especially local staging (referred to as T assessment), determines the treatment strategy. This includes operation planning and the use of neoadjuvant therapy.<sup>1</sup> The total mesorectal excision, gives the best chance for tumor-free circumferential resection margin, and this will reduce the local recurrence rate.<sup>4</sup> Preoperative chemoradiation therapy has become the standard adjunctive preoperative treatment of patients especially in patients where there is a high likelihood of not achieving free surgical margin.<sup>6</sup> MRI has been shown to be highly accurate for local staging. As it was less operator dependent, it enabled evaluation of anal infiltration as well as the depth of extramural invasion. It could also be used to predict the circumferential resection margin.<sup>7</sup> The tumor-free total mesorectal excision reduces the frequency of pathologically involved margin of resection by tumor. This benefit should lead to reduced rates of local tumor recurrence and lower patient morbidity.<sup>8</sup>

## 2. Materials and methods

This is a prospective study that includes 68 patients with biopsy-proven stage II or III rectal adenocarcinoma who received standardized 5-week chemo radiation therapy over a 2-year period (September 2010–December 2012). The indica-

tions for chemo radiation therapy were biopsy-proven locally advanced rectal cancer. In this regard, a locally advanced rectal cancer patient in our study was selected on the basis of either tumor fixation by digital rectal examination or clinical staging MRI findings of a high likelihood of circumferential resection margin involvement and hence possibility of inadequate immediate resection.

Of note, tumors were classified clinically as rectal if the lower limit was within 12 cm from the anal verge at sigmoidoscopy

- Informed consent was obtained from all patients after full explanation of the technique of MRI which is non invasive, without any risk approved till now.
- Privacy of all patients' data is guaranteed.

*Inclusion criteria:* T3, T4 N0–3 adenocarcinoma rectal cancer patients.

*Exclusion criteria:* Early T1–2 and/or distant metastatic rectal adenocarcinoma.

### 2.1. Pre treatment evaluation

#### 2.1.1. Clinical

Evaluation started with a complete history and accurate clinical examination including digital rectal examination and performance status (PS) of all patients according to ECOG PS scoring.

#### 2.1.2. Laboratory

Base line and before surgery complete blood count, liver and renal function tests, electrolytes, tumor marker Carcino-embryonic antigen (CEA) and CA19.9 level were performed.

**Table 1** Correlation between disease response after induction concomitant radio chemotherapy and patient characteristics.

		Response				Chi-square			
		Stable disease (SD)		Partial response (PR)		Total		$\chi^2$	P-value
		N	%	N	%	N	%		
Sex	Female	14	20.59	6	8.82	20	29.41	0.639	0.424
	Male	38	55.88	10	14.71	48	70.59		
Symptoms	Bleeding per rectum	51	75.00	14	20.59	65	95.59	2.651	2.651
	Alternation of bowel habits	1	1.47	2	2.94	3	4.41		
Signs	Bleeding per touch	37	54.41	13	19.12	50	73.53	4.145	0.126
	Mass detected clinically	13	19.12	1	1.47	14	20.59		
	Painful per touch	2	2.94	2	2.94	4	5.88		
Distance from anal verge	≤5 cm	23	33.82	8	11.76	31	45.59	0.164	0.686
	> 5 cm	29	42.65	8	11.76	37	54.41		
Operation Type	Low anterior resection	11	16.18	16	23.53	27	39.71	37.702	0.001**
	abdomino-perineal Resection + colostomy	41	60.29	0	0.00	41	60.29		
Margin	Both margins are free	48	70.59	14	20.59	62	91.18	0.327	0.567
	One or both margins are involved	4	5.88	2	2.94	6	8.82		
Grade	I	0	0.00	1	1.47	1	1.47	3.430	0.180
	II	41	60.29	13	19.12	54	79.41		
	III	11	16.18	2	2.94	13	19.12		
MRI morphology	Eccentric wall thickening	19	27.94	8	11.76	27	39.71	1.775	0.412
	Circumferential thickening	19	27.94	6	8.82	25	36.76		
	Polypoid growth	14	20.59	2	2.94	16	23.53		

### 2.1.3. Radiologically

- Abdomino-pelvic ultrasound of all patients.
- Chest X-ray and/or computed tomography (CT) if needed to exclude pulmonary metastasis of all patients.
- Abdominal CT with contrast to exclude liver metastasis.
- *Pelvic Magnetic Resonance Imaging (MRI)*: All cases underwent MRI examination in the Radio diagnosis Department (Tanta University) using a machine (GE signa 1.5 Tesla) with abdominal surface coil. All patients were positioned in the supine position. The following sequences are used, axial, sagittal and coronal T2WI. Axial cuts with fat saturated fast spin-echo T2WI and T1WI were obtained. Also axial, sagittal and coronal T1WI were taken immediately after a manual intravenous injection of 0.1 mg of Gd-DTPA/kg of body weight (Magnevist: Schering Berlin, Germany). Patients were asked to do breath-holding techniques to the extent tolerable.

### 2.1.4. Image analysis

MRI images were evaluated on a work station. Tumors were classified into two groups according to their anatomic location: low rectal tumors were diagnosed when less than 5 cm from the anal verge, upper and middle rectal tumors were diagnosed when more than 5 cm from the anal verge.

MR signal intensity of rectal mucosa and submucosa appear (inner hyperintense) followed by muscularis propria (appearing as hypointense intermediate layer). Then perirectal fat tissue (appearing as hyperintense layer), the mesorectal fascia appear as thin low intensity structure which envelops the mesorectum and the surrounding perirectal fat tissue. Also the extramesorectal lymph nodes were detected. The depth of the tumor invasion, the mesorectal infiltration, and number of enlarged lymph nodes were assessed. Mesorectal fascia was clearly delineated.

Each rectal tumor was staged according to the MRI findings and was later correlated with the operative and pathological findings. The depth of mural invasion by the tumor was staged according to the TNM staging system.<sup>9</sup>

We characterized T1 tumors by an infiltration of the submucosal layer and a sparing of the muscularis propria. When the tumor invades muscularis propria we accepted the tumor as T2. T2 lesions were differentiated from T3 lesions by identification of a smooth outer tumor border within the rectal wall with no invasion into the fat surrounding the rectum. T3 lesions had irregular outer borders and invaded the fat surrounding the rectum either by a plaque, mass, or cordlike signal intensity that projected into the perirectal fat. The presence of spiculation within the fat alone was not sufficient evidence of an extramural invasion. In T4 lesions, fat planes between the rectal carcinoma and surrounding organs disappeared. Mesorectal fascia involvement and the invasion into adjacent organs were also noted as indicators of T4 tumors. Mesorectal and extramesorectal lymph nodes with irregular margins and/or a short axis greater than 5 mm were accepted as metastatic.<sup>9</sup>

### 2.1.4. Treatment

Treatment is carried out in three Clinical Oncology centers: Tanta, Alexandria and Assiut. Radiation therapy for rectal cancer patients using Linear accelerator Photon 15 MeV

Varian Medical Systems, Palo Alto, CA (United States) and Siemens Primus (German) Serial No. 3301; Radiotherapy dose consisted of a total of 5040 cGy delivered in 28 fractions of 180 cGy, five times a week, to the pelvis with individually shaped portals and the use of a four-field box technique. Concomitant chemotherapy used oral capecitabine (Xeloda)<sup>®</sup> 825 mg/m<sup>2</sup> tablets twice daily throughout radiotherapy without interruption. Clinical and radiological restaging was performed 6 weeks after completion of preoperative treatment. Surgical resection either with anterior resection or abdomino-perineal resection was performed 6–8 weeks after completion of the chemo radiation therapy according to the principles of total mesorectal excision.

Patients were monitored for toxicity as radiation dermatitis, diarrhea and if needed were scored according to the National Cancer Institute Common Terminology Criteria for adverse Events (version 3.0).<sup>8</sup>

### 2.2. Ethical approval

Ethical and record linkage approvals were obtained from the Human Research Ethics Committee at the University of Tanta and the Confidentiality of Health Information Committee of Tanta and from Human Researches Ethics Committee at Assiut University.

**Table 2** Rectal tumor (T) down staging after induction radio-chemotherapy by MRI.

T pre MRI staging		T post MRI staging				
		T1	T2	T3	T4	Total
T2	N	2	12	0	0	14
	%	2.94	17.65	0.00	0.00	20.59
T3	N	0	34	3	2	39
	%	0.00	50.00	4.41	2.94	57.35
T4	N	0	0	10	5	15
	%	0.00	0.00	14.71	7.35	22.06
Total	N	2	46	13	7	68
	%		67.65	19.12	10.29	100.00
Wilcoxon signed ranks test Z		-6.351				
		P-value 0.001***				

**Table 3** MRI lymph node (N) down staging after induction radio-chemotherapy.

MRI node staging pre chemoradiotherapy		MRI node staging Post chemoradiotherapy			
		cNo	cN1	cN2	Total
cNo	N	9	0	0	9
	%	13.24	0.00	0.00	13.24
cN1	N	16	2	0	18
	%	23.53	2.94	0.00	26.47
cN2	N	0	10	31	41
	%	0.00	14.71	45.59	60.29
Total	N	25	12	31	68
	%	36.76	17.65	45.59	100.00
Wilcoxon signed ranks test Z		-5.099			
		P-value 0.001**			

cN = clinical radiological node.

3. Result

Sixty-eight adenocarcinoma rectal cancer patients were included in the study (M:F = 48:20). The commonest clinical

presentation was per-rectal bleeding (95.6%,  $n = 65$ ). Preoperative MRI examination was performed. No treatment interruption occurred as no major toxicity occurred. All patients subsequently underwent operation. The mean time lag between the MRI study and operation was 16.8 days. 27 (39.71%) patients achieved a statistically significant partial response to concomitant radio chemotherapy and underwent low anterior resection and 41 (60.29%) patients abdomino-perineal resection + colostomy ( $P$  value 0.001\*\*) (Table 1).

**Table 4** Rectal cancer downstaging after induction radio-chemotherapy by MRI.

MRI stage before therapy		MRI stage after therapy		
		Stage II	Stage III	Total
Stage II	<i>N</i>	9	0	9
	%	13.24	0.00	13.24
Stage III	<i>N</i>	16	43	59
	%	23.53	63.24	86.76
Total	<i>N</i>	25	43	68
	%	36.76	63.24	100.00
Wilcoxon signed ranks test	<i>Z</i>	-4.000		
	<i>P</i> -value	0.001**		

3.1. MRI down staging after induction radio-chemotherapy

After preoperative chemo-radiotherapy, there is a significant shift toward downstaging. 16/59 (23.5%) patients achieved down-staging by tumor (T) downsizing (Table 2) and lymph node (N) downsizing (Table 3) and from clinical stage III (before therapy) to stage II after therapy ( $P = 0.001$ )\*\* (Table 4) by achieving both.

**Table 5** Correlation between histo-pathological and post chemo-radiotherapy MRI findings for rectal tumor (T) staging.

Pathological T staging		Post chemo-radiotherapy MRI staging (T staging)				
		T1	T2	T3	T4	Total
T1	<i>N</i>	2	0	0	0	2
	%	100.00	0.00	0.00	0.00	100.00
T2	<i>N</i>	0	46	13	0	59
	%	0.00	77.97	22.03	0.00	100.00
T3	<i>N</i>	0	0	0	7	7
	%	0.00	0.00	0.00	100.00	100.00
Total	<i>N</i>	2	46	13	7	68
	%	2.94	67.65	19.12	10.29	100.00
Wilcoxon signed ranks test	<i>Z</i>	-4.472				
	<i>P</i> -value	0.001**				
		Agreement				
		70.58%				
		Sensitivity	Specificity	PPV	NPV	Accuracy
		100%	78.7%	35%	100%	80.9%

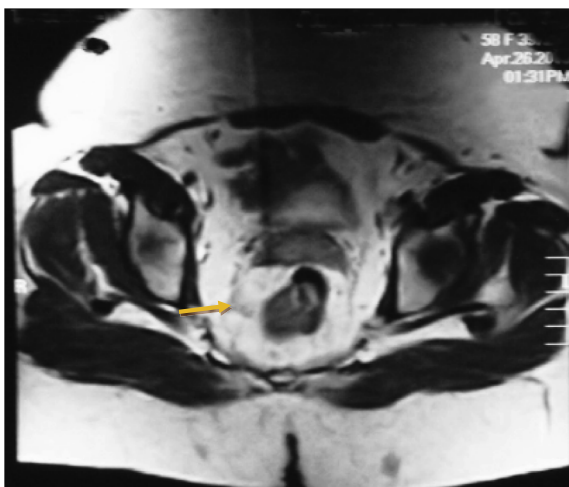
PPV = positive predictive value; NPV = negative predictive value.

**Table 6** Correlation between histo-pathological and post chemo-radiotherapy MRI findings for LN (N) staging.

Histo-pathological N staging		Post chemo-radiotherapy MRI staging (N staging)				
		cNo	cN1	cN2	Total	
ypNo	<i>N</i>	25	0	0	25	
	%	100.00	0.00	0.00	100.00	
ypN1	<i>N</i>	0	12	20	32	
	%	0.00	37.50	62.50	100.00	
ypN2	<i>N</i>	0	0	11	11	
	%	0.00	0.00	100.00	100.00	
Total	<i>N</i>	25	12	31	68	
	%	36.76	17.65	45.59	100.00	
Wilcoxon signed ranks test	<i>Z</i>	-4.472				
	<i>P</i> -value	0.001**				
		Agreement				
		70.58%				
		Sensitivity	Specificity	PPV	NPV	Accuracy
		100%	100%	100%	100%	100%

ypN = pathological node.



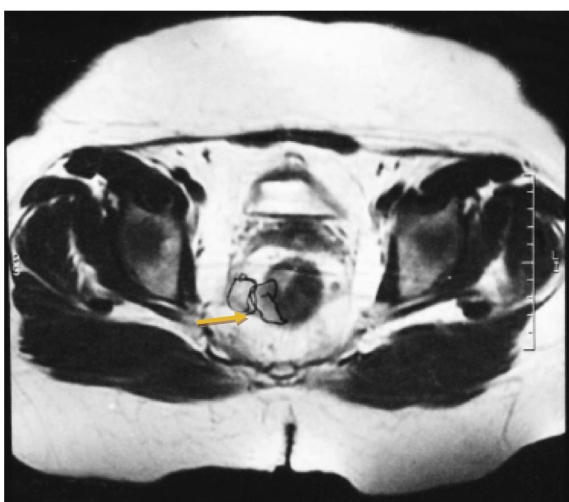


**Figure 1** Axial T2 MR cuts showing soft tissue mass of intermediate to high T2 signal intensity (S1) on the antero-lateral aspect of the lower rectum 9 O'clock (arrow) with loss of the muscularis propria and early infiltration of the adjacent mesorectal fat represent early T3.

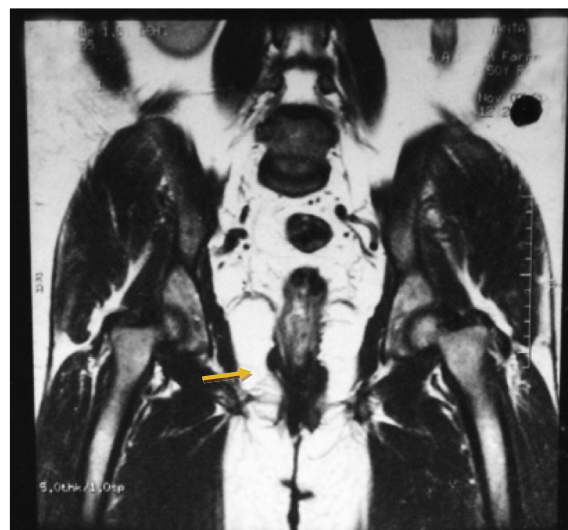The accuracy of pre-operative MRI versus pathological staging after either low anterior resection or abdomino-perineal resection:

Using Wilcoxon signed ranks test, there is a significantly strong correlation between histopathological and post MR images obtained after radiation therapy with concomitant chemotherapy in the differentiation of T2/T3 tumors ( $z = -4.472$ ;  $P = 0.001^{**}$ ).

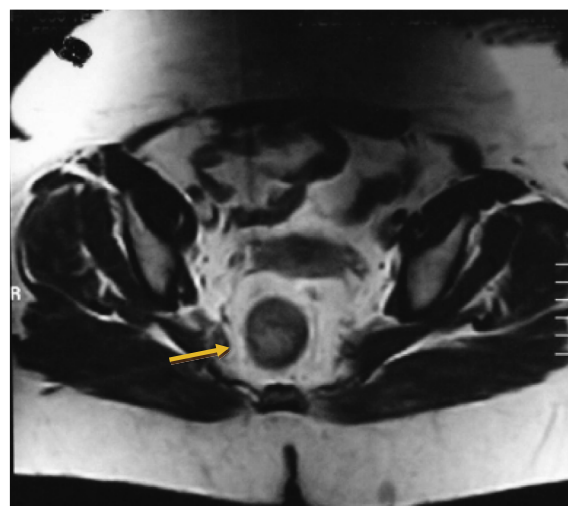
When compared with pathological findings after surgical manipulation, MRI achieved 100% sensitivity, 78.7% specificity, 100% NPV, 80.9% accuracy with an agreement of 70.58% for rectal tumor (Table 5). MRI showed 100% accuracy for detection of node staging (Table 6).



**Figure 2** Axial T2 MR cuts showing soft tissue mass of intermediate to high T2 signal intensity (S1) on the antero-lateral aspect of lower rectum 6-9 O'clock (arrow) with loss of the muscularis propria and early infiltration of the adjacent mesorectal fat represent early T3.



**Figure 3** Coronal T2 MRI showing right lower third rectal mass about 2 cm from levator ani/puborectalis insertion (arrow).



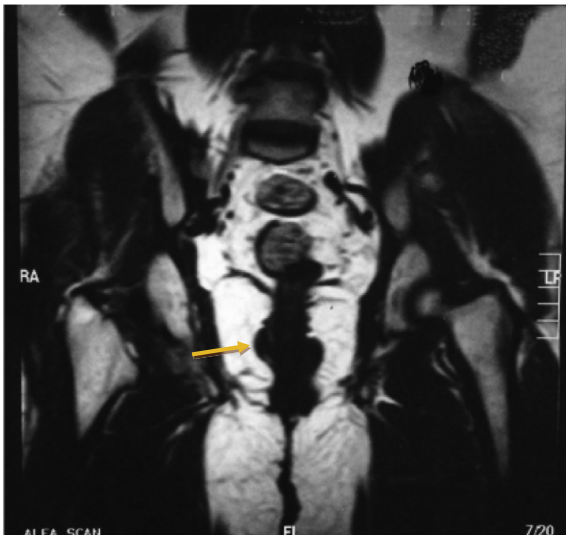
**Figure 4** Axial MR sequence showing T1 soft tissue mass in the posterior right lateral rectal wall (arrow) with clear invasion into mesorectal fat.

### 3.1.1. Case number 1

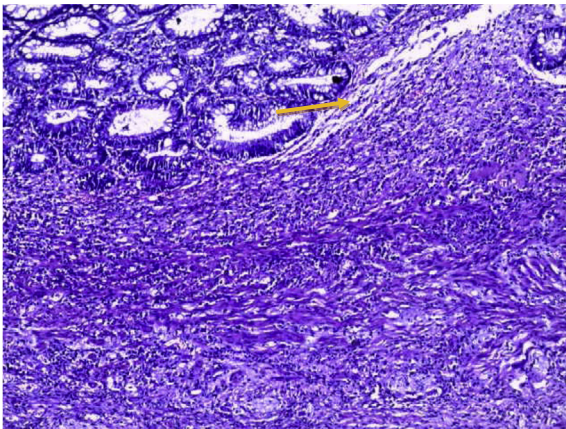
Female patient 60 years old presented by bleeding per rectum 2 months, Pre chemo-irradiation MRI (Figs. 1-3) show antero-lateral aspect of lower rectum 6-9 O'clock rectal adenocarcinoma with loss of the muscularis propria and early infiltration of the adjacent mesorectal fat. Post therapy MRI shows regression course of rectal adenocarcinoma with down staging of early T3 → T1 (Figs. 4 and 5) which correlates with post operative low anterior resection of pathological finding of the complete response (Fig. 6) with no evidence of adenocarcinoma (100% accuracy).

### 3.1.2. Case number 2

A male patient 38 years old presented with bleeding per rectum for 6 months. With alternation of bowel habits rectal adenocarcinoma is proved by punch biopsy before starting



**Figure 5** Coronal T2 MRI showing right lower third rectal mass 1 cm from levator ani puborectalis insertion (arrow).



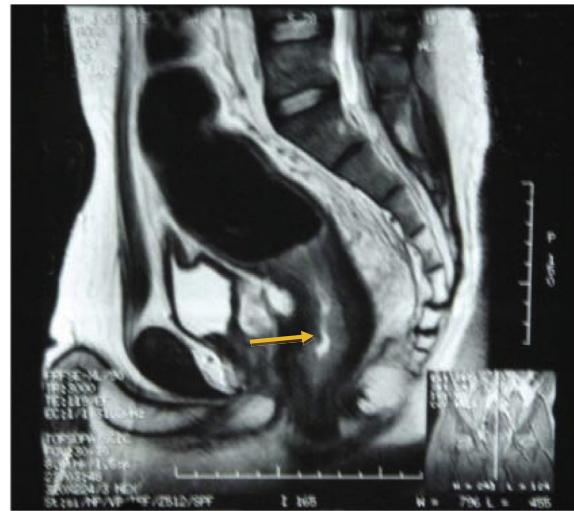**Figure 6** Histo pathological examination showing chronic non specific chemoradiotherapy induced proctitis showing transmurial lymphoplasmacytic inflammatory infiltrate, glandular architectural atypia but with preserved mucin production (arrow). No granuloma & no malignancy include H&E X100 (100% agreement).

concurrent chemo-radiotherapy. Pre chemo-irradiation MRI shows circumferential wall thickening mainly at the ano-rectal junction and narrowing of the lumen T3 (Fig. 7).

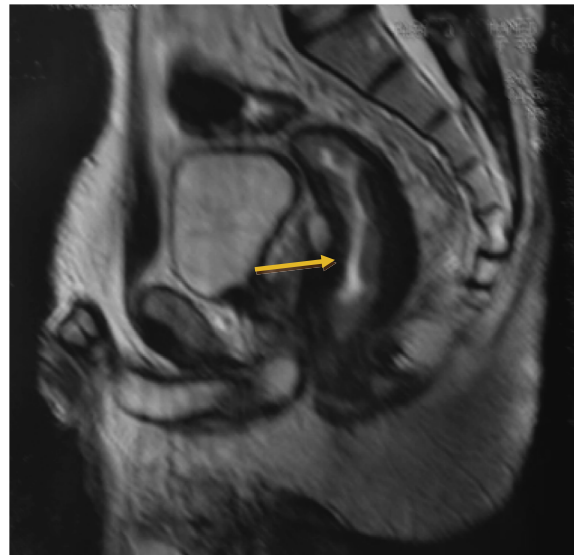
Post chemo-irradiation MRI shows stationary course of T3 rectal adenocarcinoma (Figs. 8 and 9) which correlates with post operative abdomino-perineal resection pathological finding (Fig. 10) of no response with evidence of adenocarcinoma (100% accuracy).

#### 4. Discussion

There are different modalities for diagnosis of rectal tumors including barium enema, and either colonoscopy or sigmoidoscopy. However these endoluminal techniques do not provide significant information about the extraluminal spread of the tumor needed for preoperative planning. Now several imaging



**Figure 7** Pre-therapeutic sagittal T2 MRI sequence show circumferential wall thickening mainly at the ano-rectal junction, narrowing the lumen.



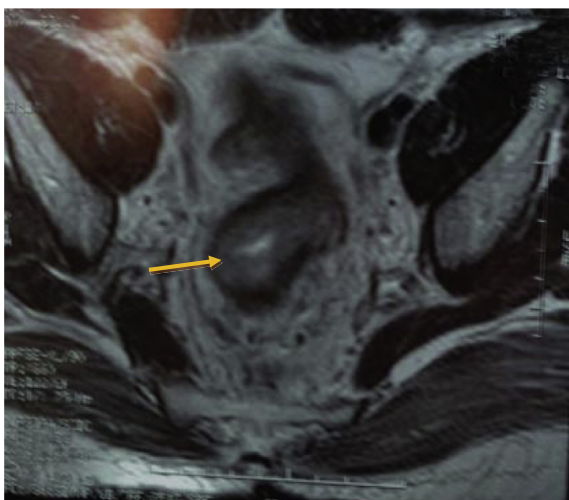
**Figure 8** Post therapeutic sagittal T2 MRI examination of the ano-rectal junction showing slight regressive course of the previously detected mass (arrow).

methods have been used to assess the accurate spread of the tumor, such as endorectal ultrasound (EUS), computed tomography (CT) and MRI.<sup>10</sup>

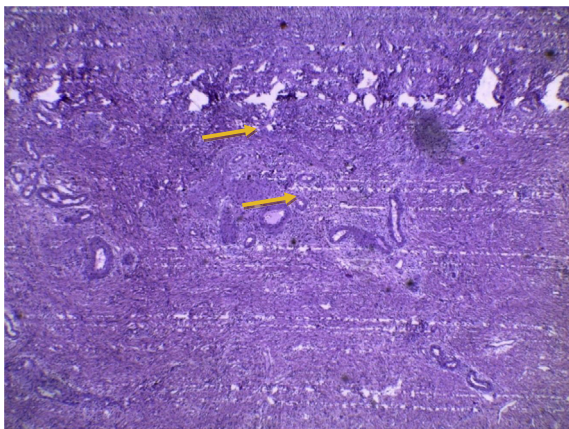
Many studies have reported that MRI shows excellent overall accuracies in the diagnosis of mesorectal fascia spread and invasion into adjacent organs (88–100% and 100%, respectively).<sup>11–13</sup> However this high accuracy rate was not achieved either by EUS or multi detector CT.<sup>14</sup> Differentiation between T3 from T2 lesions is very important mainly for preoperative therapy, and the most important criterion is the invasion into perirectal fat. Early criteria for an assignment of pT3 in MRI are the absence of hypointensity of the muscle layer seen between the edge of the tumor and the extramural soft tissue.<sup>15</sup>

Infiltration of tumor to the perirectal fat is the best indicator of T3 tumor on MRI images. However it is difficult to





**Figure 9** Axial T2 MRI sequence examination revealing also the slight regression of the circumferential thickening seen at recto-anal junction (arrow).



**Figure 10** Histo pathological examination after chemo radiotherapy showing residual of malignancy (arrow) H&E X100 with 100% post therapy MRI agreement.

differentiate spiculation seen in the perirectal fat caused only by fibrosis from that spiculation caused by fibrosis containing tumor cells.<sup>16</sup>

The mesorectal fascia that represents the CRM, and hence invasion into the CRM has a high recurrence rate.<sup>17</sup> In our work, neoadjuvant chemo-radiotherapy leads to down staging of the tumor in terms of its T and N stages as we investigated the MR accuracy obtained after radiation therapy with concomitant chemotherapy for the prediction of down staging of tumors confined to the rectal wall T3–4/T1–2 by using histopathologic findings (ypT3/T1–2 lesions) as the reference standard in patients with cancerous rectum. After preoperative chemo radiotherapy there is a significant shift toward earlier TNM stages with significant down-staging from stage III before therapy to stage II after therapy ( $P$  value = 0.001). MR images obtained after concomitant chemo-irradiation have 100% sensitivity, 78.7% specificity, 100% NPV for the prediction of

tumor downsizing to a ypT0–2 lesion with accuracy 80.9%. This result agrees with that of Williamson<sup>18</sup> and Chari.<sup>19</sup>

In our study MRI shows 100% accuracy in the differentiation of N0/N1–2 tumors ( $z = -4.472$ ;  $P = 0.001$ ) with sensitivity 100%, specificity 100% (Table 6) with agreement 70.58%. This concurs with Beets-Tan and colleagues who investigated 76 patients and found preoperative MRI to be accurate in the assessment of CRM. The agreement is 100% in T4 tumors, and 97% and 93% for both readers in tumors with a histologically determined tumor-free CRM > 10 mm.<sup>10,11</sup> The low accuracy of MR imaging in these studies could be explained by the low spatial resolution that was used with early MRI techniques in 2001. But even with higher spatial resolutions in the new generation of phased-array coils, the accuracy for T staging was not as high as expected, with values varying between 65% and 86%.<sup>11,20–22</sup>

One exception to the above was the study done by Brown and colleagues<sup>6</sup> who reported 100% accuracy and complete agreement between two readers on the diagnosis of tumor stage with MR imaging results. The most difficult staging with MR imaging occurs in the differentiation of T2-stage and borderline T3-stage lesions. This is mainly due to the over-staging of the tumor. Over-staging is caused mainly by desmoplastic reactions.<sup>6,11,22</sup> In our work there is strong correlation between histopathological and post MRI tumor staging in the differentiation of T2/T3 ( $Z = 472$ ;  $P = 0.001$ ) and also in the differentiation of N1/N2 ( $Z = 472$ ;  $P = 0.001$ ). This is in concordance with Minsky and others in 1995 as MRI and histology for T staging have ranged from 66% to 94%. The main difficulty with MRI has been the differentiation between two stages T2 and T3. However, the definitive treatment being the same for both these stages, this means the differentiation does not play a huge impact on patient outcome.<sup>23</sup>

On the other hand, in a study Bissett and his colleague reported good agreement between preoperative MRI and histopathology as regards tumor invasion detection through the mesorectal fascia with an high accuracy of 95%.<sup>24</sup> The exact staging is very important because the number of metastatic nodes has been shown to affect the prognosis of the disease.<sup>25</sup> Lymph node involvement in the vicinity of the mesorectal fascia is associated with a higher risk of local recurrence,<sup>2</sup> and therefore the accuracy in the detection of lymph nodes is essential for accurate treatment. Patients with metastatic lymph nodes outside the mesorectal fascia need extended lymph node resection with removal of the internal iliac lymph nodes.<sup>11</sup> This group of lymph node is not removed when TME is done.

Nodal staging by MRI usually depends on the size criteria. Typically a lymph node is considered malignant when the short axis of the lymph node measures over 0.5 cm.<sup>26</sup> Also the lymph node features such as ill defined edges, dissimilarity of signal enhancement within the node increase the accuracy of MRI.<sup>27</sup> This can explain achieving 100% accuracy in our study. The disappointing accuracy seen in MRI imaging in staging rectal cancer is due to both over-staging and under-staging. Over staging, in the assessment of invasion into the rectal wall, occurs because after radiotherapy the responding tumors are replaced by fibrosis, inflammatory and vascular proliferation.<sup>28</sup> Promising strategies of imaging using lymph node specific paramagnetic nano particles have been reported to increase the accuracy in the detection of micro metastasis.<sup>29</sup>

## 5. Conclusion

MRI plays an important role in the multimodality imaging used in the treatment of patients with cancerous rectum. Accurate preoperative staging is very important for making effective therapeutic decisions. MRI accurately delineates the extent of primary tumor. Regarding the depth of tumor invasion these give effective decisions for patient treatment.

## Conflict of interest

None declared.

## References

- Sagar PM, Pemberton JH. Surgical management of locally recurrent rectal cancer. *Br J Surg* 1996;**83**:293–304.
- Adam IJ, Mohamdee MO, Martin IG, et al. Role of circumferential margin involvement in the local recurrence of rectal cancer. *Lancet* 1994;**344**:707–11.
- Quirke P, Durdey P, Dixon MF, Williams NS. Local recurrence of rectal adenocarcinoma due to inadequate surgical resection: histopathological study of lateral tumor spread and surgical excision. *Lancet* 1986;**2**:996–9.
- Heald RJ, Ryall RDH. Recurrence and survival after total mesorectal excision for rectal cancer. *Lancet* 1986;**1**:1479–82.
- Reynolds JV, Joyce WP, Dolan J, Sheahan K, Hyland JM. Pathological evidence in support of total mesorectal excision in the management of rectal cancer. *Br J Surg* 1996;**83**:1112–5.
- Brown G, Richards CJ, Newcombe RG, et al. Rectal carcinoma: thin-section MR imaging for staging in 28 patients. *Radiology* 1999;**211**:215–22.
- MERCURY Study Group. Extramural depth of tumor invasion at thin-section MR in patients with rectal cancer: results of the MERCURY study. *Radiology* 2007;**243**:132–9.
- Trotti A et al. Development of comprehensive grading system for the adverse effects of cancer treatment. *Semin Radiat Oncol* 2003 July;**13**(3):176–81.
- Sobin L, Wittekind C. *TNM classification of malignant tumors*. 5th ed. New York, NY: Wiley; 1997, 227.
- Beets-Tan RG, Beets GL. Rectal cancer: review with emphasis on MR imaging. *Radiology* 2004;**232**:335–46.
- Beets-Tan RG, Beets GL, Vliegen RF, et al. Accuracy of magnetic resonance imaging in prediction of tumour-free resection margin in rectal cancer surgery. *Lancet* 2001;**357**:497–504.
- Brown G, Radcliffe AG, Newcombe RG. Preoperative assessment of prognostic factors in rectal cancer using high-resolution magnetic resonance imaging. *Br J Surg* 2003;**90**:355–64.
- Akasu T, Iinuma G, Takawa M, et al. Accuracy of high-resolution magnetic resonance imaging in preoperative staging of rectal cancer. *Ann Surg Oncol* 2009;**16**:2787–94.
- Bipat S, Glas AS, Slors FJ, et al. Rectal cancer: local staging and assessment of lymph node involvement with endoluminal US, CT, and MR imaging a meta-analysis. *Radiology* 2004;**232**:773–83.
- Rao SX, Zeng MS, Xu JM, et al. Assessment of T staging and mesorectal fascia status using high-resolution MRI in rectal cancer with rectal distention. *World J Gastroenterol* 2007;**13**:4141–6.
- Brown G, Richards CJ, Newcombe RG, et al. Rectal carcinoma: thin-section MR imaging for staging in 28 patients. *Radiology* 1999;**211**:215–22.
- Brown G, Davies S, Williams GT, et al. Effectiveness of preoperative staging in rectal cancer: digital rectal examination, endoluminal ultrasound or magnetic resonance imaging? *Br J Cancer* 2004;**91**:23–9.
- Williamson PR, Hellinger MD, Larach SW, Ferrara A. Endorectal ultrasound of T3 and T4 rectal cancers after preoperative chemoradiation. *Dis Colon Rectum* 1996;**39**(1):45–9.
- Chari RS, Tyler DS, Anscher MS, et al. Preoperative radiation and chemotherapy in the treatment of adenocarcinoma of the rectum. *Ann Surg* 1995;**221**(6):778–86 discussion 786–777.
- Blomqvist L, Machado M, Rubio C, et al. Rectal tumor staging: MR imaging using phased-array and endorectal coils vs endoscopic ultrasonography. *Eur Radiol* 2000;**10**:653–60.
- Gagliardi G, Bayar S, Smith R, Salem RR. Preoperative staging of rectal cancer using magnetic resonance imaging with external phase-arrayed coils. *Arch Surg* 2002;**137**:447–51.
- Vogl TJ, Pegios W, Mack MG, et al. Accuracy of staging rectal tumors with contrast-enhanced transrectal MR imaging. *AJR Am J Roentgenol* 1997;**168**:1427–34.
- Minsky BD. Conservative treatment of rectal cancer with local excision and postoperative radiation therapy. *Eur J Cancer* 1995;**31A**(7–8):1343–6.
- Bissett IP, Fernando CC, Hough DM, et al. Identification of the fascia propria by magnetic resonance imaging and its relevance to preoperative assessment of rectal cancer. *Dis Colon Rectum* 2001;**44**(2):259–65.
- Tang R, Wang JY, Chen JS, et al. Survival impact of lymph node metastasis in TNM stage III carcinoma of the colon and rectum. *J Am Coll Surg* 1995;**180**(6):705–12.
- Beynon J, Mortensen NJ, Foy DM, Channer JL, Rigby H, Virjee J. Preoperative assessment of mesorectal lymph node involvement in rectal cancer. *Br J Surg* 1989;**76**:276–9.
- Kim DJ, Kim JH, Ryu YH, Jeon TJ, Yu JS, Chung JJ. Nodal staging of rectal cancer: high-resolution pelvic MRI versus 18F-FDG PET/CT. *J Comput Assist Tomogr* 2011;**35**:531–4.
- Kim DJ, Kim JH, Lim JS, Yu JS, Chung JJ, Kim MJ, et al. Restaging of rectal cancer with MR imaging after concurrent chemotherapy and radiation therapy. *Radiographics* 2010;**30**:503–16.
- Will O, Purkayastha S, Chan C, Athanasiou T, Darzi AW, Gedroyc W, et al. Diagnostic precision of nanoparticle enhanced MRI for lymph-node metastases: a meta-analysis. *Lancet Oncol* 2006;**7**:52–60.