



Alexandria University Faculty of Medicine
Alexandria Journal of Medicine

<http://www.elsevier.com/locate/ajme>



ORIGINAL ARTICLE

The clinical outcome of lateral mass fixation after decompressive laminectomy in cervical spondylotic myelopathy



Ahmed Yehya

Department of Neurosurgery, Faculty of Medicine, Alexandria University, Egypt

Received 6 May 2014; accepted 26 August 2014

Available online 11 October 2014

KEYWORDS

Lateral mass fixation;
Subaxial cervical spine;
Screw fixation

Abstract Lateral mass cervical fixation is the technique of choice for posterior cervical stabilization of the lower cervical spine in the cases of cervical spondylotic myelopathy. It is used for patients who had extensive, multiple-level laminectomies with reversed cervical lordosis.

Objective: The aim of this study was to evaluate the outcome of decompressive laminectomy of cervical spondylotic myelopathy with lateral mass fixation compared with decompressive laminectomy only without fixation.

Patients and methods: The study was conducted on 32 patients operated for cervical decompressive laminectomy with lateral mass fixation using polyaxial screws and rods at different levels of the subaxial cervical spine named group I, compared with 30 patients operated for cervical decompressive laminectomy only without lateral mass fixation named group II.

Results: Group I comprised 22 males (68.8%) and 10 females (31.2%), the age ranged from 36 to 63 years. Group II comprised 18 males (60%) and 12 females (40%), the age ranged from 40 to 66 years with a mean of 51 ± 7.73 . In group I, the mean operative time was 110 ± 14.16 min, the mean hospital stay was 4 ± 1.76 days and the mean blood loss was 480 ± 193.04 ml. In group II, the mean operative time was 75 ± 24.38 min, the mean hospital stay was 3 ± 1.57 days, and the mean blood loss was 220 ± 111.22 ml. There was a clinically significant difference as regards neck pain and brachialgia. In group I, neck pain improved in 68.8% and brachialgia improved in 83.3% but in group II, neck pain improved in 46.7% and brachialgia improved in 61.5%. Myelopathy and sphincteric disturbance showed clinical improvement but without clinically significant difference of both groups.

Conclusions: Lateral mass fixation of the cervical spine after cervical laminectomy is safe and reliable with few complications. It also improves neck pain and brachialgia.

© 2014 Alexandria University Faculty of Medicine. Production and hosting by Elsevier B.V. All rights reserved.

E-mail address: ahmedyehyamd@yahoo.com

Peer review under responsibility of Alexandria University Faculty of Medicine.

<http://dx.doi.org/10.1016/j.ajme.2014.08.004>

2090-5068 © 2014 Alexandria University Faculty of Medicine. Production and hosting by Elsevier B.V. All rights reserved.

1. Introduction

Lateral mass cervical fixation is the technique of choice for posterior cervical stabilization for treating instability of the lower cervical spine after extensive multiple-level cervical laminectomies with reversed lordosis.^{2,14} It is safe and reliable, but it is difficult to be used in patients with abnormal cervical anatomy as it may lead to injury of the spinal nerves or the vertebral arteries during the insertion of lateral mass screws.^{2,22} Roy-Camille was the first to insert screws into the lateral mass of the cervical spine in 1964 in France followed by Louis and Magerl in Switzerland.^{15,17}

There are many different techniques of posterior cervical fixation as posterior wiring,³ Halifax clamps,¹ posterior plate and screws,⁹ and finally fixation using polyaxial screws and rods.^{2,3} Wiring is rarely used as it is used only if the lamina and spinous process of the posterior element of the subaxial spine are intact and it could not be used in cases where laminectomies have been required for the decompression or exposure of target lesions.^{3,12} The main disadvantage of wiring is that it provides less fixation strength in comparison with other rigid instrumentations.³ Halifax clamps may provide better fixation strength than wiring but are still not optimal.¹ Lateral mass screws with plate fixation require precise contour tailoring for each patient and are thus extremely difficult for practical application.⁹ Recently, the technique of using polyaxial screws in conjunction with rod systems for the fixation of the lateral mass was greatly increased as it can avoid the above-mentioned disadvantages.^{16–19}

2. Patients and methods

The study was conducted on 2 groups. 32 patients operated for cervical decompressive laminectomy with lateral mass fixation using the modified Magerl technique at various levels from C3 to C7 according to the patient's requirements named group I, compared with another 30 patients operated for cervical decompressive laminectomy only without lateral mass fixation named group II. All the patients were operated in the Neurosurgery Department of the Main Alexandria University Hospital and the classification of the patients into group I and group II was random and the 2 groups were nearly the same as regards the clinical presentations, the cord signal, and the number of levels affected. Informed consent was obtained from all the patients before study.

All the patients were operated in prone position with the head slightly flexed. Posterior midline approach was done followed by dissection of the paravertebral muscles with exposure of the lamina extending from C1 to C7. In group I the dissection extended laterally till full exposure of the lateral mass and facets. The lateral border of each lateral mass was dissected which is a very important step for placing of the screws. The screws were placed into lateral mass of the affected levels of the subaxial cervical spine before laminectomies so that the bony landmarks can be used for better orientation. The entry point of the screw was identified 2 mm inferior and 2 mm medial to the center of the lateral mass using a high speed drill with a trajectory 30 mm lateral and 30–45 mm superior more or less parallel to the spinous process. The spinous processes should be fixed during the process of drilling and screw placement. Fluoroscopy was not necessary during the placement of the

screws, but required whenever we felt not confident enough or after the screws were inserted. The patient then underwent laminectomy for decompression, then the rod was inserted and the screw nuts were tightened. Finally the posterior lateral aspects of the lateral mass and the facet joint underwent decortication for bony fusion using bone grafts. Drainage catheters were placed before the closure of the wound.

The patients were followed up for at least 6 months. Plain X-ray cervical spine was done in AP and lateral study before discharge from the hospital and at 2 months interval later on. The patients were recommended to wear hard cervical collar for at least 6 weeks postoperative, bony fusion recorded within this period of follow up.

3. Results

The 2 groups were operated, group I comprised 32 patients (100%) operated with decompressive laminectomy with lateral mass fixation. It comprised 22 males (68.8%) and 10 females (31.2%), the age ranged from 36 to 63 years with a mean of 48.0 ± 8.68 . Group II comprised 30 patients (100%) operated upon by decompressive laminectomy only without fixation, it comprised 18 males (60%) and 12 females (40%), the age ranged from 40 to 66 years with a mean of 51 ± 7.73 (Table 1).

In group I, neck pain was the most commonly present in all the 32 patients (100%) followed by brachialgia in 18 patients (56.3%). Myelopathy was present in 26 patients (81.3%) according to the JOA-score, grade 1 myelopathy in 16 patients (61.6%), grade 2 myelopathy in 7 patients (26.9%) and only 3 patients (11.5%) with grade 3 myelopathy. Sphincteric disturbance was present in 11 patients (34.4%). In group II, neck pain was present in 30 patients (100%) followed by brachialgia in 26 patients (86.7%). Myelopathy was present in 28 patients (93.3%), grade 1 myelopathy in 10 patients (35.7%), grade 2 myelopathy in 14 patients (50%) and 4 patients (14.3%) with grade 3 myelopathy. Sphincteric disturbance was present in 10 patients (33.3%) (Table 2).

In group I, the operative time ranged from 90 to 140 min with a mean of 110 ± 14.16 min, the hospital stay ranged from 2 to 7 days with a mean of 4 ± 1.76 days and the blood loss ranged from 250 to 800 ml with a mean of 480 ± 193.04 ml. In group II, the operative time ranged from 45 to 120 min with a mean of 75 ± 24.38 min, the hospital stay ranged from 1 to 6 days with a mean of 3 ± 1.57 days and the blood loss ranged from 100 to 450 ml with a mean of 220 ± 111.22 ml (Table 3).

In group I, 18 patients (56.3%) were operated from C3 to C6 levels followed by C3–7 in 8 patients (25%), 4 patients (12.5%) from C4 to C7 and lastly 2 patients (6.2%) from C4 to C6 (Table 4).

A total of 268 screws were used most of them (252 screws)(94%) were 3.5 mm in thickness and 16 screws (6%) were 4 mm as revision screws. 6 screws were used in 2 patients (6.3%), 8 screws were used in 22 patients (68.7%), and 10 screws were used in 8 patients (25%). The length of screws varied from patient to patient and according to the level of fixation we found that 14 screws (5.2%) were 12 mm in length, 70 screws (26.1) 14 mm, 160 screws (59.7%) 16 mm and finally 24 screws (9%) 18 mm (Table 5).

As regards the complications, we found no recorded cases of spinal cord injury or spinal nerve root injury in both groups. In group I screw pullout occurred in 4 screws of 268 screws

Table 1 Age and gender of the patients.

	Group I (n = 32)		Group II (n = 30)		Test of sig.
	No.	%	No.	%	
Sex					
Males	22	68.8	18	60.0	$p = 0.472$
Females	10	31.2	12	40.0	
Age (years)					
Range	36.0–63.0		40.0–66.0		^a $p = 0.123$
Mean \pm SD	48.0 \pm 8.68		51.0 \pm 7.73		

p : p value for Chi Square test.

^a p value for Student t -test.

Table 2 The clinical presentation of the patients.

Clinical data	Group I (n = 32)		Group II (n = 30)		Test of sig.
	No.	%	No.	%	
Neck pain	32	100.0	30	100.0	–
Brachialgia	18	56.3	26	86.7	FEp = 0.012*
Myelopathy	26	81.3	28	93.3	
Grade 1	16	61.6	10	35.7	MCp = 0.155
Grade 2	7	26.9	14	50.0	
Grade 3	3	11.5	4	14.3	
Sphincteric disturbance	11	34.4	10	33.3	$p = 0.931$

FEp: p value for Fisher Exact test; MCp: p value for Monte Carlo test; p : p value for Chi Square test.

* Statistically significant at $p \leq 0.05$.

Table 3 Operative data of the two groups.

Operative data	Group I (n = 32)	Group II (n = 30)	Test of sig.
Operative time (min)			
Range	90.0–140.0	45.0–120.0	<0.001*
Mean \pm SD	110.0 \pm 14.16	75.0 \pm 24.38	
Hospital stay (days)			
Range	2.0–7.0	1.0–6.0	0.046*
Mean \pm SD	4.0 \pm 1.76	3.0 \pm 1.57	
Blood loss (ml)			
Range	250.0–800.0	100.0–450.0	<0.001*
Mean \pm SD	480.0 \pm 193.04	220.0 \pm 111.22	

[†] p : p value for Student t -test.

* Statistically significant at $p \leq 0.05$.

Table 4 Laminectomy levels and fixation in group I.

Levels of laminectomy and fixation	Group I (n = 32)	
	No.	%
C3–6	18	56.3
C3–7	8	25.0
C4–7	4	12.5
C4–6	2	6.2

used in 4 different patients that were managed conservatively as there was no complaint from them (12.5%). Dural tear was present in 2 patients (6.3%) in group I and 1 patient (3.3%) in group II. Postoperative neurological deficit occurred

in 2 patients in group I (6.3%) and 3 patients (10%) in group II in comparison with the preoperative condition of the patients. In group I, we found that 2 patients (6.3%) complained of posterior circulation ischemia as vertigo, dizziness and vomiting mostly due to excessive epidural hemorrhage during dissection and screw insertion. No wrong level was detected in postoperative radiography. In group I, we recorded 3 patients (9.4%) complained of superficial wound infection that was treated medically in comparison with 2 patients (6.7%) in group II. No recorded cases of vertebral artery injury were found (Table 6).

In group I, plain X-ray was done in A–P and lateral positions for all the patients immediately postoperative and after 2 month interval till bony fusion was detected. Bony fusion

Table 5 Instrument profile.

No. of screws per patient	No. of patients	%
6 screws	2	6.3
8 screws	22	68.7
10 screws	8	25.0
Total no of screws	268	100.0
Thickness of the screws used	No. of screws	%
3.5 mm	252	94.0
4 mm	16	6.0
Average length of screws used	No. of screws	%
12 mm	14	5.2
14 mm	70	26.1
16 mm	160	59.7
18 mm	24	9.0

was achieved in all the patients after 6 month follow up. Stability of the fixation was confirmed in postoperative X-ray in flexion and extension films in all the patients.

As regards the outcome of the patients according to the clinical conditions determined by the visual analog scale VAS we found that in group I, neck pain improved in 22 patients (68.8%) and 8 patients (25%) remained stationary without improvement and only 2 patients (6.2%) deteriorated mostly due to wound infection, but in group II we found that neck pain improved in 14 patients (46.7%) and 7 patients (23.3%) remained stationary without improvement and 9 patients (30%) deteriorated mostly due to increased kyphosis. This indicates that neck pain improved much better in group I in comparison with group II with positive clinical significance test.

As regards brachialgia, determined by the visual analog scale VAS, we found in group I, brachialgia improved in 15 patients (83.3%) and 2 patients (11.1%) remained stationary without improvement and only 1 patient (5.6%) deteriorated mostly due to dural tear intraoperative, but in group II we found that brachialgia improved in 16 patients (61.5%) and 7 patients (29.9%) remained stationary without improvement and 3 patients (11.5%) deteriorated mostly due to foraminal stenosis. This indicates that brachialgia improved much better in group I in comparison with group II with positive clinical significance test.

As regards the myelopathy and sphincteric disturbance, we found that both group I and group II showed improvement of

the 3 grades but without any clinically significant difference (Table 7 and Fig. 1).

4. Discussion

Lateral mass cervical fixation is good technique for posterior cervical stabilization for treating instability of the lower cervical spine after extensive multiple-level cervical laminectomies with reversed lordosis.²⁻¹⁴ It is safe and reliable, but it is difficult to be used in patients with abnormal cervical anatomy. In this study, 2 groups were operated, group I comprised 32 patients (100%) operated with decompressive laminectomy with lateral mass fixation. It comprised 22 males (68.8%) and 10 females (31.2%). Group II comprised 30 patients (100%) operated upon by decompressive laminectomy only without fixation, it comprised 18 males (60%) and 12 females (40%). In both groups we found that males are more affected than females as they were more exposed to trauma but there were no significant statistical differences between both groups as regards the sex. This was matched with other studies by Watter and Levinthal²¹ who showed that males were more affected than females (61% males and 39% females) in a similar study and also Olaorie and Thomas¹³ who found that males are commonly affected than females (65 males to 35 females) in another study.

In group I, the age ranged from 36 to 63 years with a mean of 48.0 ± 8.68 , and in group II, the age ranged from 40 to 66 years with a mean of 51 ± 7.73 . These are mostly because decompressive laminectomy is usually done in the old age group but there was no significantly statistical differences between both groups as regards the age which are matched with many studies as in Watter and Levinthal²¹ study who showed that the average age was 46 years and Olaorie and Thomas¹³ showed that the average age was 47 years, and finally Jankowitz⁸ showed that the average age was 50-60 years in a large series.

In group I, neck pain was most commonly present in all the patients (100%) followed by brachialgia in 56.3%. Myelopathy was present in 81.3%, grade 1 myelopathy in 61.6% and grade 2 myelopathy in 26.9% and 11.5% with grade 3 myelopathy. Sphincteric disturbance was present in 34.4%. In group II, neck pain was present in 100% of patients followed by brachialgia in 86.7%. Myelopathy was present in 93.3%, grade 1 myelopathy in 35.7% and grade 2 myelopathy in 50% and 14.3% with grade 3 myelopathy. Sphincteric disturbance was present in 33.3%.

Table 6 Complications in the 2 groups.

Complications	Group I (n = 32)		Group II (n = 30)		FEp
	No.	%	No.	%	
Screw pullout	4	12.5	0	0.0	0.114
Intraoperative spinal cord or nerve root injury	0	0.0	0	0.0	-
Dural tear	2	6.3	1	3.3	1.000
Posterior circulation ischemic manifestation as vertigo	2	6.3	0	0.0	0.492
Postoperative new neurological deficit as myelopathy or radiculopathy	2	6.3	3	10.0	0.667
Vertebral artery injury	0	0.0	0	0.0	-
Superficial wound infection	3	9.4	2	6.7	1.000

FEp: *p* value for Fisher Exact test.

Table 7 Outcome as regards the clinical presentation of the patients.

Outcome and Clinical data	Group I (n = 32)		Group II (n = 30)		Test of sig.
	No.	%	No.	%	
Neck pain	32	100.0	30	100.0	–
Improved	22	68.8	14	46.7	<i>p</i> = 0.044*
Stationary	8	25.0	7	23.3	
Deteriorated	2	6.2	9	30.0	
Brachialgia	18	56.3	26	86.7	FEP = 0.012*
Improved	15	83.3	16	61.5	MCp = 0.373
Stationary	2	11.1	7	29.9	
Deteriorated	1	5.6	3	11.5	
Myelopathy	26	81.3	28	93.3	
Grade 1	16	61.5	10	35.7	MCp = 0.155
Improved	12	75.0	7	70.0	
Stationary	4	25.0	2	20.0	
Deteriorated	0	0.0	1	10.0	MCp = 0.597
Grade 2	7	26.9	14	50.0	
Improved	4	57.1	8	57.1	
Stationary	2	28.6	3	21.4	MCp = 1.000
Deteriorated	1	14.3	3	24.4	
Grade 3	3	11.5	4	14.3	
Improved	1	33.3	2	50.0	MCp = 1.000
Stationary	2	67.7	1	25.0	
Deteriorated	0	0.0	1	25.0	
Sphincteric disturbance	11	34.4	10	33.3	<i>p</i> = 0.931
Improved	6	54.5	4	40.0	MCp = 0.819
Stationary	4	36.4	5	50.0	
Deteriorated	1	9.1	1	10.0	

p, *p* value for Chi Square test; MCp, *p* value for Monte Carlo test; FEP, *p* value for Fisher Exact test.

* Statistically significant difference when *p* < 0.05.

There was a significant difference as regards the improvement of neck pain and brachialgia between both groups. We found that the improvement of neck pain in group I was 68.8% in comparison with 46.7% in group II and also brachialgia improved in group I (83.3%) in relation to group II (61.5%). The improvement was mostly due to the stability of the cervical spine after fixation and widening of the intervertebral foramen to decompress the nerve root in group I. This was matched with other studies as Epstein and Janin⁴ recorded 85% improvement after cervical laminectomy with fixation in comparison with other posterior laminectomy. This improvement is much better if we removed the anterior osteophytes through poster lateral approach. Herkowitz⁷ found that the incidence of postoperative kyphosis after cervical laminectomy with partial medial facetectomy was 25% after 2 year follow up period leading to recurrent neck pain and brachialgia, also Symon and Lavender¹⁷ recorded 70% improvement in patients operated with cervical laminectomy only without fixation in comparison with 85% improvement after fixation.

As regards the myelopathy and sphincteric disturbance, we found that both group I and group II showed improvement of 3 grades of myelopathy but without any clinically significant difference. The improvement of grade 1 myelopathy was 75% in group I in relation to 70% in group II and grade 2 improvement was 57.1% in both groups and in grade 3 the improvement was 33.3% in group I to 50% in group II, and finally the sphincteric disturbance improved in both groups to 45.5% in group I and to 40% in group II. This was mostly

due to the same decompression of the cord without clinical difference in both groups. Kumar et al.¹¹ recorded 80% improvement with good outcome and 76% improvement in myelopathy score after cervical laminectomy with lateral mass fixation.

There was a significant difference between both groups as regards the operative time, blood loss and the hospital stay. We found that in group I, the mean operative time was 110 ± 14.16 min but in group II, was 75 ± 24.38 min, and *p* value < 0.001*. The mean hospital stay in group I was 4 ± 1.76 days and in group II, was 3 ± 1.57 days with *p* value < 0.046*. Finally, the mean blood loss in group I, was 480 ± 193.04 ml and in group II, was 220 ± 111.22 ml, with *p* value < 0.001*. The blood loss in group I is more than that in group II due to long operative time and lateral dissection during surgery with the injury of the epidural and paravertebral venous plexuses.

There was no significant difference between both groups as regards the post operative complications; there were no cases of spinal cord or nerve root or vertebral artery injury in both groups. Dural tear occurred in 6.3% in group I and 3.3% in group II. Superficial wound infection occurred in 9.4% in group I and 6.7% in group II. Screw loosening and pullout occurred in 4 screws of 268 screws used in 4 different patients. Heller et al.⁶ and Kast et al.¹⁰ found in a series of patients operated for decompressive laminectomy with lateral mass fixation that the incidence of nerve root injury was 0.69%, screw loosening was 1.17%, infection was 1.3%, facet breakout was

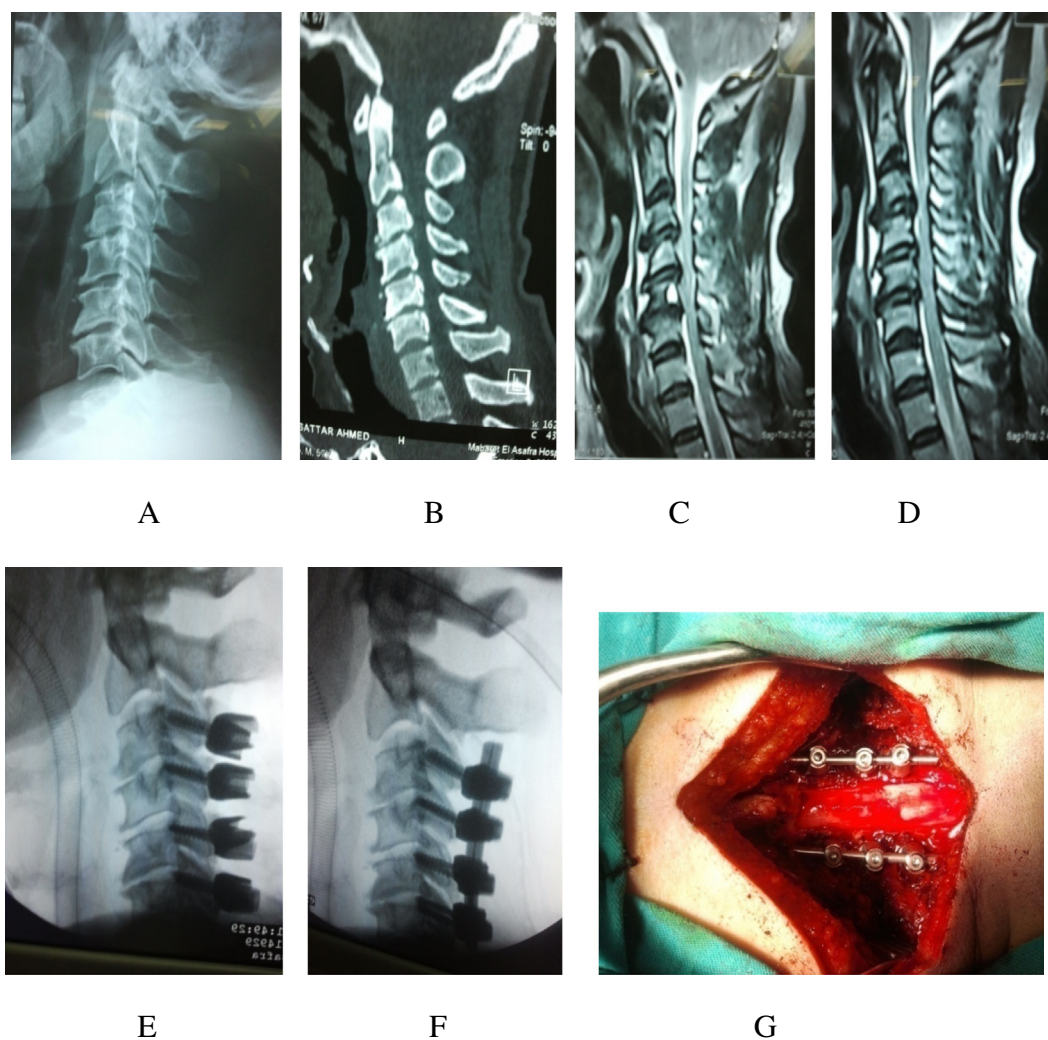


Figure 1 (A) Preoperative plain X-ray cervical spine lateral view of a male patient 57 years old presented with quadromyelopathy, operated with cervical laminectomy with lateral mass fixation, (B) Preoperative multislice CT cervical spine, (C, D) Sagittal MRI T2 weighted image of the cervical spine of the same patient before surgery, (E, F) fluoroscopic photo of the cervical spine after the insertion of the screws in lateral view of the same patient, (G) operative photo of the same patient after fixation.

0.2%, and 0% vertebral artery injury was very rare. Graham et al.⁵ in a series of patients with lateral mass fixation reported 6.1% incidence of screw malposition and 1.8% incidence of radiculopathy per screw with no vertebral artery injury. Traynelis²⁰ found that decompressive laminectomy with lateral mass fixation results in successful arthrodesis in 98% of patients and less than 1% neurovascular injury.

Bony fusion was achieved in all the patients after 6 month follow up. Stability of the fixation was confirmed in postoperative X-ray in flexion and extension films in all the patients of group I. Swank et al.¹⁸ found that the incidence of fusion with lateral mass fixation was 98%.

5. Conclusions

Lateral mass fixation of the cervical spine after multilevel cervical laminectomy is safe and reliable. It has undergone rapid evolution with many new techniques for fixation. It allows excellent decompressions of the cervical canal with

few complications and also restores cervical lordosis with rigid fixation and prevents further kyphosis. It also improves neck pain and brachialgia.

Conflict of interest

The authors have no conflict of interest to declare.

References

1. Al Barbarawi MM, Audat ZA, Obeidat MM, et al. Decompressive cervical laminectomy and lateral mass screw-rod arthrodesis. *Surgical analysis and outcome. Scoliosis* 2011;6:10.
2. Andrew AM, Paul RA, Sameer M, et al. Anatomic considerations for standard and modified techniques of cervical lateral mass screw placement. *Spine J* 2002;2:430–5.
3. David WL, Thomas JL, Pawan R, et al. Comparison of tension band wiring and lateral mass plating for subaxial posterior cervical fusion. *Surg Neurol* 1998;50:323–32.

4. Epstein JA, Janin Y, Carras R, et al. A comparative study of the treatment of cervical spondylotic myelopathy: experience with 50 cases treated by means of extensive laminectomy, foraminotomy, and excision of osteophytes during the past 10 years. *Acta Neurochir (Wien)* 1982;**61**:89–104.
5. Graham AW, Swank ML, Kinard RE, et al. Posterior cervical arthrodesis and stabilization with a lateral mass plate: clinical and computed tomographic evaluation of lateral mass screw placement and associated complications. *Spine J* 1996;**21**:323–9.
6. Heller JG, Silcox H, Sutterlin CE. Complications of posterior cervical plating. *Spine J* 1995;**20**:2442–8.
7. Herkowitz HN. A comparison of anterior cervical fusion, cervical laminectomy, and cervical laminoplasty for surgical management of multiple level spondylotic radiculopathy. *Spine J* 1988;**13**:774–80.
8. Jankowitz B, Gerstzen P. Decompression for cervical myelopathy. *Spine J* 2006;**6**:317–22.
9. Jau-Ching W, Wen-Cheng H, Yu-Chun C, et al. Stabilization of subaxial cervical spines by lateral mass screw fixation with modified Magerl's technique. *Surgical Neurol* 2008;**70**:25–33.
10. Kast E, Mohr K, Richter HP, et al. Complications of Transpedicular screw fixation in the cervical spine. *Eur Spine J* 2006;**15**(3):327–34.
11. Kumar VG, Rea GL, Mervis LJ, et al. Cervical spondylotic myelopathy: functional and radiographic long term outcome after laminectomy and posterior fusion. *Neurosurgery* 1999;**44**:771–7.
12. Liu H, Ploumis A, Schwender JD, et al. Posterior cervical lateral mass screw fixation and fusion to treat pseudarthrosis of anterior cervical fusion. *J Spinal Disord Tech* 2012;**25**(3):138–41.
13. Olaroie SA, Thomas DG. Spinal cord compression due to prolapsed of cervical intervertebral disc. *J Neurosurg* 1983;**59**:847–53.
14. Ren LX, Du W, Zhang P, Ding WY. Enlarged laminectomy and lateral mass fixation for multilevel cervical degenerative myelopathy associated with kyphosis. *Spine J* 2014;**14**(1):57–64.
15. Roy-Camille R, Saillant G, Mazel C. Internal fixation of the unstable cervical spine by a posterior osteosynthesis with plates and screws. In: Sherk HH, Dunn HJ, Eismont FJ, editors. *The Cervical Spine*. 2nd ed. Philadelphia, PA: J.B. Lippincott Company; 1989. p. 390–403.
16. Sekhon LH. Posterior cervical decompression and fusion for circumferential spondylotic cervical stenosis: review of 50 consecutive cases. *J Clin Neurosci* 2006;**13**(1):23–30.
17. Symon L, Lavender P. The surgical treatment of cervical spondylotic myelopathy. *Neurology* 1967;**17**:117–27.
18. Swank ML, Sutterlin III CE, Bossons CR, et al. Rigid internal fixation with lateral mass plates in multilevel anterior and posterior reconstruction of the cervical spine. *Spine* 1997;**22**:274–82.
19. Takayama H, Muratsu H, Doita M, et al. Proprioceptive recovery of patients with cervical myelopathy after surgical decompression. *Spine J* 2005;**30**:1039–44.
20. Traynelis VC. Anterior and posterior plate stabilization of the cervical spine. *Neurosurgery* 1992;**59**:76.
21. Watters WC, Levinthal R. Anterior cervical discectomy with and without fusion: results, complications, and long term follow up. *Spine J* 1994;**19**(20):2343–7.
22. Xu R, Haman SP, Ebraheim NA, et al. The anatomic relation of lateral mass screws to the spinal nerves. A comparison of the Magerl, Anderson, and Ann techniques. *Spine J* 1999;**24**(19):2057–61.
23. Yukawa Y, Kato F, Yoshihara H, et al. Cervical pedicle screw fixation in 100 cases of unstable cervical injuries: pedicle axis views obtained using fluoroscopy. *J Neurosurg Spine J* 2006;**5**:488–93.