



A study of retrograde degeneration of median nerve forearm segment in carpal tunnel syndrome of variable severities



Mona Mokhtar El Bardawil, Gihan Abd El Latief Younis,
Marwa Mohammed Hassan, Eman Ramadan Mohammed *

Alexandria University, Department of Physical Medicine, Rheumatology and Rehabilitation, Egypt

Received 16 April 2013; accepted 24 August 2013
Available online 22 October 2013

KEYWORDS

Carpal tunnel syndrome;
Electrodiagnosis;
Forearm median mixed
study;
Retrograde degeneration

Abstract *Introduction:* Carpal tunnel syndrome (CTS) is a disorder of the hand which results from compression of the median nerve within its fibro-osseous tunnel at the wrist. The slowing in the forearm motor conduction velocity suggests the presence of retrograde degeneration. Existing studies conflict regarding a correlation between the severities of the entrapment neuropathy in CTS and slowing of median motor nerve conduction velocity in the forearm.

Aims: The objective of this work was to study retrograde degeneration (RGD) of the median nerve forearm segment in patients with CTS and its relation to variable severity of CTS in Egyptian patients.

Patients and methods: Twenty-four patients with CTS were included in this study. The Forearm mixed nerve conduction is presumed to be indicative of the conduction of the median nerve over the forearm and is used widely to assess the causes of slowing forearm conduction velocity in CTS. In addition to conventional nerve conduction studies of the upper limb, forearm median mixed conduction studies were performed. Median motor forearm amplitudes and nerve

Abbreviations: CTS, carpal tunnel syndrome; RGD, retrograde degeneration; NCV, nerve conduction velocity; MNAP, mixed nerve action potential; MCp, Monte Carlo test.

* Corresponding author. Present address: Alexandria University, Faculty of Medicine, Department of Physical medicine, Rheumatology and Rehabilitation, Egypt.

E-mail addresses: mona_mokhtar@yahoo.com (M.M. El Bardawil), gihan_younis@yahoo.com (G.A.E.L. Younis), hussamradwan@yahoo.com (M.M. Hassan), emyramadan2008@yahoo.com (E.R. Mohammed).

Peer review under responsibility of Alexandria University Faculty of Medicine.

<http://dx.doi.org/10.1016/j.ajme.2013.08.002>

2090-5068 © 2013 Alexandria University Faculty of Medicine. Production and hosting by Elsevier B.V. All rights reserved.

conduction velocities (NCVs) as well as forearm median mixed amplitudes and NCVs were considered as parameters of RGD.

Results: There were statistically significant differences as regards forearm mixed nerve action potential (MNAP) amplitude and median motor amplitude in the forearm segment but there were no statistically significant differences as regards forearm median mixed peak latency and NCV. There was no statistically significant relation between grades of severities of CTS in the studied hands and both forearm median motor NCV and forearm MNAP amplitude using Monte Carlo test ($MCp = 0.323$ and 0.464).

Conclusions: Retrograde degeneration exists in patients with CTS. Forearm median motor NCV and median mixed conduction study are valid electrophysiologic tools for the assessment of RGD in patients with CTS. Retrograde degeneration is not related to grade of severity of CTS.

© 2013 Alexandria University Faculty of Medicine. Production and hosting by Elsevier B.V. All rights reserved.

1. Introduction

Carpal tunnel syndrome (CTS) is a constellation of symptoms associated with compression of the median nerve at the wrist. It is the most common entrapment neuropathy.¹ Symptoms usually start gradually, with frequent burning, tingling and/or numbness in the palm of the hand and the fingers, especially the thumb, the index and middle fingers. A person with CTS may wake up feeling the need to “shake out” the hand or wrist. As symptoms worsen, people might feel tingling during the day. Decreased grip strength may make it difficult to form a fist, grasp small objects, or perform other manual tasks. By clinical examination, there is hypoesthesia of median nerve distribution in the hand, wasting of the thenar eminence, weakness of thumb abduction and/or opposition. Also positive Phalen’s test and Tinel’s sign are important in diagnosis of CTS.²⁻⁴

Nerve conduction studies (NCSs) are sensitive measures of detecting compression of the median nerve. In CTS, electrodiagnosis rests upon demonstrating delayed median nerve conduction across the carpal tunnel in context of normal conduction elsewhere. Compression results in damage to the myelin sheath and manifests as delayed latencies and slowed conduction velocities but in more severe cases it may be associated with axonal loss.^{5,6} It was found that, in patients with CTS with normal sensory and motor conduction velocities, comparative studies are useful for the diagnosis of very mild CTS. Carpal tunnel syndrome had been divided by Bland⁷ into 6 grades ranging from very mild CTS where the only abnormality is demonstrated by comparative studies, to extremely severe CTS where sensory and motor evoked potentials are effectively unrecordable.⁵⁻⁷

Retrograde degeneration of the median nerve in CTS represents pathophysiological changes affecting the median nerve proximal to the site of compression in the carpal tunnel.¹⁵ This phenomenon was noticed during routine nerve conduction study in the form of slowed NCV in the median motor NCS of the forearm segment. Weiss and Hiscoe⁹ reported in their experiment that nerve constriction indicates swelling and fluid accumulation in the area that lies proximal to the site of injury. They uphold that this is due to an obstruction effect on the axoplasm inside the nerve fiber. Later on after release of noxious substances, there were irreversible findings in the form of atrophic changes that appeared in some of the median nerve fibers in the forearm.^{8,9}

A sign of RGD proximal to the carpal tunnel is the reduction in amplitude of the mixed nerve action potential. It has also been

shown that patients with severe CTS with gross atrophy of the abductor pollicis brevis muscle; motor nerve conduction velocity and CMAP amplitude could not be measured in the forearm segment.¹⁰ Only few researches have discussed retrograde degeneration of forearm segment of median nerve in patients with CTS. As retrograde degeneration can affect the prognosis of patients with CTS even after surgical intervention, this point needs to be more clarified and assessed using the appropriate electrodiagnostic techniques. Moreover, whether retrograde degeneration is related to the severity of CTS also needs clarification. The aim of this work is to study RGD of the median nerve forearm segment in CTS of variable severity.

2. Subject and methods

The study was carried out on twenty four patients diagnosed as idiopathic CTS, according to the criteria proposed by the American Association of Electrodiagnostic Medicine.¹¹ Patients must fulfill at least four of the following signs and symptoms: (1) acroparesthesia or numbness of the hand, (2) nocturnal exacerbation awaking the patient from sleep, (3) exacerbation after manual work, (4) positive Phalen’s or reversed Phalen’s maneuver, (5) positive Tinel’s sign, (6) sensory deficit limited to the distribution of the median nerve passing through the carpal tunnel, (7) weakness of thenar muscles and (8) wasting of thenar muscles.¹¹

Carpal tunnel syndrome patients were divided according to Bland⁷ into seven grades, grade 0 (normal), grade 1 (very mild; CTS demonstrable only with most sensitive tests; comparative studies), grade 2 (mild; sensory nerve conduction velocity slow on finger/wrist measurement, normal distal motor latency), grade 3 (moderate; sensory potential preserved with motor slowing, distal motor latency to APB <6.5 ms), grade 4 (severe; sensory potentials absent but motor response preserved, distal motor latency to APB <6.5 ms), grade 5 (very severe CTS; terminal latency to APB >6.5 ms) and grade 6 (extremely severe; sensory and motor potentials effectively unrecordable (surface motor potential from APB <0.2 mV amplitude).⁵

All patients were recruited from those attending the outpatient clinic of the Physical Medicine Rheumatology and Rehabilitation department at the Main and El Hadara University Hospital. All patients and controls were informed about the research aim and methods and an informed written consent was given by all enrolled subjects.

Patients with secondary causes of CTS; Rheumatoid arthritis, pregnancy, hypothyroidism, acromegaly, trauma and fractures of the wrist, tumors such as a ganglion or a lipoma, metabolic disorders and systemic diseases that can affect the median nerve were excluded from the study. Patients with double crush syndrome were excluded as well.

Complete history taking including complaint, duration of symptoms, affected side and presence of acroparesthesia or numbness of the hand, nocturnal exacerbation awaking the patient from sleep and exacerbation after manual work was recorded.

All studied patients were subjected to a thorough clinical examination including a complete neurological examination stressing on the presence of wasting of the thenar muscles, hypoesthesia confined to the radial three and half digits, Phalen's or reversed Phalen's maneuver, Tinel's sign, and weakness of thenar muscles.

The following studies were done for all patients recording from symptomatic hand(s) and controls recording from the dominant hand using NEUROPACK 2 Electroneuromyograph apparatus from Nihon Kohden (Japan) according to Preston and Shapiro: (1) sensory conduction studies including median wrist–finger antidromic sensory nerve conduction study (digit II), ulnar wrist–finger (digit V) antidromic sensory nerve conduction study, superficial radial antidromic sensory nerve conduction study, median versus the ulnar antidromic wrist to digit IV sensory latency study were studied.¹² Motor conduction studies including motor conduction study of median nerve, motor conduction study of ulnar nerve and anterior interosseus motor conduction studies were also performed.¹² F-wave to calculate axillary F central loop (AFCL) latency of median and ulnar nerves and finally the mixed nerve conduction study of median nerve were studied.¹²

Mixed nerve conduction study of median nerve over the forearm segment was performed according to Change¹³ by placing the stimulating electrode at the wrist and the recording surface electrodes over the median nerve at the elbow. The measured parameters were peak latency (PL), amplitude and nerve conduction velocity (NCV).¹³

3. Statistical analysis

Data were analyzed using the Statistical Package for Social Sciences PASW (SPSS ver.18 Chicago, IL, USA). The

distributions of quantitative variables were tested for normality using the Kolmogorov–Smirnov test which revealed abnormal distribution of the data. Thus, non-parametric statistics were applied.¹⁴ Quantitative data were described using median, minimum and maximum. Qualitative data were described using number and percent.

Qualitative dependent variables (between two groups) were compared using Chi-square test whereas, quantitative dependent variables (between two groups) were compared using Mann Whitney *U* test.^{15,16} In all statistical tests, level of significance below which the results were considered to be statistically significant is 0.05.¹⁷ The relation of qualitative variables was evaluated using Fisher Exact and Monte Carlo test.^{18,19} The correlation of quantitative variables was evaluated using Spearman test.¹⁹

The cut-off point values of the studied electrophysiological parameters were calculated using mean \pm 2 SD of the matched control group. The forearm MNAP amplitude cut-off value was calculated using mean \pm 1.5 SD to avoid negative value due to the wide range of recorded amplitude value among controls. Any value above or below the previously mentioned value was considered abnormal.

4. Results

4.1. Clinical findings

The study was carried out on 24 patients, all were females diagnosed as idiopathic CTS, their age ranged from 25 to 65 years, (mean \pm SD: 42.73 \pm 9.69 years).

Six patients (25%) had signs and symptoms of bilateral CTS while eighteen patients had unilateral CTS, ten (45.83%) had dominant hand affection and eight (29.16%) had non dominant hand affection.

The control group included twenty healthy volunteers, all were females with their age ranging from 22 to 57 years, (mean \pm SD: 37.90 \pm 8.27 years) matching with those of CTS patients ($p = 0.982$).

Twenty patients (83.33%) were housewives responsible for their routine home duties; only one (4.17%) was doing minimal hand activities at home; two patients (8.33%) were manual worker (grocery and fish seller) and one (4.17%) was office worker.

Table 1 Median sensory conduction studies in hands of CTS patients and controls.

Median sensory conduction studies	Control ($n = 20$)	Patients ($n = 30$)	p
<i>Sensory peak latency (ms)</i>			
Range	2.80–3.84	3.88–13.80	< 0.001 ^a
Mean \pm SD	3.29 \pm 0.27	5.58 \pm 2.31	
Median	3.24	5.05	
<i>SNAP amp. (μV)</i>			
Range	20.40–81.0	2.14–57.50	< 0.001 ^a
Mean \pm SD	53.34 \pm 16.99	24.61 \pm 16.97	
Median	53.60	19.20	
<i>NCV, hand (m/s)</i>			
Range	49.0–59.70	12.70–43.40	< 0.001 ^a
Mean \pm SD	52.95 \pm 2.82	32.90 \pm 8.46	
Median	53.0	33.65	

^a The value calculated by using mean \pm 1.5 SD.

Table 2 Median motor conduction studies in hands of CTS patients and controls.

Median motor conduction studies	Control (n = 20)	Patients (n = 30)	P
<i>Motor distal latency (ms)</i>			
Range	2.70–4.10	3.50–9.50	< 0.001 ^a
Mean ± SD	3.53 ± 0.45	5.49 ± 1.48	
Median	3.45	5.15	
<i>CMAP amp. distal (mV)</i>			
Range	7.50–22.30	2.27–22.30	0.006 ^a
Mean ± SD	14.89 ± 4.59	10.69 ± 4.40	
Median	14.10	10.17	
<i>CMAP amp. forearm (mV)</i>			
Range	6.67–22.30	1.60–19.0	0.001 ^a
Mean ± SD	14.18 ± 4.43	9.56 ± 4.15	
Median	13.20	10.02	
<i>Motor NCV forearm (m/s)</i>			
Range	50.0–62.20	42.50–62.0	0.061
Mean ± SD	53.84 ± 3.28	51.77 ± 4.72	
Median	53.20	51.15	
<i>Motor NCV arm. (m/s)</i>			
Range	50.0–68.90	50.0–87.50	0.114
Mean ± SD	60.87 ± 5.54	66.24 ± 10.80	
Median	61.95	66.70	
<i>AFCL (ms)</i>			
Range ms	8.50–12.70	8.10–12.80	0.172
Mean ± SD ms	10.32 ± 1.11	10.82 ± 1.29	
Median ms	10.20	10.70	

p: p Value for Mann Whitney test.

SNAP amp.: sensory nerve action potential amplitude.

NCV: nerve conduction velocity.

CMAP amp.: compound muscle action potential amplitude.

AFCL: axillary F central latency.

^a The value calculated by using mean ± 1.5 SD.

4.2. Electrophysiological findings

On comparison between patients and controls as regards the studied electrophysiological data there were significant differences between CTS patients and control group regarding sensory peak latency (PL) from the wrist to digit II, SNAP amplitude, sensory NCV. As regards median motor NCS, also there were significant differences in the distal latency, distal CMAP amplitude and forearm CMAP amplitude. There were no statistically significant differences between the studied groups regarding median motor forearm and arm conduction velocities (NCV forearm, NCV arm) and AFCL (Tables 1 and 2).

4.3. Grading of severity among hands of carpal tunnel syndrome patients

According to the electrophysiological data recorded from patients, the hands of CTS patients had been classified into 4 grades. Out of 30 hands of CTS patients, there were two hands (6.66%) classified as grade 1; while there were six hands (20%) classified as grade 2. There were sixteen hands (53.33%) categorized as grade 3 and six hands (20%) categorized as grade 5 (Fig. 1).

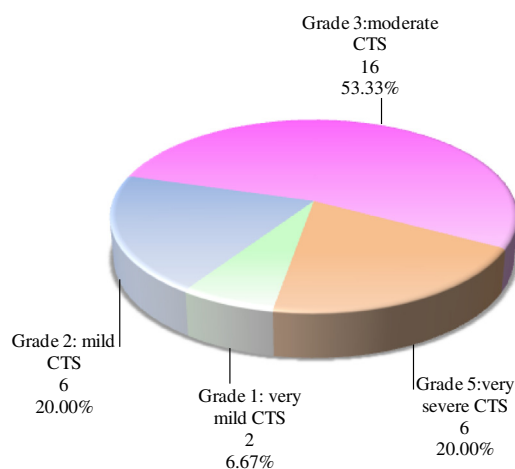


Figure 1 Distribution of grades of severity in the studied hands of CTS patients.

4.4. Electrophysiological parameters of retrograde degeneration

There were statistically significant differences between patients and control group as regards forearm MNAP amplitude and median motor amplitude in the forearm segment but there

Table 3 Forearm mixed nerve conduction of the median nerve in the studied hands of CTS patients and controls.

Mixed median nerve	Control (n = 20)	Patients (n = 30)	p
<i>Peak latency (ms)</i>			
Range	3.12–4.34	2.44–4.72	0.307
Mean ± SD	3.71 ± 0.32	3.78 ± 0.56	
Median	3.72	3.87	
<i>MNAP amp. (µV)</i>			
Range	11.56–56.50	4.0–58.0	0.004 ^a
Mean ± SD	25.6 ± 13.73	15.95 ± 10.78	
Median	20.25	11.60	
<i>NCV, forearm (m/s)</i>			
Range	54.50–85.80	50.88–90.40	0.191
Mean ± SD	68.09 ± 8.78	64.47 ± 8.47	
Median	67.0	63.80	

p: p Value for Mann Whitney test.

NCV: nerve conduction velocity.

^a Statistically significant.

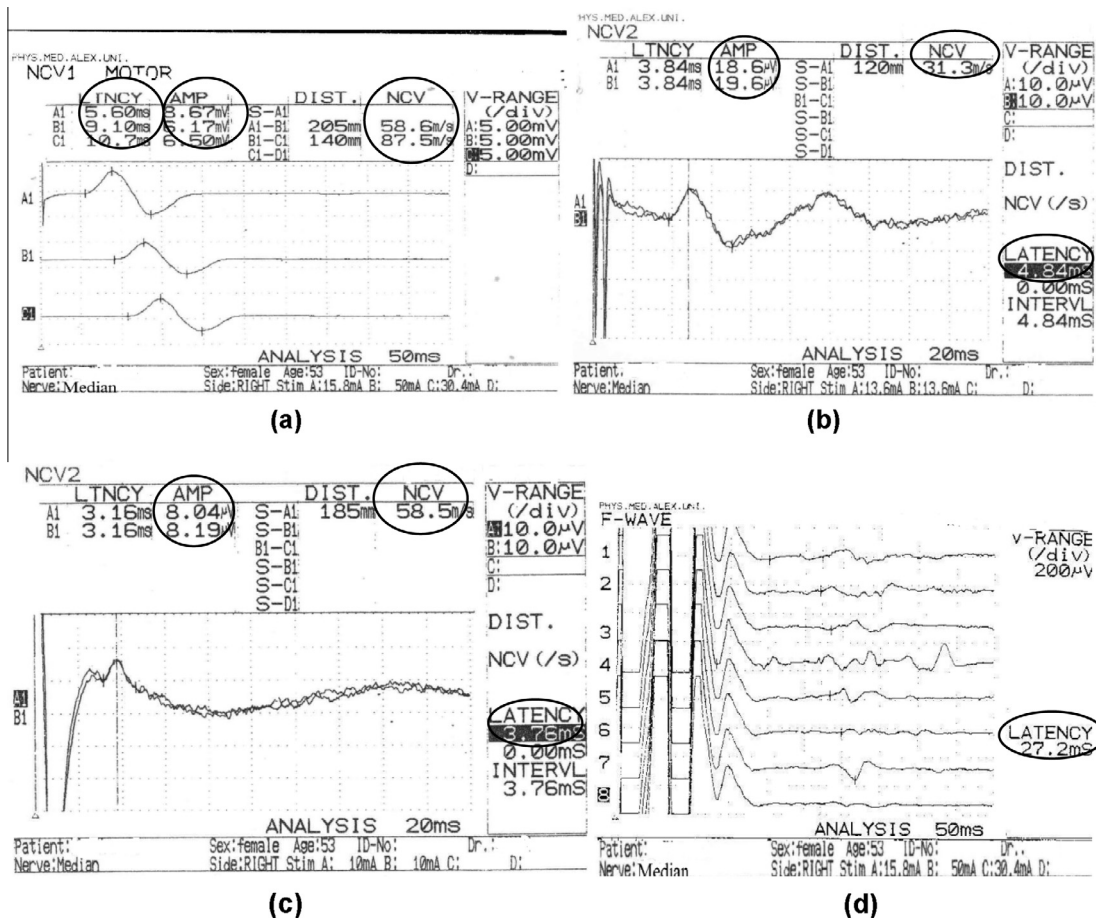


Figure 2 Electrophysiological recordings from a patient with moderate right CTS showing (a) prolonged distal latency, normal amplitude, normal forearm NCV of the median motor conduction study; (b) a prolonged peak latency, slowed NCV and normal amplitude of median sensory conduction study; (c) normal peak latency, amplitude of MNAP and NCV of the forearm median mixed conduction study which means that there is no evidence of retrograde degeneration. Normal AFCL = 11.4 ms (d).

were no statistically significant differences as regards forearm median mixed peak latency and forearm motor NCV (Table 3).

Electrophysiological abnormalities suggestive of RGD were detected in a total of 5 CTS patients. Slowing of the forearm median motor NCV was found in 3 patients

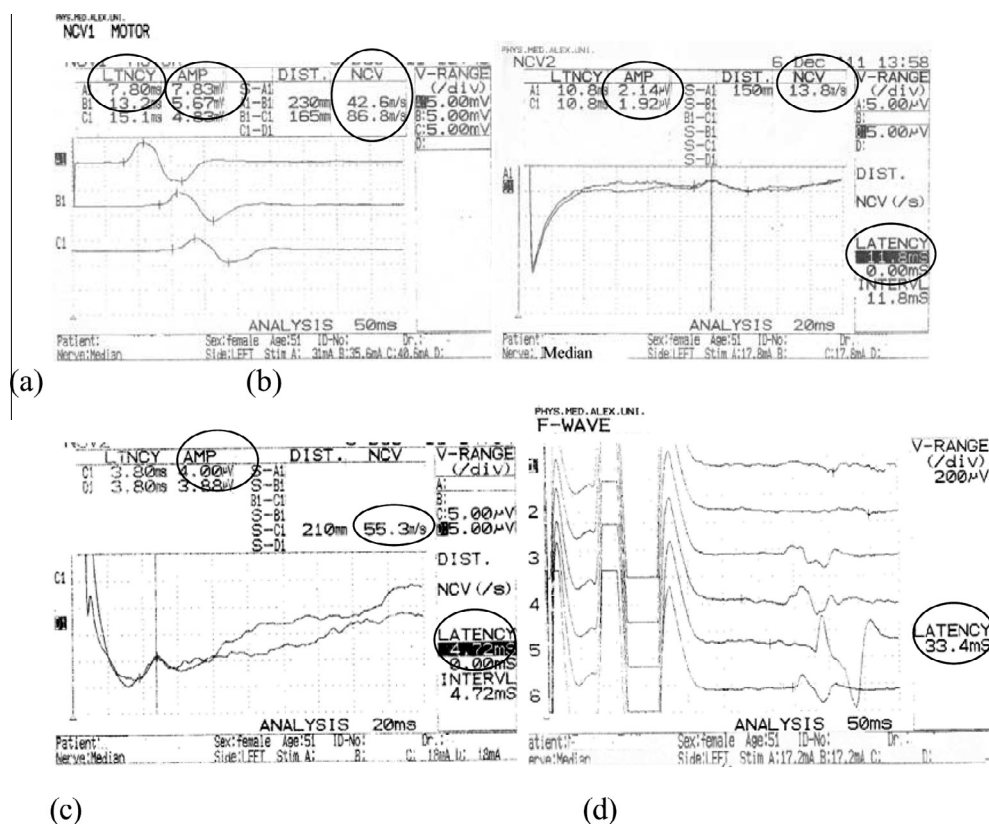


Figure 3 Electrophysiological recordings from a patient with very severe left CTS showing (a) prolonged distal latency, normal amplitude, slowed NCV of the forearm segment of the median motor conduction study; (b) prolonged peak latency, slowed NCV and decreased amplitude of median sensory conduction study; (c) with decreased amplitude of MNAP of the forearm median mixed conduction study and normal peak latency and NCV; (d). Slowed median motor forearm NCV and decreased MNAP amplitude mean that there is retrograde degeneration. Normal AFCL = 10.6 ms (d).

Table 4 Relation between grades of severity of the hands of CTS patients with forearm MNAP amplitude and median motor forearm NCV.

Conduction studies	Grade									
	1 (n = 1)		2 (n = 7)		3 (n = 16)		4 (n = 0)		5 (n = 6)	
	No	%	No	%	No	%	No	%	No	%
<i>Median nerve motor forearm conduction velocity</i>										
-ve	1	100.0	7	100.0	14	87.5	0	0.0	4	66.7
+ve	0	0.0	0	0.0	2	12.5	0	0.0	2	33.3
MCp	0.323									
<i>Mixed median nerve amplitude</i>										
-ve	1	100.0	7	100.0	15	93.8	0	0.0	5	83.3
+ve	0	0.0	0	0.0	1	6.3	0	0.0	1	16.7
MCp	0.464									

MCp: p value for Monte Carlo test.

(13.3%). Moreover, diminished amplitude of forearm median MNAP was detected in one patient with CTS (6.67%) and both abnormalities were detected in another CTS patient (6.67%). In the later 2 CTS patients, the median SNAP amplitudes had 2 of the least 3 values among CTS patients (4.46 and 2.14 μ V, respectively). (Figs. 2 and 3) carpal tunnel syndrome patients with RGD were grade 3 and 5 and durations of disease ranged from 3 to 7 years.

4.5. Relationship between different grades of severity of carpal tunnel syndrome and retrograde degeneration

As there were only abnormalities as regards forearm median motor NCV and forearm MNAP amplitude, they had been considered as the parameters of RGD.

There was no statistically significant relation between different grades of severities of CTS in the studied hands and both

forearm median motor NCV and forearm MNAP amplitude using Monte Carlo test ($MCp = 0.323$ and 0.464) (Table 4).

5. Discussion

Carpal tunnel syndrome is a common disorder of the hand that results from compression of the median nerve within its fibro-osseous tunnel at the wrist. Early diagnosis and intervention can lead to resolution or prevent progression to severe CTS. It is the most common peripheral nerve disorder, with a population prevalence of 5.8% in women and 0.6% in men.²⁰⁻²⁴

Retrograde degeneration (RGD) in median nerve in CTS patients is an electrophysiological finding where there is slowing in the conduction velocity in the segment proximal to site of compression; transverse carpal ligament. Although it is known that at any segmental compression of peripheral nerves the area mostly affected is that directly under the site of compression and followed by the distal segment of the peripheral nerve through Wallerian degeneration according to the duration and severity of compression, it was found that in the proximal segment there is slowed conduction velocity.^{8,9}

In the current work the main aim was to study the relation between RGD of the forearm segment of median nerve and grades of severity of CTS. As there were only abnormalities of the median motor forearm NCV and forearm median mixed amplitude, they had been considered as the parameters of RGD in the current work.

In the forearm median mixed nerve conduction study, there was a statistically significant difference as regards forearm median mixed amplitude but there were no statistically significant differences as regards forearm median mixed peak latency or NCV between CTS patients and controls.

Chang et al.²⁴ were in support of the current results as they found that RGD was represented by diminished forearm median mixed amplitude among CTS patients in comparison with control group and explained that RGD initially involves the medium-sized fibers with the manifestations of the greatly diminished forearm median mixed amplitude and then affects fast conducting fibers, resulting in a decrease of forearm median mixed NCV while the disease progresses.^{9,21} Stoehr et al.²⁵ and Pease et al.²⁶ also found that forearm mixed median conduction study can exactly measure NCV over the forearm.

Hansson²⁷ was also in agreement with the current study as he found that the mixed NCV of the median nerve in the forearm diverged from the motor and sensory nerve conduction velocities. He explained the preserved forearm median mixed NCV in the presence of RGD that the mixed NCV in the forearm is probably determined by non-lesioned fibers such as those from the cutaneous palmar branch of the median nerve. The motor and sensory, but not the mixed nerve conduction velocities in the forearm may be used to estimate possible retrograde impairment in CTS.

As regards the median motor NCV in the forearm segment it was the first studied parameter indicating RGD.^{3,4} In the current work, there were no significant difference between CTS patients and controls as regards median motor forearm NCVs ($p = 0.061$).

Several investigators had reported that the median forearm NCV reflected chronological changes in RGD of the median nerve, and that these changes correlated with the clinical grading of CTS.^{3,4,25} This suggests that electrophysiological studies

can identify signs of neurological impairment in the median nerve beyond the carpal tunnel, as degeneration becomes more extensive. The likely cause of slowing is selective damage of large, rapidly conducting fibers in the carpal tunnel, associated with retrograde nerve fiber degeneration.

In the current work, CTS patients with slowed median motor NCV of the forearm segment had been studied using the anterior interosseus conduction study to exclude median mononeuropathy to be the cause of this slowing.¹²

Buchthal et al.⁸ found slowing of conduction from the wrist to the elbow in only 2% of CTS patients. The variation in incidence was ascribed to the presence of large number of patients with mild and moderate CTS in author's work. Some investigators found accidental slowing of the median forearm segment and they did not find appropriate explanation and considered it an electrodiagnostic artifact rather than pathophysiological changes.²⁶

At individual level, RGD was found in 5 (16.6%) unilateral CTS patients, 4 of them were detected by slowed median motor NCV of the forearm segment, one patient with unilateral CTS was found to have diminished forearm median mixed amplitude and a single CTS patient had both slowed median motor NCV of the forearm segment and diminished forearm median mixed amplitude. those CTS patients were grade 3 and 5 regarding the grade of severity with disease duration ranging from 3 to 7 years.

The last 2 CTS patients who had diminished forearm median mixed amplitude also had 2 out of the 3 least values of median SNAP amplitude which suggest that the reduced amplitudes proximally are a continuation of mainly the sensory fibers passing through the carpal tunnel which had a severe affection based on the electrophysiological grading.^{10,27} The disease duration of both patients was 5 years.

In the current work, the correlation between RGD (using median motor NCV of the forearm segment and the forearm median mixed amplitude) and grade of severity of CTS showed no significant correlation.

Some authors have claimed that the degree of slowing in the forearm is not proportional to the severity of peripheral compression.²⁷⁻²⁹ Chang et al. (b)³¹ found similar results that the reduced median motor NCV of the forearm segment (RGD) were not parallel with the decrease in distal median motor NCV (degree of severity). Hanssen²⁷ also found similar results as regards the median mixed NCV that the fastest fibers, as measured directly from the mixed response in the forearm, were not impaired by wrist compression. This is in contrast to the fastest sensory or motor fibers, as measured indirectly by recording at the hand, which were impaired by the carpal tunnel compression in the wrist. Fox and Bangash³² first found substantial slowing in the median motor NCV of the forearm segment in the presence of a quite-minor abnormality in the carpal tunnel itself. Other studies showed that some CTS patients with normal median motor NCV of the forearm segment of more than 50 m/s had a significant reduction in the median FMCV and CMAP amplitude compared to controls, but this finding was not reproducible. Thus the issue regarding the relationship between severity of compression at wrist and the proximal conduction slowing remains to be elucidated.²⁷⁻³²

Few studies had argued that the occurrence of RGD is specifically associated with the presence of severe compression.³³ Histological studies in animals have demonstrated that RGD is possibly related to the severity of peripheral compression

carried out by Anderson.³⁰ On the other hand, Leif and Trapani³³ found that in CTS the motor NCV proximal to the wrist is reduced in proportion to the degree of severity of the nerve lesion and so the extent of the retrograde changes correlates with the degree of severity and duration of nerve compression.

It was important to study RGD and its relation with the grade of severity in CTS patients to assess the prognosis of the disease and the importance of early surgical intervention even in mild and moderate CTS patients with start of RGD. These findings in the current work suggest that RGD of the median nerve does exist in CTS. Retrograde degeneration is best assessed by median motor forearm NCV. However, retrograde degeneration leads to the reduced forearm median mixed amplitude which substantially results from the block of faster conduction fibers at the wrist. Moreover, RGD is not related to the grade of severity of CTS.

6. Conclusion

Retrograde degeneration exists in patients with carpal tunnel syndrome. Forearm median motor nerve conduction velocity and median mixed conduction study are valid electrophysiologic tools for the assessment of retrograde degeneration in patients with carpal tunnel syndrome. Retrograde degeneration is not related to the grade of severity of carpal tunnel syndrome.

7. Recommendations

Forearm median motor nerve conduction velocity and median mixed conduction studies should be included for the assessment of retrograde degeneration in carpal tunnel syndrome patients. Further studies should be conducted to compare the different proposed electrophysiological parameters of retrograde degeneration in a larger sample size and correlate the sensitivity of each parameter. Inclusion of larger sample size for accurate studying of further risk factors that may have a role in the development of retrograde degeneration should be studied. Postoperative electrophysiological follow up for patients with retrograde degeneration to explain whether it will affect the prognosis after surgical release of transverse carpal ligament should be done.

Conflict of interest

None.

References

- Kostopoulos D. Treatment of carpal tunnel syndrome: a review of the non-surgical approaches with emphasis on neural mobilization. *Bodywork Movement Ther* 2004;**8**(1):2–8.
- Firestein GS, Budd RC, Harris ED, Innes IB, Ruddy S, Sergent JS. Kelleys textbook of rheumatology. In: Ruddy S, editor. *Common etiology for hand and wrist pain*. 8th ed. Philadelphia: Elsevier Butterworth–Heinemann; 2008. p. 255–81.
- Joseph J, Blundo JR. Regional rheumatic pain syndromes. In: Klippel JH, Stone JH, Crofford LJ, White PH, editors. *Primer on the rheumatic diseases*. 13th ed. New York: Springer; 2008. p. 69–87.
- Becker J, Gomes I, Stringari F, Seitensu R, Juliana S, Panosso J. An evaluation of gender, obesity, age and diabetes mellitus as risk factors for carpal tunnel syndrome. *Clin Neurophysiol* 2002;**11**(79):1429–34.
- Herrmann DN, Logigian EL. Electrodiagnostic approach to the patient with suspected mononeuropathy of the upper extremity. *Neurol Clin* 2002;**20**(2):451–69.
- Pecina M, Krmpotic M, Nemanic J, Markiewitz AD. Tunnel syndromes. In: Krmpotic M, editor. *Peripheral nerve compression syndromes*. 2nd ed. New York: CRC Press; 1997. p. 73–6.
- Bland JD. A neurophysiological grading scale for carpal tunnel syndrome. *Muscle Nerve* 2000;**8**:1280–3.
- Buchthal F, Rosenfalck A, Trojaborg W. Electrophysiological findings in entrapment of the median nerve at wrist and elbow. *Neurol Neurosurg Psychiatry* 1974;**37**:340–60.
- Weiss P, Hiscoe HB. Experiments on the mechanism of nerve growth. *Exp Zool* 1988;**107**:315–95.
- Chang HM, Liu LH, Chen LW. The reason for forearm conduction slowing in carpal tunnel syndrome an electrophysiological follow-up study after surgery. *Clin Neurophysiol* 2003;**114**(6):1091–5.
- American Association of Neuromuscular and Electrodiagnostic Medicine. American Academy of Neurology, American Academy of Physical Medicine and Rehabilitation. Practice parameter for electrodiagnostic studies in carpal tunnel syndrome: summary statement. *Muscle Nerve* 2002;**25**:918–922.
- Preston DC, Shapiro BE, editors. *Median neuropathy at wrist. Electromyography and neuromuscular disorders clinical-electrophysiologic correlations*. 2nd ed. Philadelphia: Elsevier Butterworth–Heinemann; 2007. 255–281.
- Chang MH, Wei SJ, Chiang HL, Wang HM, Hsieh PF. The cause of slowed forearm median conduction velocity in carpal tunnel syndrome: a palmar stimulation study. *Clin Neurophysiol* 2002;**113**(7):1072–6.
- Fasano G, Franceschini A. A multidimensional version of the Kolmogorov–Smirnov test. *Mon Not R Astron Soc* 1987;**25**:155–70.
- Nikulin MS. Chi-square test for continuous distributions with scale and shift parameters. *Theor Probab Appl* 1973;**3**:559–68.
- Mann HB, Whitney DR. On a test of whether one of two random variables is statistically larger than the other. *Ann Math Stat* 1947;**18**:50–60.
- Wilcoxon F. Individual comparisons by ranking methods. *Biometrics* 1958;**1**:80–3.
- Stigler S. Fisher and the 5% level. *Chance* 2008;**21**(4):12–24.
- Caruso JC, Cliff N. Empirical size, coverage, and power of confidence intervals for Spearman's Rho. *Ed Psych Meas* 1997;**57**:637–54.
- Padua L, Padua R, Nazzaro M, Tonali P. Incidence of bilateral symptoms in carpal tunnel syndrome. *J Hand Surg* 1998;**23**(5):603–6.
- Jennifer C, Lublin MD, David E, Rojer MI, Barron MD. Carpal tunnel syndrome a review of initial diagnosis and treatment for the ob/gyn. *Primary Care Update Ob/Gyn* 1998;**5**:280–5.
- Kostopoulos D. Treatment of carpal tunnel syndrome: a review of the non-surgical approaches with emphasis on neural mobilization. *Bodywork Movement Ther* 2004;**8**(1):2–8.
- Peter AC. History of carpal tunnel syndrome. In: Riccardo L, Peter AC, editors. *Carpal tunnel syndrome*. 1st ed. Berlin: Springer; 2007.
- Chang HM, Liu LH, Wei SJ, Chiang HL, Hsieh PF. Does retrograde axonal atrophy really occur in carpal tunnel syndrome patients with normal forearm conduction velocity? *Clin Neurophysiol* 2004;**115**(12):2783–8.
- Stoehr M, Petrucci F, Scheglmann K, Schilling K. Retrograde changes of nerve fibers with the carpal tunnel syndrome. *Neurology* 1978;**218**(4):287–92.
- Pease WS, Lee HH, Johnson EW. Forearm median nerve conduction velocity in carpal tunnel syndrome. *Electromyogr Clin Neurophysiol* 1990;**30**:299–302.

27. Hansson S. Does forearm mixed nerve conduction velocity reflect retrograde changes in carpal tunnel syndrome? *Muscle Nerve* 1994;**17**(7):725–9.
28. Werner RA, Andary M. Carpal tunnel syndrome: pathophysiology and clinical neurophysiology. *Clin Neurophysiol* 2002;**113**(9):1373–81.
29. Joynt RL. Correlation studies of velocity, amplitude and duration in median nerve. *Arch Phys Med Rehabil* 1989;**70**:477–81.
30. Anderson MH, Fullerton PM, Gilliatt RW, Hern JE. Changes in the forearm associated with median nerve compression at the wrist in the guinea pig. *Neurol Neurosurg Psychiatry* 1970;**33**:70–7.
31. Chang MH, Wei SJ, Chiang HL, Wang HM, Hsieh PF. The cause of slowed forearm median conduction velocity in carpal tunnel syndrome: a palmar stimulation study. *Clin Neurophysiol* 2002;**113**(7):1072–6.
32. Fox JE, Bangash IH. Conduction velocity in the forearm segment of the median nerve in patients with impaired conduction through the carpal tunnel. *Electroenceph Clin Neurophysiol* 1996;**101**:192–6.
33. Leif AA, Trapani VC. *Atlas of electromyography*. 1st ed. New York: Oxford University Press; 2006, 7–22.