

# Observations on the oesophageal glands in some Tanzanian anurans

K.N. Hirji and A.M. Nikundiwe

Department of Zoology and Marine Biology, University of Dar es Salaam, Dar es Salaam, Tanzania

The occurrence and function of oesophageal glands in some anurans from Tanzania was investigated. The compound glands were present in the oesophageal submucosa of *Ptychadena oxyrhynchus* Smith, *Ptychadena porosissima* Steindachner, *Phrynobatrachus acridoides* Cope, *Chiromantis xerampelina* Peters, *Leptopelis argenteus* Pfeffer, *Kassina maculata* Dumeril, *Afrivalus brachycnemis brachycnemis* Boulenger, *Hyperolius argus* Peters, *Hyperolius puncticulatus* Pfeffer and *Hyperolius tuberilinguis* Smith, but were absent in *Xenopus muelleri* Peters, *Bufo gutturalis* Power and *Phrynomerus bifasciatus bifasciatus* Smith. It is suggested that in anurans, the oesophageal and gastric glands have similar functions.

S. Afr. J. Zool. 1982, 17: 32–34

Die voorkoms en funksie van kliere in die slukderm van 'n aantal paddas vanaf Tanzania is ondersoek. Saamgestelde kliere was teenwoordig in die submucosa van die slukderm van: *Ptychadena oxyrhynchus* Smith, *Ptychadena porosissima* Steindachner, *Phrynobatrachus acridoides* Cope, *Chiromantis xerampelina* Peters, *Leptopelis argenteus* Pfeffer, *Kassina maculata* Dumeril, *Afrivalus brachycnemis brachycnemis* Boulenger, *Hyperolius argus* Peters, *Hyperolius puncticulatus* Pfeffer en *Hyperolius tuberilinguis* Smith, maar was afwesig in *Xenopus muelleri* Peters, *Bufo gutturalis* Power en *Phrynomerus bifasciatus bifasciatus* Smith. Dit word voorgestel dat die slukderm en maagkliere eenderse funksies het.

S.-Afr. Tydskr. Dierk. 1982, 17: 32–34

Although the occurrence of oesophageal glands in amphibians has been reviewed briefly by Reeder (1964), further studies on these glands in African anurans are not available. In addition, the nature of the oesophageal glands is not quite clear. As early as 1894, Kingsbury considered them to be homologous with the gastric glands and Reeder (1964), Goin & Goin (1971) and Porter (1972) reported that they produce pepsinogen, a precursor of the proteolytic enzyme pepsin. Jordan (1927) suggested that in *Hyla*, *Rana*, *Bufo*, *Pelobates* and *Triturus* more pepsinogen was produced in these glands than in the gastric glands.

The aim of the present study was to obtain data on the occurrence of oesophageal glands in selected anurans from Tanzania and to compare their structure with the better known gastric glands.

## Materials and Methods

The following anurans were collected from different areas in Tanzania:

Family Pipidae – *Xenopus muelleri* Peters

Family Bufonidae – *Bufo gutturalis* Power

Family Microhylidae – *Phrynomerus bifasciatus bifasciatus* Smith

Family Ranidae – *Ptychadena oxyrhynchus* Smith, *Ptychadena porosissima* Steindachner, *Phrynobatrachus acridoides* Cope, *Chiromantis xerampelina* Peters, *Leptopelis argenteus* Pfeffer, *Kassina maculata* Dumeril, *Afrivalus brachycnemis brachycnemis* Boulenger, *Hyperolius argus* Peters, *Hyperolius puncticulatus* Pfeffer, *Hyperolius tuberilinguis* Smith. Five frogs from each species were used.

On capture, the frogs were chloroformed, their abdomens opened and the entire oesophagus with a small part of the anterior stomach fixed overnight in Bouin's fluid. The tissues were then dehydrated in ethyl alcohol of ascending concentrations, cleared in xylene and embedded in paraffin wax. Serial sections of 5  $\mu$ m thickness were obtained from the oesophagus and part of the stomach.

The sections were stained in each of the following combinations:

- Iron haematoxylin and eosin.
- Periodic acid Schiffs (PAS) according to Pearse (1968).

K.N. Hirji\* and A.M. Nikundiwe  
Department of Zoology and Marine Biology, University of Dar es Salaam,  
P.O. Box 35064, Dar es Salaam, Tanzania

\*To whom correspondence should be addressed

Received 24 March 1981; accepted 16 July 1981

- (c) Masson's trichrome stain (Goldner-Foot modification).  
 (d) Alcian blue (pH 2,5) and haematoxylin.

## Results

### Oesophagus

Oesophageal glands were present in all Ranidae but were absent in *X. muelleri* (Pipidae), *B. gutturalis* (Bufonidae) and *P. bifasciatus bifasciatus* (Microhylidae). In these species the submucosa consisted only of a rather dense connective tissue with blood vessels and nerves present (Figure 3).

The compound glands were located in the oesophageal submucosa. The cells were pyramidal with large proximal nuclei and distal ends which enclosed the lumen of the acinus and were filled with secretory granules.

In *P. oxyrhynchus* and *P. porosissima* the oesophageal submucosa contained a compact layer of collagen lying close to the tunica muscularis and an inner compact lamina propria situated immediately beneath the oesophageal lining epithelium. The loose connective tissue between these layers accounted for over two-thirds of the total width of the submucosa and contained tightly packed oesophageal glands.

In *L. argenteus* the connective tissue below the lamina propria compact layer was occupied by masses of glands. The short gland ducts penetrated the lamina propria and opened directly into the lumen (Figure 1). The interglandular spaces were occupied by the loose connective tissue.

The entire oesophageal submucosa of *P. acridoides* was occupied by glands leaving only a thin lamina propria tissue beneath the oesophageal epithelium. The masses of glands were surrounded by a thin network of collagen.

In *C. xerampelina* and *K. maculata*, the oesophageal mucosa together with the submucosa was thrown into several deep folds. Numerous glands occupied the loose connective tissue below the lamina propria. In *K. maculata*, the glands were particularly numerous with the interglandular connective tissue more condensed (Figure 2). The mucosa and submucosa were thrown into folds.

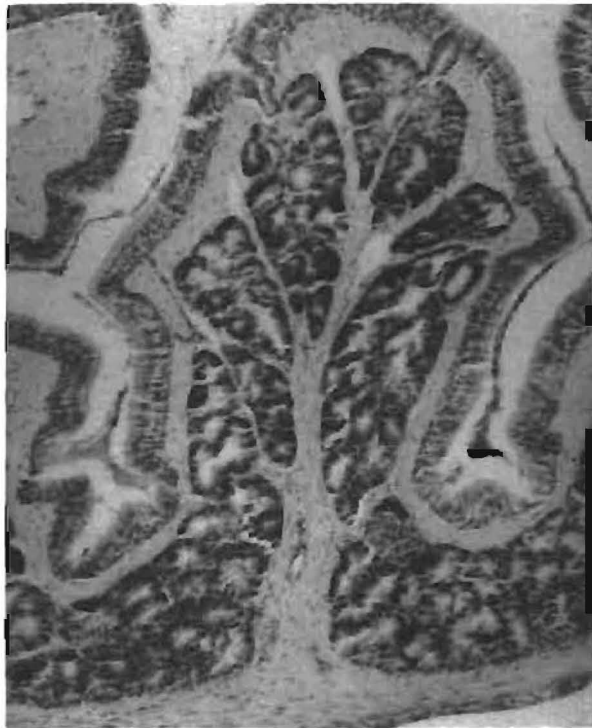

Figure 2 A transverse section through the oesophagus of *K. maculata*. Note the accumulation of oesophageal glands in the folds. Two short ducts can be seen in the upper side of the figure. PAS,  $\times 80$ .

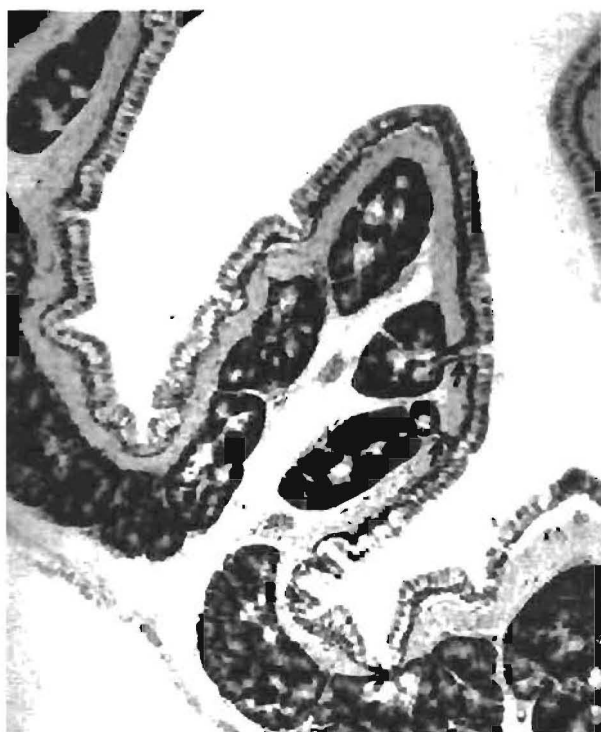

Figure 1 A transverse section through the oesophagus of *L. argenteus* showing oesophageal glands in the submucosa. Note the short ducts (arrows) which open into the lumen. Masson's trichrome,  $\times 80$ .

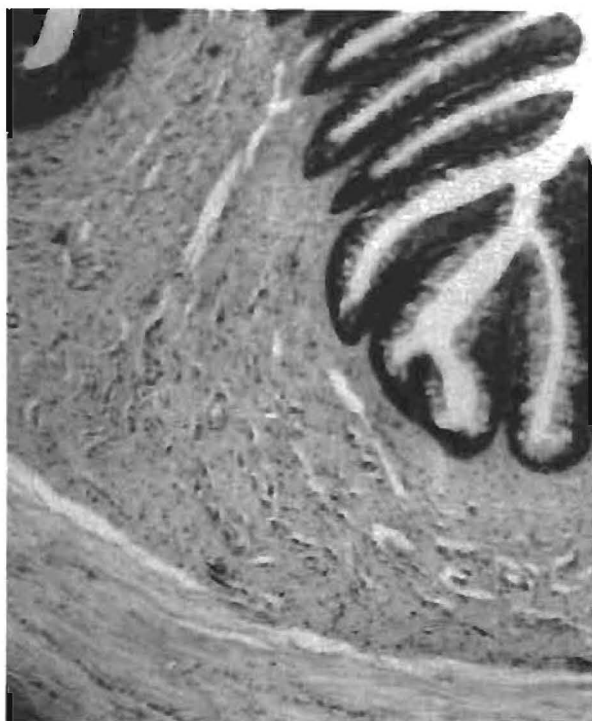


Figure 3 A transverse section through the oesophagus of *B. gutturalis*. Note the absence of oesophageal glands. Masson's trichrome,  $\times 60$ .

In *A. brachycnemis brachycnemis* the entire submucosa which accounted for more than half of the thickness of the oesophageal wall, was occupied by glands. Only a very thin inner compact lamina propria was evident beneath the oesophageal epithelium.

In *H. tuberilinguis*, *H. puncticulatus* and *H. argus*, the tightly packed oesophageal glands were present in the loose connective tissue of the submucosa which, together with the oesophageal mucosa, was thrown into shallow folds.

The glandular cells of all Ranidae were strongly basophilic (haematoxylin combinations) and did not stain with PAS or Alcian blue.

### Stomach

The histological organization of the stomach in all anurans was similar. The gastric wall consisted of four layers; serosa, tunica muscularis, submucosa and mucosa. The latter was composed of a muscularis mucosae, a lamina propria and the lining epithelium. The lining epithelium consisted of mucous cells which were invaginated to form gastric pits at the bottom of which perpendicular orientated simple tubular glands opened. Just below these glands a muscularis mucosae was present. The tubular glands contained chief cells and mucous neck cells (Figure 4). Compared to the cells of the oesophageal glands, the chief cells were less basophilic. However both types of cells showed similar staining with PAS, Alcian blue and Masson's trichrome stain.

### Discussion

According to Pernkopf & Lehner (1937) oesophageal glands are not universally found in amphibians. However, Reeder (1964) states that they are common in amphibians but their distribution shows variations in different species. In our investigation, oesophageal glands were present in all species of Ranidae whilst they were absent in Pipidae, Bufonidae and Microhylidae. As only a single species each of Pipidae, Bufonidae and Microhylidae was examined, it is not possible to present a general conclusion about the occurrence of oesophageal glands in these families. There is also a need to examine many species of Ranidae in order to establish whether the occurrence of oesophageal glands is characteristic of this family.

In Ranidae, oesophageal glands were exclusively found in the submucosa and only minor variations in their distribution were evident in the species.

It has been suggested that oesophageal glands are true homologues of the gastric glands and that they also secrete pepsinogen (Kingsbury 1894; Jordan 1927; Reeder 1964; Porter 1974). In this study, the oesophageal glands failed to stain with PAS and Alcian blue. This indicates that they do not produce mucous substances (Pearse 1968). A biochemical characterization of the secretory product of the oesophageal glands is not available. However, both oesophageal and gastric glands showed similar reactions to stains. On the basis of this observation, it is

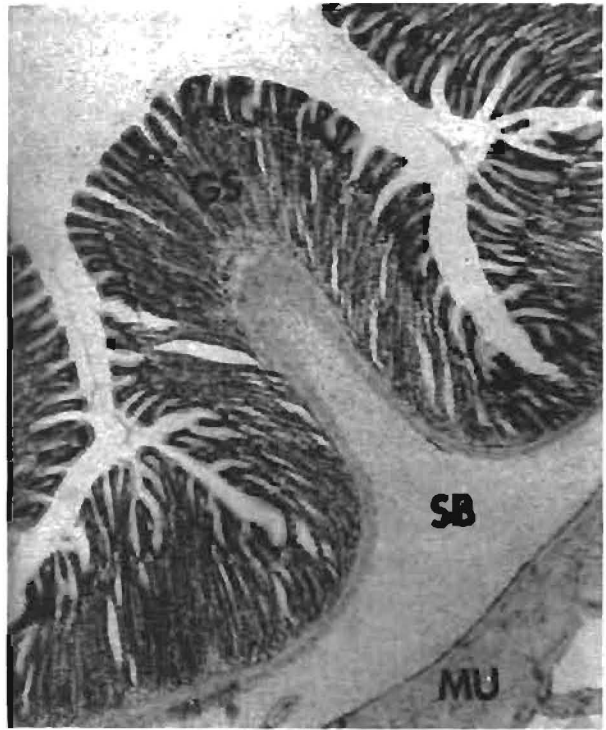


Figure 4 A transverse section through the stomach of *B. gutturalis* showing the gastric glands (GS), muscularis mucosae (MU), submucosa (SB). H/E.  $\times 60$ .

likely that both glands produce pepsinogen.

The large numbers of oesophageal glands observed in Ranidae support the suggestion of Jordan (1927) that in some amphibians the quantity of pepsinogen produced in the oesophageal glands is significant and in some instances may exceed that produced by the gastric glands in the stomach.

### Acknowledgements

We thank Mr E.T. Urasa for his technical assistance and Professor R. Tucker for his constructive comments on earlier drafts of this manuscript.

### References

- GOIN, C.J. & GOIN, O.B. 1971. Introduction to Herpetology. 2nd edn. W.H. Freeman & Co., San Francisco.
- JORDAN, H.J. 1927. Uebungen aus der vergleichenden Physiologie. Springer, Berlin.
- KINGSBURY, B.F. 1894. The histological structure of the enteron of *Necturus maculosus*. *Proc. Am. Microscop. Soc.* 16: 19-64.
- PEARSE, A.G.E. 1968. Histochemistry; Theoretical and Applied. 3rd edn, Vol. 1, J.P.A. Churchill Ltd., London.
- PERNKOPF, E. & LEHNER, J. 1937. Vergleichende Beschreibung des Vorderdarms bei den einzelnen Kranioten. In: Handbuch der vergleichenden Anatomie der Wirbeltiere, eds, Bolk, L., Goppert, E., Kallius, E. & Lubosch, W. Vol. III Urban & Schwarzenberg. Berlin and Vienna.
- PORTER, K.R. 1972. Herpetology. Saunders Company, Philadelphia, London and Toronto.
- REEDER, W.G. 1964. The digestive system. In: Physiology of the Amphibian, ed. Moore, J.A. Academic Press, New York and London.