

## OBSTRUCTIVE UROLITHIASIS IN A 1<sup>1</sup>/<sub>2</sub> – YEAR OLD OUDA–YANKASA RAM: CASE REPORT

\*<sup>1</sup>Alimi O.A., <sup>2</sup>Bello M.B., <sup>3</sup>Baraya Y.S., <sup>3</sup>Raji A.A., <sup>4</sup>Bashir S.,  
<sup>5</sup>Bello A., <sup>1</sup>Abdulkadir S.Z. & <sup>6</sup>Shoyinka S.V.O.

<sup>1</sup>Department of Veterinary Surgery and Radiology, Faculty of Veterinary Medicine,  
University of Ilorin, Ilorin, Nigeria

<sup>2</sup>Department of Veterinary Microbiology, Faculty of Veterinary Medicine,  
Usmanu Danfodiyo University, Sokoto, Nigeria

<sup>3</sup>Department of Veterinary Pathology, Faculty of Veterinary Medicine,  
Usmanu Danfodiyo University, Sokoto, Nigeria

<sup>4</sup>Department of Veterinary Physiology and Biochemistry, Faculty of Veterinary Medicine,  
Usmanu Danfodiyo University, Sokoto, Nigeria

<sup>5</sup>Department of Veterinary Anatomy, Faculty of Veterinary Medicine,  
Usmanu Danfodiyo University, Sokoto, Nigeria

<sup>6</sup>Department of Pathology, Faculty of Veterinary Medicine,  
Usmanu Danfodiyo University, Sokoto, Nigeria

\*Corresponding author's email: [alimialimi@gmail.com](mailto:alimialimi@gmail.com)

### ABSTRACT

*Obstructive urolithiasis is the retention of urine subsequent to the lodgement of calculi in the urinary tract from the kidney up to the urethral orifice. This report describes the post-mortem and chemical analysis findings of the calculi in an 18-month old Ouda-Yankasa cross ram presented at the Large Animal Clinic of the Veterinary Teaching Hospital, Usmanu Danfodiyo University, Sokoto. The patient was presented on 20th of March, 2013 with reports of anorexia, disinclination to drink water and anuria that developed four days before presentation at the clinic. On clinical examination, urethral blockage and mild ascites were observed. Cystocentesis was performed to relieve the patient and plain radiograph taken but was not diagnostic. The patient died before definitive diagnosis was made for rational treatment. The post - mortem findings include frothy exudate in the trachea and bronchial airways, congestion of the lungs, hydroperitoneum with recovered fluid measuring 2,350 ml, splenomegaly, hydronephrosis, distended urinary bladder, severe haemorrhagic cystitis, urinary calculi in the bladder and throughout the urethral length and urethral stricture. The urinary calculi recovered were white, friable and amorphous, ranging from small particles to 5mm in diameter. Histopathologic section of the kidney showed atrophied glomeruli. It can thus be concluded that the atrophied glomeruli in turn impaired glomerular filtration which invariably pre-disposed the patient to uraemia leading to its death. The chemical analysis of the calculi showed that the calculi was either oxalate, phosphate or silicate, or any of these mixtures.*

**Key words:** calculi, obstruction, phosphate, uraemia

### INTRODUCTION

Obstructive urolithiasis is the retention of urine subsequent to lodgment of calculi anywhere in the urinary tract from the bladder up to the urethral orifice (Makhdoomi and Gazi, 2013). It is a metabolic disease of male sheep and goats. The disease occurs when calculi (stones) usually comprised of phosphate salts, lodge in the urinary tract and prevent urination (Susan, 2005). The primary cause of urinary calculi is feeding concentrate diets which are excessive in phosphorus and magnesium and/or have an imbalance of calcium and phosphorus (Susan, 2005). The disease results in heavy economic losses to the livestock

industry as it is attributed to be the fifth most prevalent cause of death in feedlot (Makhdoomi and Gazi, 2013). Incidence of urolithiasis is highest in midwestern and western United States where sheep are confined to feedlot, castrated at an early age and wintered on pasture under natural conditions (Jorgensen and King, 1968). Urethral obstruction has been extensively reported in ruminant species (Smith *et al.*, 1989). Though it affects both sexes, it is a common problem encountered in male sheep, goat and cattle (Winter *et al.*, 1987) because of the anatomical conformation of their urinary tract (Makhdoomi and Gazi, 2013).

The highest occurrence is in young animals castrated before sexual maturity, hindering the hormonal influence necessary for the penis to reach full size (Kahn and Line, 2010). Urolithiasis affects 5–15% of the population worldwide and recurrence rates are close to 50% (Machado *et al.*, 2014). Urolithiasis has no geographic distribution, and the different urolith types reflect the mineral distribution of the feed (Kahn and Line, 2010).

### Case History

On 20<sup>th</sup> of March, 2013, a client presented a 1½-year old Ouda–Yankasa ram, weighing 23 kg at the Veterinary Teaching Hospital, Usmanu Danfodiyo University, Sokoto with complaints of anorexia, disinclination to drink water and anuria that developed four days prior to presentation at the clinic. The patient was said to have been presented at the Sokoto Veterinary Zonal Clinic for haematuria and the condition subsided for three weeks, after which the anuria occurred. The patient was intact, reared intensively on millet, wheat offall and water *ad libitum*. The patient was reported to be the only animal kept by the client for the purpose of rearing for festivity. On clinical examination, urethral blockage and mild ascites were observed. Cystocentesis was performed to relieve the patient and plain radiograph was taken, which was not diagnostic. The patient was placed on 5% oxytetracycline at 5 mg kg<sup>-1</sup> for three days intramuscularly, Vitamin B complex at 1 ml 10 kg<sup>-1</sup> for three days intramuscularly and dewormed with albendazole 7.5 mg kg<sup>-1</sup> per os stat. The patient died before definitive diagnosis was made for rational treatment.

### Post – Mortem Findings

The post – mortem findings include frothy exudate in the trachea and bronchial airways, severe congestion of the lungs, hepatization of the right apical lung lobe, hydroperitoneum with recovered fluid measuring 2,350 ml, splenomegaly, hydronephrosis, distended urinary bladder, severe haemorrhagic cystitis (Figure 1), urinary calculi in the bladder and throughout the urethral length and urethral stricture (Figure 2). The urinary calculi recovered were white, friable and amorphous, ranging from small particles to 5 mm in diameter. Histopathologic section of the kidney showed atrophied glomeruli and tubular cell necrosis (Figure 3). It can thus be concluded that the atrophied glomeruli and tubular cell necrosis in turn impaired glomerular filtration which invariably pre-disposed the patient to uraemia leading to its death.

### Analysis of Urolith Sample

Broadly, the urolith could be any of struvite, calcium oxalate, urate ammonium and sodium urate, cysteine, calcium phosphate or silicate. Therefore, qualitative and quantitative analysis of the metal ions (Mg<sup>2+</sup>, Ca<sup>2+</sup> and Na<sup>+</sup>) were carried out using Shimadzu Atomic Absorption Spectrometer Model AA 700 Japan, while qualitative analysis of other ions (NH<sub>4</sub><sup>+</sup>, PO<sub>4</sub><sup>3-</sup>, C<sub>2</sub>O<sub>4</sub><sup>2-</sup> and Si<sup>4+</sup>) were carried out via wet qualitative tests. The results of the analysis of the metal ions were as follows with their concentrations in mg kg<sup>-1</sup>: Mg<sup>2+</sup> (5,279.60), Ca<sup>2+</sup> (265.78), Na<sup>+</sup> (not detected) and Si<sup>4+</sup> (2923.86). The wet qualitative analysis showed the presence of oxalate and phosphate. From the result, it could be concluded that the urolith was either oxalate, phosphate or silicate, or mixture of these.

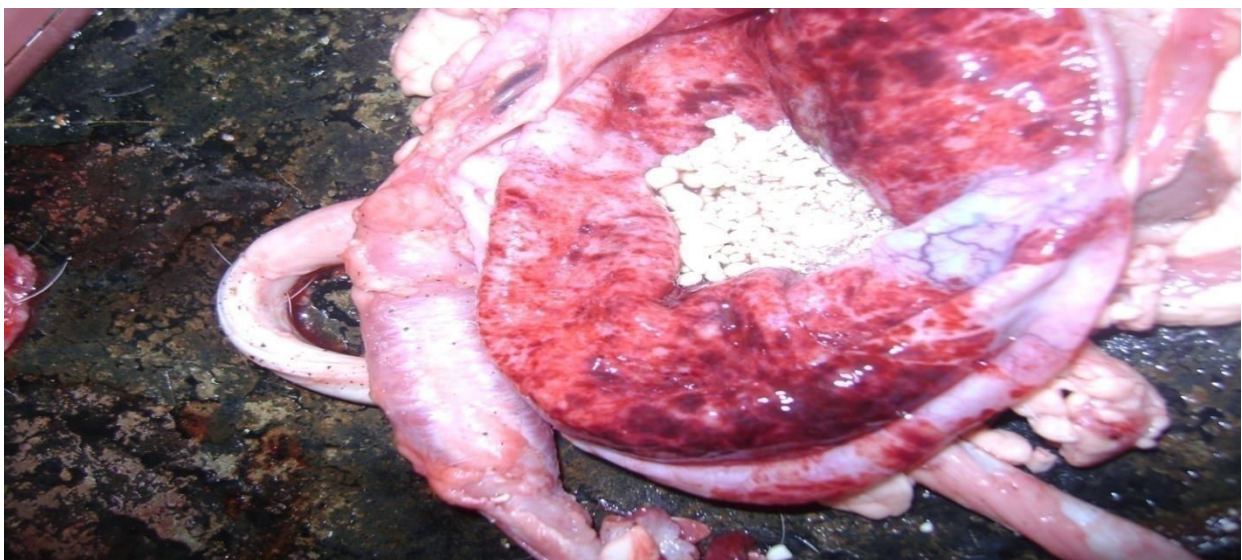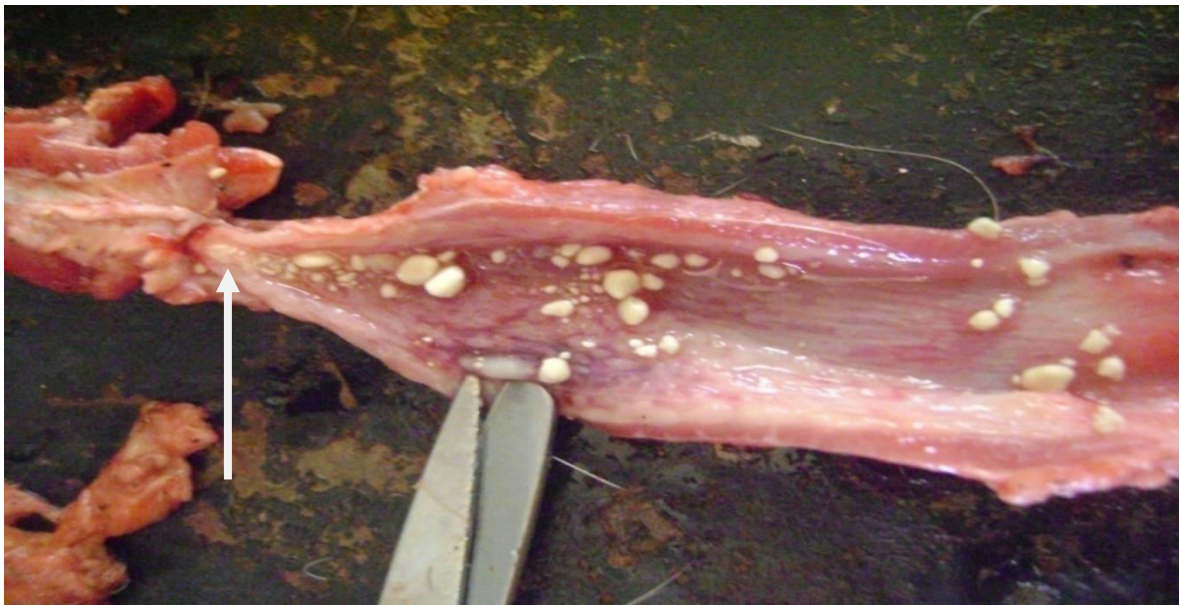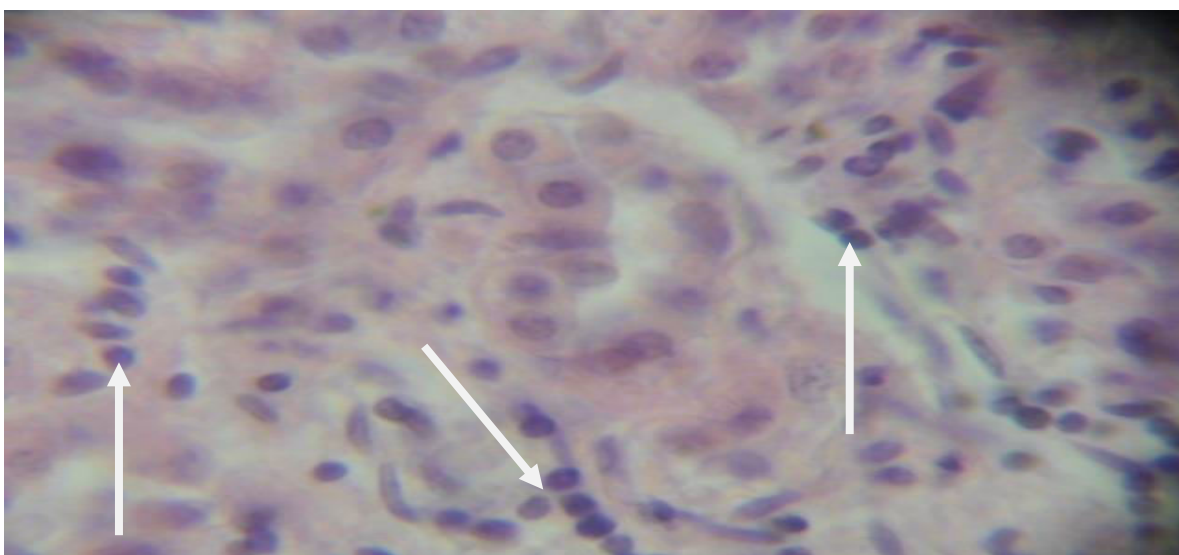


Figure 1: Severe haemorrhagic cystitis





**Figure 2:** Presence of calculi in the urethral and point of urethral stricture (arrow)



**Figure 3:** Arrows showing areas of tubular cell necrosis (H and E x400)

## DISCUSSION

Ovine urolithiasis is a relatively common condition occurring both in growing feedlot lambs and in older rams being kept on pasture (Jorgensen and King, 1968). Early diagnosis of this condition is important, since the longer the condition is allowed to persist the less favorable the prognosis becomes (Jorgensen and King, 1968). The condition may affect a good number of animals in a flock to become of real economic importance (Jorgensen and King, 1968). The primary cause of urinary calculi is feeding concentrate diets which are excessive in phosphorus and magnesium and/or have an imbalance of calcium and phosphorus (Susan, 2005). Urinary calculi can form anywhere within the urinary tract, the kidney, ureter or in the bladder and ranges in sizes and shape (Lohdip *et al.*, 2008). Urinary calculi are the most common

disease disorder, resulting from various factors such as metabolic abnormalities, nutritional factors, bacterial infection and environmental conditions (Kumar *et al.*, 2006). It is thought that diet and alkaline urine may dispose animal to urinary calculi formation. The role of diet rich in the formation calcium carbonate calculi has been reported in ruminants (Kumar *et al.*, 2006). Feeding of high phosphate diet to ruminants could result in the formation of urinary calculi containing calcium (Kumar *et al.*, 2006). High grain rations which animals received on feedlot contribute to the development of urinary calculi and it is common to find a Ca:P ratio of 1:1 in these high concentrate rations (Jorgensen and King, 1968). Cereal grains have an abnormally low calcium to phosphorus ratio of 1:4 to 1:6 (Susan, 2005).

This encourages formation of phosphatic calculi, in addition to high magnesium diets and alkaline urine. It was also reported that with a high concentrate ration, the amount of colloids (mucoproteins and glycoproteins) in the urine is increased (Jorgensen and King, 1968). It is thought that these colloids serve as a matrix upon which the phosphates and carbonates may crystallize. Heavy concentrate – low roughage diets, limited intake or deprivation of water, dehydration, urine alkalinity, mineralized artesian water, alkaline water supplies, excess of sodium bicarbonate in diet, vitamin imbalance and high proteins ration are among the numerous factors in the development of urinary calculi (Makhdoomi and Gazi, 2013). Phosphorus is recycled through saliva and excreted through faeces in ruminants (Susan, 2005). Therefore, low roughage diet and high grain decrease the rate of formation of saliva and subsequently increase the amount of phosphorus excreted in the urine (Susan, 2005). Vitamin A plays a role in maintenance of healthy epithelium, which is deficient in high concentrate rations, therefore, desquamated epithelial cells could serve as a nidus for the formation of calculi (Jorgensen and King, 1968). Animals on high grain ration often show up to a 60% decrease in urine output with a corresponding decrease in water intake. As a result, their urine is much more concentrated and crystallization of the minerals present is more likely to occur (Jorgensen and King, 1968). Treatment of urolithiasis is basically establishing normal urinary passage, which can be accomplished by various ways depending on the severity of the condition. Use of muscle relaxant, amputation of urethral process, urethrostomy and tube cystotomy are among techniques to establish patent urinary tract.

Use of urinary acidifiers (calculolytics) like ammonium chloride may be helpful at early stage of the condition. Prevention of urolithiasis is of two basic principles; correction of mineral imbalance and ensuring adequate water intake so that urinary system is flushed regularly and thoroughly (Jorgensen and King, 1968). Increasing the calcium level in the diet of feedlot has markedly decrease the incidence of urolithiasis (Jorgensen and King, 1968). The ration should be modified, which includes elimination of alfa–alfa feeding, reduction or elimination of grain feeding, a change to grass hay as primary forage, encouragement of grazing and ammonium chloride supplementation (Jorgensen and King, 1968).

## RECOMMENDATIONS

Compositions of uroliths together with environmental and dietary factors should be considered when establishing adequate preventive measures for urolithiasis (Makhdoomi and Gazi, 2013). Therefore, it can be recommended that more work should be done on chemical analysis of the calculi found in animals and the chemical composition of the rangelands should be determined in areas where urolithiasis have been reported and other areas that is to be used for such purpose.

## ACKNOWLEDGEMENTS

The efforts of Dr. P.M. Ejikeme of Department of Pure and Industrial Chemistry, University of Nigeria, Nsukka for the analysis of the calculi and Mr. Mustafa Ibiobio of Department of Veterinary Anatomy, Usmanu Danfodiyo University, Sokoto for the processing of the histopathology sections are hereby acknowledged.

## REFERENCES

- Jorgensen J. and King R. (1968). Urolithiasis in Sheep. *Iowa State University Veterinarian*. Available at [http://lib.dr.iastate.edu/iowastate\\_veterinarian/vol30/iss2/2](http://lib.dr.iastate.edu/iowastate_veterinarian/vol30/iss2/2), accessed on 10/12/2015 by 9.00AM
- Kahn C.M. and Line S. (2010). The Merck Veterinary Manual (10<sup>th</sup> ed.). Merck and Co., Inc, Whitehouse Station, N.J., USA, p. 1389
- Kumar N., Singh P., and Kumar S., (2006). Physical, X – Ray Diffraction and Scanning Microscopic Studies of Uroliths. *Indian Journal of Biochemistry & Biophysics*, **43**, 226–232
- Lohdip Y.N., Ramyil V.M., and Gongden, J.J., (2008). Chemical Analysis of Urinary Calculi (Kidney Stones) Obtained from Patients Admitted at Jos University Teaching Hospital. *African Journal of Natural Science*, **11** 43–47
- Machado D.B., Sato I.M., Silva F.R.O., Salvador, V.L.R., Marumo J.T., and Schor N., (2014). Elemental Composition and Microstructure Analysis of a Rabbit Urolith. *Journal of Radioanalytical & Nuclear Chemistry*, **302**, 97-102
- Makhdoomi D.M. and Gazi M.A., (2013). Obstructive Urolithiasis in Ruminants – A Review. *Veterinary World*, **6** (4), 233-238
- Smith J.A. Divers T.J. and Lamp T.N. (1989). Ruptured Urinary Bladder in a Post- Parturient Cow. *Cornell Veterinarian*, **73**, 3-12
- Susan S. (2005). <http://www.sheepandgoat.com/#!urin-calc/c23i0>, accessed on 10/12/2015 by 9:15AM.
- Winter R.B. Hawkins, L.L. Holterman D.E. and Jones S.G. (1987). Catheterization- An Effective Method of Treating Bovine Urethral Calculi. *Veterinary Medicine*, **82**, 1261- 1266