

LIVER PATHOLOGY OF THE AFRICAN CATFISH, *Clarias gariepinus* INFECTED WITH *Euclinostomum clarias* METACERCARIAE IN ANAMBRA RIVER BASIN, NIGERIA

ONUOHA, Edwin Onyeodiri

Department of Zoology, University of Nigeria, Nsukka, Enugu State, Nigeria.

Email: oonuohaunn@yahoo.com Phone: +234 8037530633

ABSTRACT

The liver pathology of Clarias gariepinus infected with Euclinostomum clarias metacercariae in Anambra river basin was investigated from January to September, 2002. The clariids were examined and the livers of those infected with the metacercariae of the digenean trematode, Euclinostomum clarias, were fixed in 10% formal-saline, paraffin processed, sectioned and stained with haematoxylin and eosin. Infected liver showed massive pathological lesions ranging from hepatic degeneration, extravasations of bilirubin, necrosis, fibrosis, inflammatory reactions to proliferation of bile duct around the hepatic triad. These tissue reactions and damage were more prominent around and along the areas where the larvae localized or migrated. The liver of the uninfected fish did not show the lesions and damage which reduced the productivity and market price of the infected fish.

Keywords: African catfish, *Euclinostomum clarias*, Liver, Lesions, River basin

INTRODUCTION

Clarias gariepinus and other *Clarias* species have considerable economic importance. They are excellent sources of digestible protein and contain essential minerals, vitamins and fats. Fish is one of the keys to successful meal planning. It is a boom to the budget of United States and in these days of quick freezing, refrigeration and fast transportation, it is easy to get and easy to prepare (Ashbrook, 1955; Assiah *et al.*, 1996). Efficient fishery management should aim not only at maximizing yield but also ensuring acceptability of the product by consumers.

Various helminth species affect fish yield, spoil the quality of the fish or render them aesthetically unacceptable. Thus, the control of parasites should be looked upon as a major aspect of management of river basin and flood plain fisheries.

In Otuocha, a major river port in the Anambra River Basin, Ezenwaji and Ilozumba (1992) reported that *Euclinostomum clarias* metacercariae infect *Clarias* species, including *C.*

gariepinus and that fish infected with 28 or more metacercariae had their viscera almost completely covered by the parasite. And on such occasions the metacercariae were either embedded in or attached to the liver making it look a pale yellowish-red. The liver in such *Clarias* species appeared diseased and the fish looked emaciated.

No detailed pathologic studies (gross and histologic) of the changes in the liver, or any of the visceral organs, infected with *E. clarias* have been undertaken. The pathology associated with the infection of the liver need to be studied to have a basis for the effective treatment and control of the infection. This requires detailed histologic and histochemical studies of the infected liver.

The objective of this study was to determine the pathologic effect of infection by *Euclinostomum clarias* on the liver of *Clarias gariepinus*. Information on the occurrence of diseases in *Clarias*, an economically important species, were based mainly on gross disease conditions, hence the need for the study of

histopathological changes in the fish species arising from infection with *E. clarias*.

MATERIALS AND METHODS

Thirty-one *Clarias gariepinus* were collected from Otuocha, a river port in Anambra river basin. Collections were made by purchasing the clariids randomly from the fisher or fish retailers. The fish were transported to the Department of Zoology Post Graduate Laboratory, Nsukka in a jerry can containing sufficient water with a vent on top to allow air to enter.

In the laboratory they were gross examined before dissection. After dissection of *C. gariepinus*, the identified metacercariae of *Euclinostomum clarias* were placed in normal saline making them to wriggle out of their cocoon. The metacercariae were found attached on the liver of infected clariids within the peritoneum.

The liver part infected was cut out and placed in 10% formal-saline fixative immediately. After 24 to 48 hours, the liver was paraffin processed. Uninfected liver of *C. gariepinus* was used as the control.

After fixation, the liver sections of infected *C. gariepinus* and the control were trimmed 4 to 5mm thick with sharp scalpel blade and packed into tissue baskets.

Dehydration in ascending grades of ethanol started with 70% ethanol was carried out. One and half hours in each grade was used. The tissues were cleared overnight in chloroform. Two changes of paraffin wax infiltration took 3 hours, 1½ hours in each molten paraffin wax bath. Thereafter the tissues were embedded in fresh molten paraffin wax. The embedded liver tissues of the fish infected and control were trimmed and sectioned with a sharp microtome knife using rotary microtome. The sections were cut to 5 micron thick. They were properly labeled and dried on a hot plate for 30 minutes or overnight.

Sections were deparaffinised in two changes of xylene, hydrated in descending grades of ethanol and stained with haematoxylin and eosin (HE). After staining, the sections were dehydrated in ascending grades

of ethanol, cleared in xylene and mounted in Canada balsam for microscopic examination and histopathologic studies (Drury and Wallington, 1976)

RESULTS

Of the 31 *Clarias gariepinus* (16 – 38 cm in length and 22 – 460 g weight) from the Anambra river basin examined, the liver of 2 (6.45%) were infected with *Euclinostomum clarias*. Of the two infected clariids one was small and the other big. The small clariid (22.0 cm, 22.0 g) with infected liver was weak and swam sluggishly. Its skin appeared rough. The movement of the big clariid (30 cm, 196 g) with infected liver was normal. The skin was moist, slimy and smooth. The clariids used as control (19 – 22.4 cm, 60 – 160 g) swam forcefully and rapidly. They had moist, slimy and smooth skins.

On gross postmortem examination of the carcasses of infected clariids *E. clarias* metacercariae were found on liver capsule. In the small infected clariids, the rough grayish capsule was firmly attached to the liver which had whitish spots, whereas in the big infected fish the capsule was loose and cloudy and the liver itself was yellowish with haemorrhagic spots. The capsule of the liver of the uninfected *Clarias* was glossy and lightly attached to the liver surface.

Histopathologic changes observed in the liver sections of the two infected *Clarias* were principally pan-lobular degeneration and necrosis of hepatocytes (Figure 1).

There was mild bile duct hyperplasia, and moderate to severe infiltration of the periductular spaces by mononuclear leucocytes (Figures 2 and 3). The liver showed widespread areas of hyperaemia and haemorrhages (Figure 4 and 5). Liver of the uninfected fishes presented normal histologic appearance of hepatic lobules and hepatocytes (Figure 6).

DISCUSSION

Euclinostomum clarias metacercariae was found in the *Clarias gariepinus* from Anambra river basin examined in this study. However, only 2

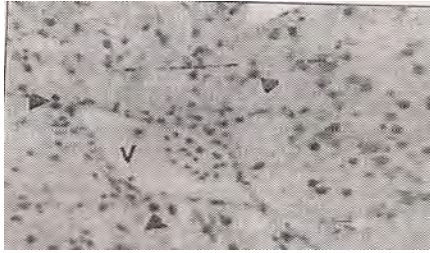


Figure 1: Liver section of small infected fish showing a central vein (v) surrounded by hepatocytes with clear cytoplasm and pyknotic nuclei (arrow head). H and E stain, x 320




Figure 4: liver section of *E. clarias* infected big fish showing area of hyperaemia in the sinusoids (arrow head). H and E stain, X 160.




Figure 2: Liver section of *Euclinostomum clarias* infected big fish showing mild hyperplasia of bile duct (arrow head) and hepatocytes with granular cytoplasm and pyknotic nuclei. H and E stain X 160

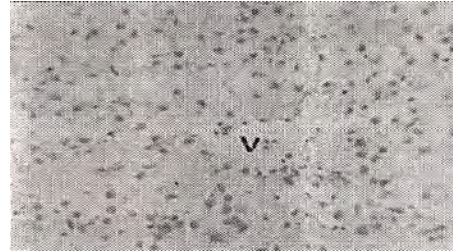


Figure 5: Liver section of infected big fish showing wide spread haemorrhages in the portal area. H and E stain, X 160

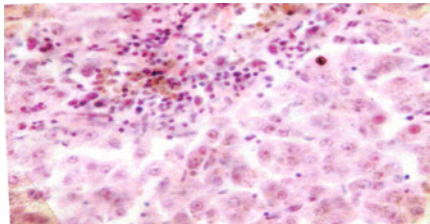


Figure 3: Liver section of *E. clarias* infected big fish showing mononuclear leucocyte aggregation in the periportal spaces. Bile pigment stained brownish. Stein's stain, X 320




Figure 6: Liver section of uninfected fish *C. gariepinus* showing a vein (V) surrounded by normal hepatocytes X 160

(6.45%) out of the 31 *Clarias gariepinus* examined were infected. The prevalence rate no doubt, is low when compared with the over 25% infection rate reported for an earlier study in the same ecosystem over a decade ago (Ezenwaji and Ilozumba, 1992). The remarkable difference in the prevalence rates from the two studies was probably a consequence of the periods of sample collection. The present study was carried out for three months (January, April

and September, 2002). The report of the earlier study cited above, indicated that sample collection was carried out all-year-round, for two consecutive years. In such situation, the influence of seasonal changes on the overall prevalence rate must have been eliminated. It is noteworthy that in the present study sampling during the months of January and April did not produce any *E. clarias* infected *Clarias*. The two cases observed were collected during the month

of September. This is in spite of the fact that the dry season (January-March) and early rainy season (April-June) were identified as the peak of infection in an earlier report (Ezenwaji and Ilozumba, 1992).

The gross and histologic changes in the liver of the small fish suggest an advanced (chronic) infection considering the fact that the liver serves metabolic functions and plays an important role in the overall well being of the fish (Ferguson, 1989). Clinical observations like weak sluggish movement and very low weight/SL ratio (1:100) for the small fish will most probably be a consequence of the chronic hepatic dysfunction in the fish.

In the big fish, biliary stasis in the liver was demonstrated by staining of liver sections with Stein's stain (Figure 3). The affected liver was yellowish, but there was no discoloration of skin which is in agreement with the report that jaundice is not a commonly observed clinical feature in the fish (Ferguson, 1989). The presence of bile in the sinusoids and hepatocytes in the peri-portal areas was not associated with widespread necrosis of hepatocytes in the area. Bile retention (Cholestasis) is usually a consequence of obstruction to the flow of bile, and is either intrahepatic or extrahepatic (Woolf *et al*, 2002). Bile is generally toxic and the retention is often associated with hepatocyte degeneration / necrosis and post - necrosis fibrosis (Walter and Israel, 1974).

The overall pathologic picture in the small infected fish is suggestive of an acute/subacute hepatitis in which there has been obstruction (intrahepatic or extrahepatic) to the flow of bile within the liver. The liver pathologic changes observed in the small infected and big infected fish were quite dissimilar, and so the pathogenesis of these lesions may be different. But no abnormal gross and histologic changes observed in *E. clarias* infected liver sections were encountered in the liver of the uninfected *clarias* examined. It may not be wrong to associate the liver pathologies in the small and big fish with *E. clarias* metacercariae infection even though sections of the parasites were not seen in histologic section of their liver.

This study has, confirmed the liver as one of the predilection sites for the metacercariae of *E. clarias* infected *Clarias*. Thus it may not be totally wrong to consider *E. clarias* a liver fluke in *Clarias gariepinus* based on the result of this study and that of others (Ezenwaji and Ilozumba, 1992).

The dissimilarity in the liver pathology of two infected *Clarias* examined in this study was an indication of pathological changes associated with degree of infestation of the liver of *Clarias* with the metacercariae of *E. clarias*. Gross and / or histologic changes should be expected in the liver of infected *Clarias*. Liver pathology may be severe enough as to reduce the overall productivity and economic value of infected fishes either in acute or chronic infections.

That the two infected *Clarias* were got in the month of September and not in January or April that were hitherto considered the climatic seasons of highest prevalence suggest that the situation presently in the Anambra river basin may be quite different from what it was ten years ago. There is therefore the need for studies that will provide current information on the parasitic infections of *Clarias* in the river basin, with special respect to the case of *E. clarias*. Such information is very desirable if an effective policy is to be formulated with regard to improving the overall productivity of *Clarias* in Anambra river basin.

The harsh / bitter economic situation now in Nigeria is increasingly forcing people to consume the 'small' *Clarias* even in the River basins. In this situation, the public health importance of *E. clarias* infection becomes relevant, since it had been speculated that in situation where the fishes are not properly cooked, the metacercariae can cause laryngopharyngitis in man as does other related trematodes like *C. complanatum*, because the domestic animal and man can be utilized as primary host (Ezenwaji and Ilozumba, 1992).

REFERENCES

- ASHBROOK, F. G. (1955). *Butchering, processing and preservation of meat. A manual for the farm and home.* Fish

- and Wild Life Services, United States. Department of the interior and Van Nostrand Reinhold Company, New York.
- ASSIAH, V. E., TON, V. S. and ALDIN H. (1996). *Small-Scale fresh water fish farming*. Agrodok Series Number 15. The African Caribbean and Pacific (ACP) States Technical Centres for Agricultural and Rural Cooperation (CTA). The Netherlands.
- DRURY, R. A. B. and WALLINGTON, E. A. (1976). *Carleton's Histological Technique*. 4th edition, Oxford University Press, London.
- EZENWAJI, H. M. G. and ILOZUMBA, P. C. O. (1992). Helminthofauna of four West African "small" *Clarias* species (Osteichthyes: Clariidae) from Nigeria. *Journal African Zoology*, 106: 391 – 400.
- FERGUSON, W. (1989). *Systemic Pathology of Fish. A Text and Atlas of Comparative Tissue Responses to Disease of Teleosts*. Iowa State University Press, Ames, Iowa.
- WALTER, J. B. and ISRAEL M. S. (1974). *General Pathology*. 4th edition, Churchill Livingstone, London.
- WOOLF, N., WOTHERSPOON, A. and YOUNG, M. (2002). The liver biliary system and exocrine pancreas. Pages 229 – 268. In: REGINALD, G. T. (Ed). *Essentials of Pathology*, Saunders, London.