

MORPHOLOGICAL FEATURES OF FETAL AND ADULT ADRENAL GLANDS IN KANO BROWN GOATS (*Capra hircus*)

NWAOGU, Innocent Chima and FRANCIS, Blessing

Department of Veterinary Anatomy, University of Nigeria, Nsukka, Enugu State, Nigeria

Corresponding Author: Nwaogu, I. C. Department of Veterinary Anatomy, University of Nigeria, Nsukka, Enugu State, Nigeria. **Email:** chimn2004@yahoo.com **Phone:** +234 8037147006

ABSTRACT

Gross and histomorphological features of fetal and adult adrenals obtained from slaughtered Kano brown goats at Obollo Afor and Nsukka abattoirs were studied. The specimens were divided into groups A – D for gestation day (GD) 86-102, 103-124, 125 – 146 and adults respectively. The mass of the adrenals increased significantly with age. Microscopically, GD 86 – 102 adrenals comprised outer capsule, definitive zone (DZ), fetal zone (FZ) and medulla. By GD 103 – 124 they exhibited transitional zone with less dense packed cells when compared with outer definitive zone. Full term adrenals had definitive cortex with zona granulosa at the early formative stage. The adult adrenals exhibited structures with typical zonation of the cortex. The width of DC increased while that of FZ decreased significantly ($P < 0.01$) with increasing age of the fetuses. These results suggest that the adrenals of Kano brown goats undergo morphological developmental changes similar to those of other animals.

Keywords: Adrenal gland, Adults, Fetuses, goats, *Capra hircus*, Morphology

INTRODUCTION

The adrenal gland is called the suprarenal gland because of its anatomical position above the kidney. They are often two in number, the right and left adrenal glands. It regulates many physiological functions both in fetal and postnatal life (Mecenas *et al.*, 1996; Smith *et al.*, 1998; Hill, 2007). In ruminants, the right adrenal gland is pyramidal and usually lies against the medial margin of the cranial extremity of the corresponding kidney while the left adrenal gland is less regular in shape and less constant in position (Dyce *et al.*, 2002).

The adrenal gland has two distinct functional units which are of different embryological origins; a mesodermal cortex and a neural crest ectoderm-derived medulla. A connective tissue capsule surrounds each gland. Comparative anatomical records reveal that the nephric origin of adrenocortical cells is a general feature of all vertebrates (Wrobel and Suss, 1999).

In fetuses of higher animals, the fetal cortex consists of three distinct layers viz the definitive zone (DZ), fetal zone (FZ) and transitional zone (TZ) (Lanmann, 1953). The DZ is a thin layer of tightly packed cells surrounding the FZ. The FZ accounts for 80 - 90% of the cortex and is the primary site of growth and steroidogenesis. During the second and third trimesters, a striking

enlargement of the FZ contributes to the growth of the adrenal cortex in humans (Mesiano and Jaffe 1997a, b). The TZ has irregularly distributed group of cells with reduced volume of cytoplasm. These small cells constitute a broad band lying between the glomerulosa and the outer FZ in full term *Macaca mulatta* fetuses (McNulty *et al.*, 1981). Projections of cords extending from DZ into the FZ indicate centripetal migration of DZ cells. The fetal adrenal cortex which later forms the adult adrenal cortex grows by cellular hypertrophy, hyperplasia, apoptosis and migration (Mesiano and Jaffe, 1997a; Spencer *et al.*, 1999).

The histology of adrenal gland varies with stage of development and the age of the fetuses. The development and histomorphology of adrenal glands have been studied in *Mus musculus* (Waring, 1935), *Tammar wallaby* (Call *et al.*, 1980), *Macaca mulatta* (McNulty *et al.*, 1981), *Sus scrofa* (Bielanska – Osuchowska, 1989), *Ovis aries* (Naaman and Durand, 1997), *Bos taurus* (Wrobel and Suss, 1999), *Papio species* (Leavitt *et al.*, 1999) and *Homo sapiens* (Spencer *et al.*, 1999; Sirianni *et al.*, 2005). There is dearth of information on the development of adrenal glands in *Capra hircus*.

This work was designed to study the gross and histomorphological features of adrenal glands in fetal and adult *Capra hircus* (Kano brown goats).

MATERIALS AND METHODS

Twenty-one fetal and twenty-one adult adrenal glands used for this study were collected from slaughtered Kano brown goats in Nsukka and Obollo-Affor abattoirs. The age of the fetuses was determined by crown-rump length method (Nwaogu and Ezeasor, 2008). The age of the adult goats was estimated using dentition (Chibuzo, 2006). The adrenal glands were dissected out immediately after slaughter. The samples were weighed and divided into four groups using specific age intervals viz: Groups A – C for gestation days (GD) 86-102, 103-124, 125-146 respectively and Group D – 1 to 2 year adults.

The glands were fixed in Bouin's fluid for 24 hrs. The fixed tissues were then dehydrated in a series of ascending ethanol concentration (70 %, 80 %, 90 % and 100 %), cleared in xylene, impregnated in liquid paraffin wax and embedded in paraffin blocks. Sections of 6µm thickness were cut using rotary microtome, dewaxed in xylene, hydrated in series of descending ethanol concentration, stained with haematoxylin and eosin and mounted on glass slides (Drury *et al.*, 1976). The slides were studied, photomicrographs prepared with digital camera (moticam 1000 1.3m pixel USB 2.0) attached to a microscope (Hund Wetzlar model) and images captured into a computer.

The width of the cortex, fetal and definitive zones was measured with stage and ocular micrometer gauge at x100 magnification. The data were analyzed statistically by ANOVA and Duncan's New multiple Range Test using SPSS for Windows version 12.0 (SPSS Inc. USA).

RESULTS

Gross Features: The adrenal glands were situated on the cranial pole of the kidneys in fetuses while in the adult goats they were located cranio-laterally to the kidneys. The adrenal gland was oval shaped in both fetuses and adults. The color varied from cream to red in fetuses but reddish-brown in the adults (Figure 1). There was a significant difference ($P < 0.01$) between the adult mean adrenal mass ($0.88 \pm 0.20\text{g}$) and those of the fetuses (Figure 2). The mean adrenal mass of the full term fetuses ($0.10 \pm 0.06\text{g}$) was significantly higher ($P < 0.01$) than those of GD 86 -102 ($0.02 \pm 0.01\text{g}$) and GD 103 – 124 ($0.08 \pm 0.04\text{g}$) fetuses.

Histological Features: The fetal adrenal glands comprised cortex and medulla. The cortex possessed two zones namely DZ near the capsule and inner FZ.

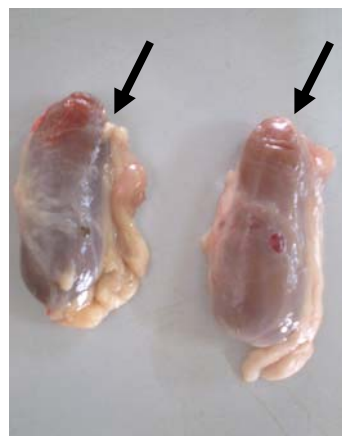

Figure 1: Gross photograph of adult adrenal glands (arrows)

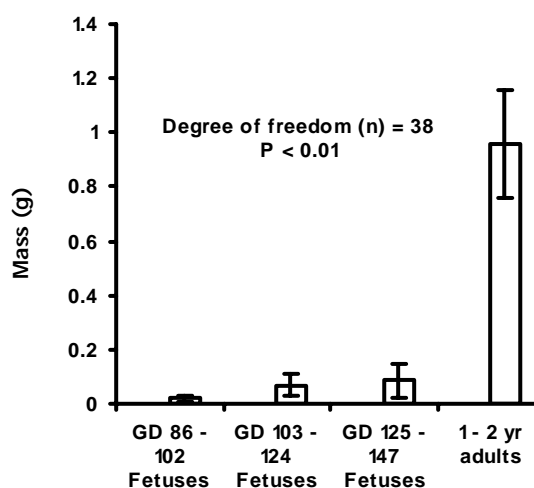


Figure 2: Comparison between adrenal gland mass of different age groups

The DZ comprised tightly packed basophilic cells while the FZ contained eosinophilic cells arranged as cords running towards the medulla at GD 124 (Figure 3). The DZ exhibited a glomerular pattern of cellular arrangement in full term fetuses. There were projections of DZ into the FZ (Figure 4). The TZ was also observed in the full term fetal adrenals.

The adult adrenal cortex comprised of three zones with the zona fasciculata as the largest zone. The zona glomerulosa cells were arranged in oval clusters while cells of the zona fasciculata were arranged in a cord-like pattern running towards the medulla (Figures 5 and 6). The cells of the zona reticularis were arranged in oval clusters (arrow head) and also as irregular network of cords (arrow) (Figure 7). The mean width of the adult definitive cortex ($1500.0 \pm 100.0\mu\text{m}$) was significantly ($P < 0.01$) higher than those of the fetuses ($40.0 \pm$

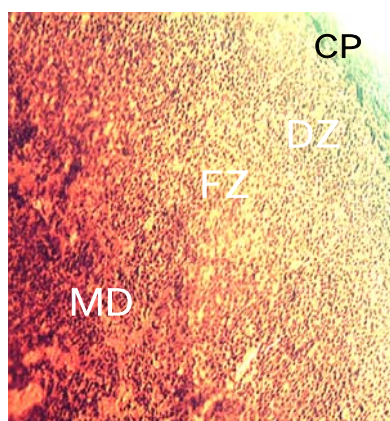


Figure 3: Section of GD 124 fetal adrenal gland showing capsule (CP), definitive zone (DZ), fetal zone (FZ) and medulla (MD). H & E. X200

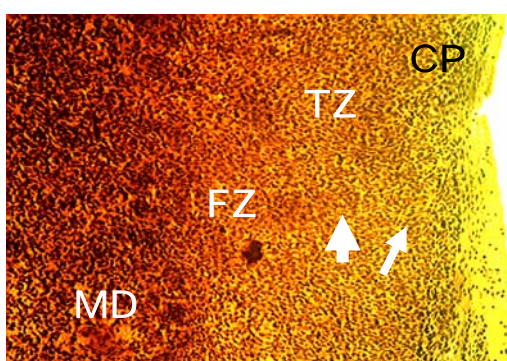


Figure 4: Section of full term adrenal gland showing capsule (CP), zona glomerulosa at formative stage (long arrow), transitional zone (TZ), projection of DZ (short arrow), into fetal zone (FZ) and medulla (MD). H and E. X 200

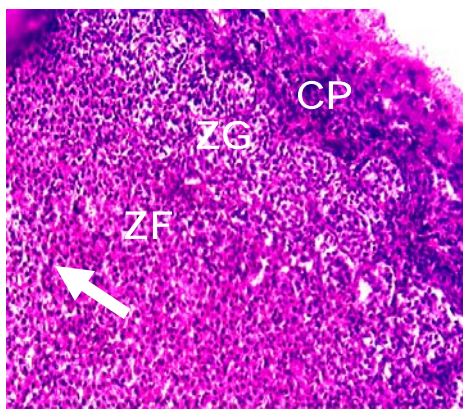


Figure 5: Section of adult adrenal cortex showing the capsule (CP), zona glomerulosa (ZG) and fasciculate (ZF) with cord – like arrangement of cells (arrow). H & E. X250

10.0 μ m, 80.0 \pm 15.4 μ m, 90.0 \pm 21.0 μ m). The FZ decreased significantly with fetal age (Figure 8).

DISCUSSION

This work provides baseline information on morphological features of adrenal glands in fetal and

adult Kano brown goats. The results of the present study indicate that the adrenal glands migrated away from the kidneys with age in Kano brown goats. The change in color from cream to red in fetuses and reddish brown in adults suggests increased blood supply to the organ. This is in agreement with the report that the adrenals are highly vascularized (Banks, 1993; Dyce *et al.*, 2002). The increase in adrenal mass from mid gestation to late gestation indicates growth. This agrees with the reports in *Macaca mulatta* (McNulty *et al.*, 1981) and man (Carr and Casey, 1982). However it is at variance with the report that fetal adrenals showed a decrease in growth rate over the final 20 days of gestation in baboon (Tame *et al.*, 1998). The changes in the adrenal mass could not be followed through neonatal period hence the neonatal adrenals were not studied.

The width of the definitive zone increased significantly with age while that of the fetal zone decreased with age. Similar observation has been reported in baboon (Leavitt *et al.*, 1999). The definitive zone in near term fetuses showed early formation of a glomerular pattern. This is supported by the report that at gestation day 130, bovine fetal adrenal gland exhibited zona glomerulo-fasciculata (Wrobel and Suss, 1999). The transitional zone observed in the adrenals of full term fetuses suggests that adrenal cortical zonation begins before birth in Kano brown goats. This corroborates with what was described as dense band in full term *M. mulatta* fetuses (McNulty *et al.*, 1981). The transitional zone according to Leavitt *et al.* (1995) is the developing zona fasciculata.

The projections of the definitive zone into the fetal zone as observed in this study are supported by the migration theory of the adrenal gland development (Mesiano and Jaffe, 1997a). This may explain why measurements of the width of the definitive and fetal zones taken at different cortical points gave different values. The combined width of the definitive cortex and the fetal zone is less than that of the adult adrenal cortex. This suggests that in addition to the migration theory of growth, this growth may also involve cellular hyperplasia.

The result of this study showed that the fetal zone was still present in full term fetal adrenal glands. Similar observations have been reported in *M. mulatta* (McNulty *et al.*, 1981) and baboon (Leavitt *et al.*, 1999). The maximum growth of the FZ might have occurred before gestation day 86 which is late second trimester in goats. It is the lowest age used in this work. This observation is supported by the report that human fetal adrenal cortex grows rapidly during the second and third trimesters (Spencer *et al.*, 1999).

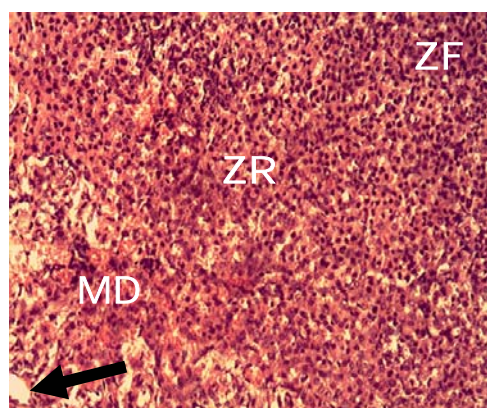


Figure 6: Section of adult adrenal gland showing part of zona fasciculata (ZF), zona reticularis (ZR), medulla (MD) and blood vessel (arrow). H & E. X250

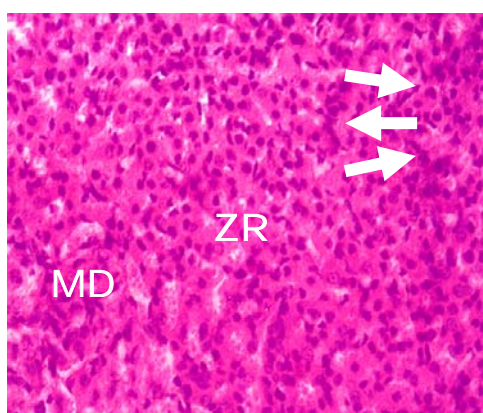


Figure 7: Section of adult adrenal gland showing zona reticularis (ZR) with cells arranged in oval clusters (short arrows), cords (long arrow) and medulla (MD) H & E X400

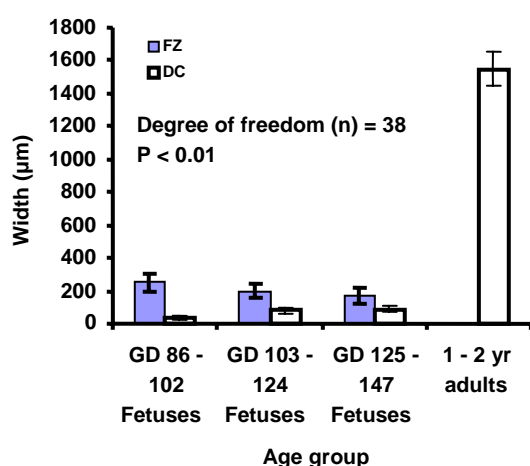


Figure 8: Comparison between width of fetal and definitive cortical zones of the age groups

The fetal zone was not observed in adult adrenal glands. The fetal zone existed through out gestation and the time for its disappearance was not identified. Probably it disappears during the neonatal period in

this species. The adult adrenal cortex comprised three zones viz, zona glomerulosa, zona fasciculata and zona reticularis. The zona glomerulosa contained clusters of cells. This is a characteristic morphological feature of adrenals in ruminants and man (Banks, 1993).

Conclusion: GD 86 – 102 adrenals comprised outer capsule, definitive zone (DZ), fetal zone (FZ) and medulla in Kano brown goats. By GD 103 – 124 they exhibited transitional zone. Full term adrenals had definitive cortex with zona granulosa at the formative stage. The adult adrenals exhibited structures with typical zonation of the cortex and medulla. The fetal adrenal mass and width of DZ increased significantly while FZ decreased with fetal age.

REFERENCES

- BANKS, W. J. (1993). Endocrine System. Pages: 408 – 428. *In: Applied Veterinary Histology*. 3rd Edition, Mosby Books Incorporated, USA.
- BIELANSKA-OSUCHOWSKA, Z. (1989). Prenatal development of the adrenals in pigs (*Sus scrofa* Dom) part 11: Adrenal cortex development in the second part of pregnancy. *Folia Morphologica*, 48(14): 29 – 58.
- CALL, R. N., CATLING, P. C. and JANSSENS, A. P. (1980). Development of the adrenal gland in the Tammar wallaby, *Macropus Eugenii* (Desmarest) (Marsupialia: Macropodiadae). *Australian Journal of Zoology*, 28(2): 249 – 259.
- CHIBUZO, G. A. (2006). The teeth. Pages 51 – 61. *In: Ruminant Dissection Guide: A Regional Approach in the Goats*. 2nd edition, Beth Bekka Academic Publishers, Maiduguri, Nigeria.
- CARR, B. R and CASEY, M. L. (1982). Growth of the adrenal gland of the normal human fetus during early gestation. *Early Human Development*, 6(2): 121 – 124.
- DRURY R. A. B., WALLINGTON, E. A. and SIR CAMERON, R. (1976). General staining procedures. *In: Carleton's Histological Technique*. Oxford University Press London.
- DYCE, K. M., SACK, W. O. and WENSING, C. J. B. (2002). The abdomen of ruminants. Pages 666 – 690. *In: KERSEY, R. and LEMELLEDO, D. (Editors). Textbook of Veterinary Anatomy*. 3rd Edition. W. B. Saunders Company, Philadelphia.
- HILL, M. (2007). Endocrine development – adrenal glands Pages 234 – 300. *In: Embryology*.

- University of New South Wales Publications, Sydney.
- LANMANN, J. T. (1953). Fetal zone of the adrenal gland, its developmental course, comparative anatomy, and possible physiological functions. *Medicine*, 32: 389 – 430.
- LEAVITT, M. G., ABERDEEN, G. W., BURCH, M. G., ALBRECHT, E. D. and PEPE, J. G. (1995). Inhibition of fetal adrenal adrenocorticotropin receptor messenger ribonucleic acid expression by betamethasone administration to the baboon fetus in late gestation. *Endocrinology*, 138: 2705 – 2712.
- LEAVITT, G. M., ALBRECHT, D. E. and PEPE, J. G. (1999). Development of the baboon fetal adrenal gland: Regulation of the ontogenesis of the definitive and transitional zones by adrenocorticotropin. *Journal of Clinical Endocrinology and Metabolism*, 84(10): 3831 – 3834.
- MCNULTY, P. W., NOVY, J. M. and WALSH, W. S. (1981). Fetal and postnatal development of the adrenal glands in *Macaca mulatta*. *Biology of Reproduction*, 25: 1079 – 1089.
- MECENAS, C. A., GUISSANI, D. A. and OWING, I. R. (1996). Production of premature delivery in pregnant rhesus monkeys by androstenedione infusion. *Nature and Medicine*, 2: 443 – 448.
- MESIANO, S. and JAFFE, R. B. (1997a). Developmental and functional biology of the primate fetal adrenal cortex. *Endocrinology Review*, 18(3): 378 – 403.
- MESIANO, S. and JAFFE, R. B. (1997b). Role of growth factors in developmental regulation of the human fetal adrenal cortex. *Steroids*, 62(1): 62 – 67.
- NAAMAN, R. E. and DURAND, P. R. (1997). The development of the ovine fetal adrenal gland and its regulation. *Reproduction Nutrition and Development*, 37(1): 81 – 95.
- NWAOGU, I. C. and EZEASOR, D. N. (2008). Studies on the development of the omasum West African dwarf goats (*Capra hircus*). *Veterinary Research Communication*, 32: 543 – 552.
- SIRIANNI, R., REHMAN, K. S., CARR, B. R., PARKER JR, C. R. and RAINEY, W. E. (2005). Corticotrophin releasing hormone directly stimulates cortisol and cortisol biosynthetic pathway in human fetal adrenal cells. *Journal of Clinical Endocrinology and Metabolism*, 90(1): 279 – 285.
- SMITH, R., MESIANO, S., CHAN, E. C., BROWN, S. and JAFFE, R. B. (1998). Corticotropin releasing hormone directly and preferentially stimulates dehydroepiandrosterone sulphate secretion by human fetal adrenal cortical cells. *Journal of Clinical Endocrinology and Metabolism*, 83: 2910 – 2920.
- SPENCER, J. S., MESIANO, S., LEE, Y. J. and JAFFE, R. B. (1999). Proliferation and apoptosis in the human adrenal cortex during the fetal and perinatal periods. Implications for growth and remodeling. *Journal of Clinical Endocrinology and Metabolism*, 84(3): 1110 – 1115.
- TAME, J. D., WINTER, J. A., LI, C., JENKINS, S., GUISSANI, D. and NATHANIELS, P. W. (1998). Fetal growth in baboon during the second half of pregnancy. *Journal of Medicine and Primatology*, 27(5): 234 – 239.
- WARING, H. (1935). The development of the adrenal gland of the mouse. *Quarterly Journal of Microscopic Sciences*, (78): 329 – 366.
- WROBEL, K. H. and SUSS, F. (1999). The origin and prenatal development of the bovine adrenal gland. *Anatomy and Embryology*, 199(4): 301 – 318.