

DIAGNOSIS OF NASAL MYIASIS IN THE WEST AFRICAN DWARF (WAD) SHEEP AT UMUDIKE, ABIA STATE, SOUTH-EASTERN NIGERIA

IKPEZE, Obiora Osegboka

Department of Parasitology and Entomology, Nnamdi Azikiwe University Awka, Nigeria

Email: ikpezevet@yahoo.com Phone: +234 8035838255

ABSTRACT

*A West African Dwarf (WAD) sheep with typical symptoms of nasal myiasis was procured on 9th December, 2008 by the Department of Microbiology and Parasitology at the College of Veterinary Medicine (CVM), Michael Okpara University of Agriculture Umudike (MOUUAU) in Abia State, south-eastern Nigeria for the purpose of teaching the subject, 'nasal myiasis', to para-clinical students of veterinary entomology. A sagittal section of the head of the suspected sheep was carried out for post mortem examination, whereupon two mature maggots, identified as the third stage larvae of the sheep nostril fly *Oestrus ovis*, were observed in the ventral meatus. The preserved specimens will help to expand the students' knowledge of the key identification features of the larva of *Oestrus ovis*, as well as the relative positions of the anatomical organs that may be affected by the developing larvae leading to pathological conditions which manifest as clinical symptoms of nasal myiasis in the sheep.*

Keywords: Sheep bot fly, *Oestrus ovis*, Nasal myiasis, Diagnosis

INTRODUCTION

The family Oestridae consists of several genera of large dipterous flies whose larvae are obligatory parasites of animals and man. Myiasis is the infection by these larvae (Roberts and Janovy, 2000) which are highly host specific and spend considerable time feeding and developing in their preferred hosts (Urquhart *et al.*, 2003). An example is the larvae of the nasal bot fly *Oestrus ovis*. The adult female fly, which does not lay eggs, is world-wide in distribution. Its larvae develop inside it and are deposited in the nostrils of sheep. The presence of the fly makes the sheep to bunch together with their heads lowered, with their nostrils close to the ground (Lapage, 1968) or protected between the bodies of other sheep. When the female fly darts at a sheep, causing it to raise its head, the fly immediately squirts a jet of liquid containing up to 25 larvae (Urquhart *et al.*, 2003) at the upturned nostril of the sheep. There are three developmental stages of the larva; the first stage larva is small, flat and white, but has a strong, sharply pointed horn-like mouth-hooks and long cephalo-pharyngeal skeleton. The second larva is long and cylindrical with a broad posterior end, and it attaches itself to the nasal mucosa with the strong mouth-hooks. The third stage is the matured larva which resembles the second, but is longer with brown bands on the dorsal aspect of the segments. Its dorsal surface is convex while the ventral side is flat and the larva tapers anteriorly while the posterior end is squared off. This implies that sheep may at any

time contain larvae in different stages of development in various sections of the nasal passages before they either crawl out or sneezed out of the sheep's nostrils to pupate on the ground. The dark brown pupa is found in the soil or under stones and tufts of foliage and lasts between 3 – 8 weeks before the adult emerges. The female adult fly survives for only two weeks, during which it can deposit up to 500 larvae in the nasal passages of the sheep (Urquhart *et al.*, 2003).

WAD sheep are commonly kept semi-intensively in Nigeria and are sometimes left to stray on public grounds constituting nuisance and danger to public health (Ikpeze, 2005). Adult fly causes annoyance which makes the sheep restless, interrupting their feeding which may lead to loss of condition (Thomton and Gracey, 1976). The larvae of *Oestrus ovis*, which is deposited on the nostril of the sheep, attach to the mucus membranes of the nasal passages where they cause irritation and inflammatory reactions resulting in the development of sticky muco-purulent nasal exudates. The irritation causes the affected sheep to frequently sneeze and shake their heads. Affected sheep may grate their teeth, rub their nose on fixed objects, move in circles with unsteady gait, and cease to eat properly. The larvae, by their activities, may also erode the bones of the skull to enter the brain (Lapage, 1968) where they may die in the sinuses causing secondary bacterial infection. Urquhart *et al.* (2003) observed that man could be occasionally infected if *Oestrus ovis* deposits larvae near the eyes, leading to

catarrhal conjunctivitis, but such larvae will never fully develop.

Diagnosis of nasal myiasis in sheep is often based on clinical signs and when the animal is observed to sneeze out the larva. Looking for larvae in the nasal and cranial cavity of the sheep is regarded as a post-mortem (PM) curiosity, but finding the active larvae in the nasal passages of the sheep is the confirmatory diagnosis of nasal myiasis. PM examination of the head of suspected sheep is not usually conducted because clients preferred to sell the affected animals or slaughter them for meat consumption. This situation will not afford para-clinical students of Veterinary Medicine the opportunity to carry out or witness the PM procedure for the examination of the head of sheep for the larvae of *Oestrus ovis*. This paper aims at doing this by using a typical case of 'Nasal Myiasis' to conduct PM, where the sagittal section of the head of the affected sheep was used to show the active larvae of *Oestrus ovis*. This paper will also help to expand the students' knowledge of the anatomical organs that may be affected by the migration of the developing larvae in the cranial cavity, leading to the pathological conditions that manifest as clinical symptoms of nasal myiasis in the sheep.

MATERIALS AND METHODS

Source of Animal: The WAD sheep with a typical symptoms of nasal myiasis, with a history of restless, muco-purulent nasal discharge, frequent head shaking, unsteady gait and improper feeding behaviour was procured on 9th December 2008, from a local market at Umuahia, for the purpose of Teaching and Research by the Department of Microbiology and Parasitology at the College of Veterinary Medicine (CVM), Michael Okpara University of Agriculture Umudike (MOUUAU), Abia State, south-eastern Nigeria, where the present researcher was serving as an Adjunct Lecturer in Veterinary Entomology.

Physical Examination: The sheep was inspected visually. There was evidence of purulent mucoid nasal discharge, emaciation, diarrhoea, head shaking, and walking in circles with unsteady gait. The muco-purulent nasal discharges were cleaned. Ectoparasites, recognized as hard ticks (Acarina: Ixodidae), were observed on the various body regions of the sheep. Based on the history and the symptoms manifested by the sheep, a tentative diagnosis of nasal myiasis was made.

Post-Mortem (PM) Examination of the Head of the Sheep and Identification of Larvae: A PM sagittal section of the head of the sheep was carried out (Sisson and Grossman, 1953) whereupon two mature active larvae, identified as the third stage larvae of the sheep nostril fly *Oestrus ovis*, were observed in the ventral meatus. Species identification was based on the location of the larvae, and comparison with the key identification features in the illustrations of Uquhart *et al.* (2003), Roberts and Janovy (2000) and Lapage (1967). Details of external structures used in successful species identification are presented in the results section of this paper. One of the recovered larvae was fixed and preserved in 70 % alcohol to which drops of 10 % glycerol was added to prevent drying out of the specimen if the alcohol evaporates. This, and the sagittal section of the sheep's head containing the other larva which was preserved in formalin, were deposited as voucher specimens in the Entomology Laboratory at MOUUAU.

RESULTS AND DISCUSSION

Result of PM examination of the sagittal section of the head of the sheep revealed two 3rd stage larvae of *Oestrus ovis* in the ventral meatus adjacent to the ventral turbinate (Figure 1 A). In these locations the larvae have produced catarrhal inflammation of nasal mucus membranes and the adjoining turbinate bones and meatuses (Figure 1 B). The external features of the third stage larvae in the sagittal section have been elaborated to show the key identification features of the species (Figure 2 A and B). The paper clearly shows that about twelve vital anatomical structures and organs in the naso-cranial cavity of the sheep (Figure 3) could be affected by the presence of the migrating and developing larvae of *Oestrus ovis*.

Confirmatory diagnosis of naso-pharyngeal myiasis in sheep, by looking for and finding active larvae of *Oestrus ovis* in the nasal cavity, is a PM curiosity which is however very useful in expanding the knowledge of the subject, allowing for proper species identification as has been demonstrated in this paper. Key identification features of the third larvae of *Oestrus ovis* are quite evident on the dorsal and ventral surfaces of the larvae (Figure 2 A and B). Rows of brownish spines visible on the ventral surface and the sharply pointed mandibular sclerites used by the larvae for attachment and feeding are responsible for much of the pathology seen in nasal myiasis. These actions cause irritation of the delicate mucus membranes of the nasal passages leading to inflammatory reactions and the associated symptoms




Figure 1: Sagittal section of the head of sheep. **A**, Larvae of *Oestrus ovis* in the ventral meatus; **B**, Larvae producing catarrhal inflammation of nasal mucus membranes and the adjoining turbinate bones and meatuses.

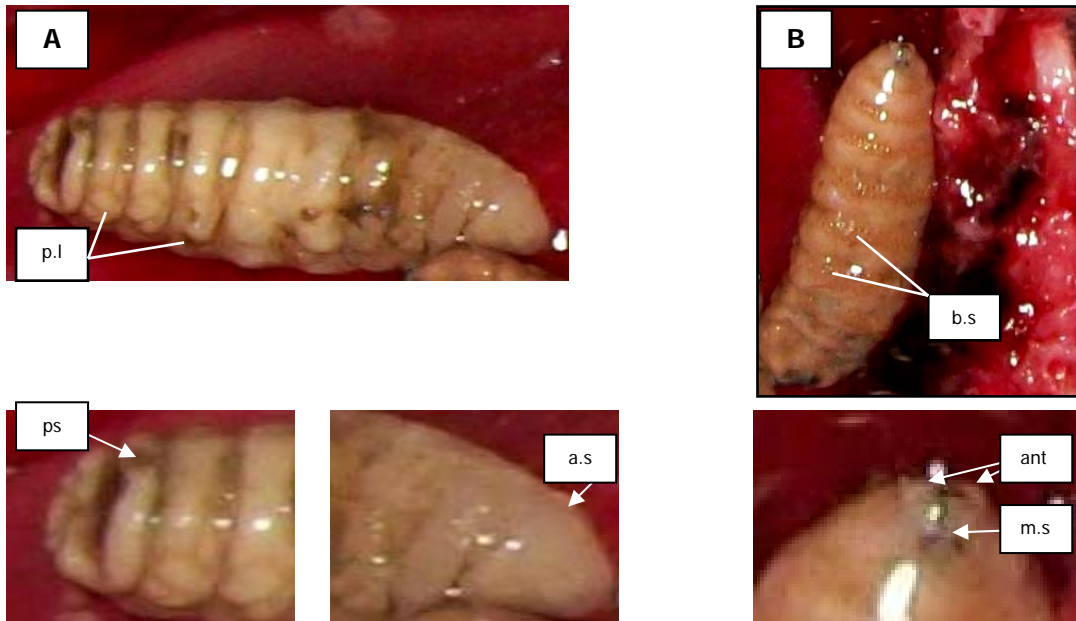


Figure 2: *Oestrus ovis* (Third stage larvae). **A**: Dorso-ventral view, **B**: Ventral view. Showing the eight segments and the prolegs (p.l.). Length of larva, 22mm, width, 7mm. The dorsal side is arched, the ventral side flat. Dorsal surface has no spines, but its ventral surface has several rows of brownish spines (b.s). There are fleshy lumps on the sides of the segments, especially on the posterior ones. Note, in A, the anterior spiracle (a.s) and the posterior spiracles (p.s); and, in B, two stumpy antennae (ant.), and the mandibular sclerites (m.s) which are sharply pointed and horn-like.

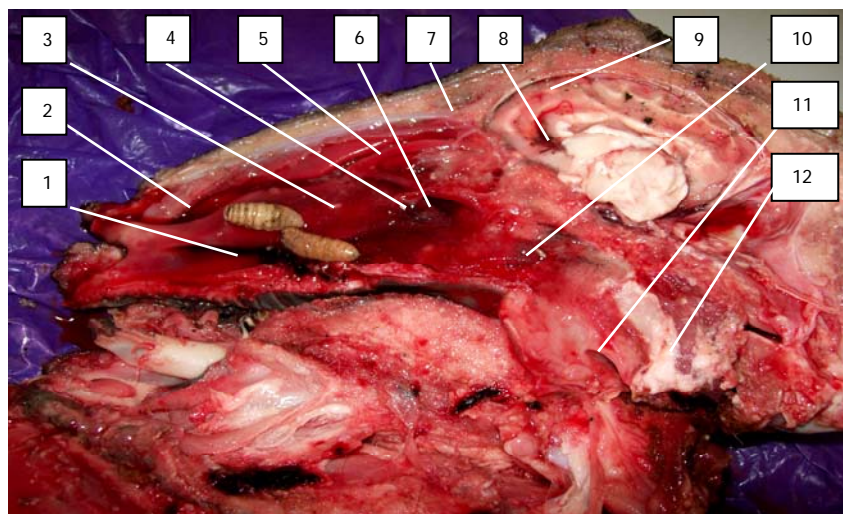


Figure 3: Sagittal section of the head of sheep. Showing anatomical structures likely to be affected by the presence of the developing larvae of *Oestrus ovis*. 1, Ventral meatus; 2, dorsal meatus; 3, ventral turbinate; 4, pre-sphenoid; 5, ethmo-turbinate; 6, Eustachian opening; 7, frontal sinus; 8, lateral ventricle; 9, cerebral hemisphere; 10, pharynx; 11, trachea; 12, oesophagus.

of muco-purulent nasal discharge, frequent sneezing, head shaking, walking with unsteady gait and improper feeding.

Figure 3 is very informative as nasal myiasis could affect not less than twelve anatomical structures and organs in the nasal and cranial cavities of the affected sheep. Smith *et al.* (1972) pointed out that growth and migration of larvae in these sites could result in serious damage to the tissues and can cause death. The sagittal section revealed that erosion of the ventral turbinate had taken place leading to haemorrhages observed in the ventral meatus. Haemorrhages observed between the cerebral hemisphere and the lateral ventricles of the brain suggested that damage had been done to brain tissue, and this may be responsible for cerebral involvement that manifested as symptoms of unsteady gait and walking in circles observed in the sheep. Other vulnerable organs include the openings of the Eustachian tubes, pharynx and trachea. Nevertheless, the successful larvae will eventually drop to the ground where they pupate before the adult flies emerge. In such circumstance, the affected sheep may recover spontaneously if there is no complication due to secondary bacterial infection or other pathological conditions like erosion of the turbinate bones and migration of larvae into the brain tissues.

Uitpeuloog or Bulging Eye Disease had been described as an oculo-vascular myiasis of domestic animals in South Africa (West, 1977), but other myiasis fly could as well be responsible for it. In man, especially shepherds, occasional infection will result if the bot fly *Oestrus ovis* deposits larvae near the eyes (Urquhart *et al.*, 2003) leading to catarrhal conjunctivitis, but with no further development of the larvae.

ACKNOWLEDGMENTS

I thank Professor S. N. Chiejina and my colleagues at the College of Veterinary Medicine, Michael Okpara

University of Agriculture Umudike for their cooperation during my stay as Adjunct Lecturer in Entomology, which made this work possible.

REFERENCES

- CAMERON, A. E (1943). *Oestrus ovis*. *Transactions of Royal Highland Agricultural Society of Scotland*, 55: 1 – 74.
- IKPEZE, O. O. (2005). Stratification and Livestock Population Census for Enugu Urban, Nigeria: A Pilot Survey. *Animal Research International*, 2(2): 332 – 335.
- LAPAGE, G. (1967). *Oestrus ovis*. In: *Veterinary Parasitology*, 2nd Edition. Oliver and Boyd, Edinburgh.
- ROBERTS, L. S. and JANOVY, J. (2000). Myiasis. In: GERALD D. SCHMIDT and LARRY, S. ROBERTS (Editors), *Foundations of Parasitology*, 6th Edition. McGraw-Hill Companies Incorporated, USA.
- SISSON, S. and GROSSMAN, J. D. (1953). Nasal cavity. In: *Anatomy of the Domestic Animals*, 4th Edition. W. B. Saunders Company. Philadelphia and London.
- SMITH, H. A., JONES, T. C. and HUNT, R. D. (1972). Myiasis. In: *Veterinary Pathology*, 4th Edition. Lea and Febiger, Philadelphia.
- THORNTON, H. and GRACEY, J. F. (1976). *The sheep nostrils fly*. In: *Textbook of Meat Hygiene*, 6th Edition. The Macmillan Publishing Companies Incorporated, New York.
- URQUHART, G. M., ARMOUR, J., DUNCAN, J. L., DUNN, A. M. and JENNINGS, F. W. (2003). *Veterinary Parasitology*, 2nd Edition. Book Power with Blackwell Science in co-operation with the British Council.
- WEST, G. P. (1977). Uitpeuloog. In: *Encyclopedia of Animal Care*, 12th Edition. The Williams and Wilkins Company, Baltimore.