

**CLINICAL CHEMISTRY AND HAEMATOLOGICAL ASSESSMENT OF QUAIL EGG-PRETREATED ACETAMINOPHEN-INDUCED HEPATOTOXICITY IN RATS**

<sup>1</sup>ABA, Patrick Emeka, <sup>2</sup>JOSHUA, Parker Elijah, <sup>2</sup>ONWUDINJO, Rex Chibuikem, <sup>1</sup>OMOJA, Valentine Unejo and <sup>3</sup>EZEASOR, Chukwunonso Kenekukwu

<sup>1</sup>Department of Veterinary Physiology and Pharmacology, Faculty of Veterinary Medicine, University of Nigeria, Nsukka, Nigeria.

<sup>2</sup>Department of Biochemistry, Faculty of Biological Sciences, University of Nigeria, Nsukka, Nigeria.

<sup>3</sup>Department of Veterinary Pathology and Microbiology, Faculty of Veterinary Medicine, University of Nigeria, Nsukka, Nigeria.

**Corresponding Author:** Aba, P. E. Department of Veterinary Physiology and Pharmacology, Faculty of Veterinary Medicine, University of Nigeria, Nsukka, Nigeria. **Email:** [patrick.aba@unn.edu.ng](mailto:patrick.aba@unn.edu.ng)  
**Phone:** +234 8062730072.

**ABSTRACT**

*This study investigated the possible hepatoprotective effect of quail egg solution on acetaminophen intoxicated rats. Thirty adult rats of mixed sexes were assigned into five groups of six per group. The rats in groups 2, 3, and 4 were pretreated with 30, 15, 7.5 mg/ml ad lib respectively of quail egg solution for 7 days before intoxication with 2000 mg/kg acetaminophen. Rats in group 5 were not pretreated but intoxicated with 2000 mg/kg acetaminophen (negative control) while the group 1 rats were neither pretreated nor intoxicated and served as positive control. Forty eight hours post induction, blood for some biochemical and haematological analysis was collected and the remaining rats treated until 14<sup>th</sup> day when the rats were humanely sacrificed and vital organs (liver and kidney) collected for histopathology. The results showed that the ALT activity of 30 mg/ml pretreated rats were significantly ( $p < 0.05$ ) lower than those of the negative control rats. Significant ( $p < 0.05$ ) increases were seen in the RBC, WBC, PCV and Hb levels of quail egg pretreated rats when compared with the negative control. However no significant ( $p > 0.05$ ) changes were seen in AST activity, MCHC and MCH levels of both the test groups and the controls. Histomorphometry examination revealed less severe vacuolar degenerative changes in the liver of 30 mg/ml pretreated rats when compared to the rats of other intoxicated groups. It was concluded that quail egg at the concentration of 30 mg/ml ameliorated hepatotoxicity and improved haematologic indices of acetaminophen-induced toxicity in rats.*

**Keywords:** Acetaminophen, Hepatotoxicity, Quail egg, Hematology, Histopathology, Liver enzymes

**INTRODUCTION**

Liver diseases are among the major problems in the globe today. Paracetamol<sup>®</sup> (acetaminophen), a widely used antipyretic and analgesic drug produces acute liver damage if frequently administered (Keffe and Friedman, 2004). Paracetamol toxicity has been reported to be the foremost cause of acute liver failure in the western world, and accounts for most drug overdoses in the United States, United Kingdom,

Australia and New Zealand (Hawkins *et al.*, 2007). The hepatotoxicity of paracetamol is as a result of formation of toxic metabolites when part of it is activated by hepatic cytochrome p-450 to a highly reactive metabolite, N-acetyl-p-benzoquinonimine (NAPQI) (Vermeulen *et al.*, 1992; Wallace, 2004)

The liver enzymes, alanine aminotransferase (ALT), aspartate aminotransferase (AST) are measures of liver homeostasis (Robert, 1999). The haematological

examination is among the methods which may contribute to the detection of some changes in health status, which may not be apparent during physical examination but which affect the fitness of the animals (Kronfeld and Medway, 1969). In spite of phenomenal growth of modern medicine, there are no synthetic drugs available for hepatic disorder. However, there are several herbs/herbal formulation claimed to possess beneficial activity in treating hepatic disorders (Ojo *et al.*, 2006).

The quail eggs are produced from small, short-tailed game birds of the family Phasianidae which resembles partridges but are generally smaller. The birds are found in chaparral, sagebush, oakwood lands and the northern east. Quail birds are common in Europe, Asia and some parts of Africa. The egg has an average weight of 10.13g, with the albumen, yolk and shell weighing 6.12g, 3.2g and 0.7g respectively (Anca *et al.*, 2008).

Quail eggs are slowly becoming an easy to get product on the market. More and more people are beginning to show interest in their use as an active natural medicine instead of the chemical product with so many side effects. Quail egg has been shown to be effective in the treatment and management of so many diseases (Tanasom *et al.*, 2013). This study is therefore tailored to evaluate the haematological, biochemical responses and the hepatic histomorphologic changes associated with quail egg pretreatment to acetaminophen-induced hepatotoxicity in rats.

## MATERIALS AND METHODS

**Animals:** Adult Wister albino rats of mixed sexes aged between 10 and 16 weeks with weight of 120-180 g were obtained from animal house of Faculty of Veterinary Medicine, University of Nigeria Nsukka. The animals were acclimatized for about 7 days under standard environmental condition, with a 12 hour light/dark cycle maintained on a regular feed (vital feed) and water *ad libitum*.

**Quail Egg:** Quail eggs used were obtained from the Faculty of Veterinary Medicine, University of

Nigeria, Nsukka Farm. The freshly laid eggs weigh between 10 – 15 g.

**Experimental Design:** Thirty adult male rats were assigned to five treatment groups replicated thrice with two rats per replicate. The groups include group 1 – pretreated with distilled water and no paracetamol intoxication (positive control), group 2 – pretreated with 30 mg/kg quail egg solution and 2000 mg/ml paracetamol, group 3 – pretreated with 15 mg/kg quail egg solution and 2000 mg/kg paracetamol, group 4 – pretreated with 7.5 mg/ml quail egg solution and 2000 mg/kg paracetamol and group 5 - pretreated with distilled water and 2000 mg/kg paracetamol (negative control). The rats were pretreated with aqueous solution of quail eggs of varying concentrations for seven days. On day 7, 2000 mg/kg of acetaminophen (paracetamol) was administered orally. Forty eight hours post acetaminophen administration, blood was collected from the rats for the determination of some haematological and biochemical parameters. Thereafter, 2 rats per group were humanly sacrificed and vital organs (liver and kidney) collected for histopathology. The remaining rats in different groups were administered with the quail egg solution *ad libitum* till day 14.

**Preparation of Quail Egg:** An empty beaker was weighed. The shells of the quail eggs were broken with spatula and the contents emptied into the beaker. The weight of the beaker and the content was recorded. The weight of the egg yolk and albumin was obtained by subtracting the weight of the beaker from the weight of the beaker and its contents. A stock solution of quail egg (weight : volume) was prepared using the weight of the egg and distilled water. Serial dilutions of the stock solution - 7.5, 15.0 and 30 mg/ml of quail egg were made for the different treatment groups.

**Induction of Liver Damage:** The dose of 2000 mg/kg of paracetamol (acetaminophen) was administered to the rats orally.

**Blood Collection:** Blood samples were collected from the animals using orbital techniques for clinical chemistry and haematological determination. Blood samples for clinical chemistry determination were collected from the retrobulbar plexus of the median canthus of the eye of the rats (Parasuraman *et al.*, 2010). A microcapillary tube was carefully inserted into the medial canthus of the eye to puncture the retrobulbar plexus and thus enable outflow of about 2 ml of blood into a clean glass tube. The blood was kept at room temperature for 30 minutes to clot. Afterwards, the test tubes containing the clotted blood sample were centrifuged at 3000 revolution per minute using a table centrifuge. The clear serum supernatant was then carefully aspirated with syringe and needle and stored in a clean sample bottle for the clinical chemistry determinations. Blood for haematologic determinations was collected with EDTA bottle.

**Determinations of Liver Biomarkers:** The serum aspartate aminotransferase and alanine aminotransferase activities were determined by the Reitman-Frankel colorimetric method for the *in-vitro* determination of AST in serum or plasma using AST test kit (QCA, Spain) (Reitman and Frankel, 1957).

### Haematological Determinations

**Packed cell volume:** The packed cell volume (PCV) was determined by the microhaematocrit method (Thrall and Weiser, 2002).

**Haemoglobin concentration:** The haemoglobin concentration (Hb) was determined by the cyanomethaemoglobin method (Higgins *et al.* 2008).

**Erythrocyte count:** The erythrocyte count was determined by the haemocytometer method (Thrall and Weiser, 2002).

**Total leukocyte count:** The total leukocyte count was determined by the haemocytometer method (Thrall and Weiser, 2002).

**Mean corpuscular values:** The mean corpuscular values – mean corpuscular volume (MCV), mean corpuscular haemoglobin (MCH), and mean corpuscular haemoglobin concentration (MCHC) were calculated using the standard formulae (Schalm *et al.*, 1975).

**Histomorphometric Examination:** The histological examination of the tissues of the liver and kidney of the rats were done using the method of Drury *et al.* (1967).

**Statistical Analysis:** The data generated was analyzed with one way analysis of variance (ANOVA) using SPSS version 20. P values less than 0.05 were accepted as significant. The results were presented in tables as mean  $\pm$  standard error of mean.

### RESULTS AND DISCUSSION

There was a significant ( $p < 0.05$ ) increase in WBC count of the rats in groups 2 and 3 when compared with the negative control (Table 1). There was concentration dependent reduction in RBC and WBC counts of acetaminophen induced hepatotoxicity in rats treated with graded concentrations of quail egg when compare to the normal group (Table 1). The effects of graded concentrations of quail egg on day 7 and 14 RBCs were similar in all treatments (Table 1). Vitamin B<sub>2</sub> (Riboflavin), Omega-3 and Omega-6-fatty acids contained in quail egg have been associated with boosting of erythropoiesis (Hillman *et al.*, 2005).

Packed cell volume and Hb levels of Groups 2 and 3 were statistically comparable ( $p > 0.05$ ) to that of the positive control on days 7 and 14 but were significantly ( $p < 0.05$ ) higher than those of the group 5 rats (Table 2). This could indicate that quail egg can improve the erythrocyte indices of paracetamol-intoxicated rats (Weiss and Goodnough, 2005).

One way analysis of variance did not reveal significant ( $p > 0.05$ ) changes in MCV, MCH and MCHC across all the groups (Table 3).

There was no significant ( $p > 0.05$ ) change in the activity of serum AST in the treated groups when compared with the

untreated paracetamol-intoxicated rats (Figure 1).

**Table 1: Effect of graded concentration of quail egg on red blood cell (RBC) and white blood cell (WBC) counts of acetaminophen induced hepatotoxicity in rats**

| Groups                                     | Day 7<br>RBC ( $\times 10^6$ cells/mm <sup>3</sup> ) | Day 14<br>RBC ( $\times 10^6$ cells/mm <sup>3</sup> ) |
|--|--|---|
| 1  | 6.81 $\pm$ 0.21 <sup>c</sup>                         | 7.03 $\pm$ 0.18 <sup>d</sup>                          |
| 2  | 6.20 $\pm$ 0.25 <sup>bc</sup>                        | 6.60 $\pm$ 0.25 <sup>cd</sup>                         |
| 3  | 5.85 $\pm$ 0.44 <sup>bc</sup>                        | 6.23 $\pm$ 0.27 <sup>c</sup>                          |
| 4  | 4.29 $\pm$ 0.35 <sup>b</sup>                         | 4.96 $\pm$ 0.33 <sup>b</sup>                          |
| 5  | 5.72 $\pm$ 0.25 <sup>a</sup>                         | 3.73 $\pm$ 0.12 <sup>a</sup>                          |
| WBC ( $\times 10^3$ cell/mm <sup>3</sup> ) |  |   |
| 1  | 9.720.14 <sup>c</sup>                                | 9.650.15 <sup>b</sup>                                 |
| 2  | 9.270.16 <sup>c</sup>                                | 9.450.18 <sup>b</sup>                                 |
| 3  | 9.580.93 <sup>c</sup>                                | 8.480.49 <sup>b</sup>                                 |
| 4  | 6.500.17 <sup>b</sup>                                | 5.270.71 <sup>b</sup>                                 |
| 5  | 5.470.29 <sup>a</sup>                                | 5.27071 <sup>a</sup>                                  |

Similar letter superscript across each column indicates not significantly different means ( $p > 0.05$ ). Different letter superscript across each column indicates significantly different means ( $p < 0.05$ )

**Table 2: Effect of graded concentration of quail egg on packed cell volume (PCV) and haemoglobin concentration of acetaminophen induced hepatotoxicity in rats**

| Groups    | Day 7<br>PCV (%)               | Day 14<br>PCV (%)             |
|-----------|--------------------------------|-------------------------------|
| 1         | 44.67 $\pm$ 0.88 <sup>b</sup>  | 45.00 $\pm$ 0.58 <sup>b</sup> |
| 2         | 42.00 $\pm$ 2.08 <sup>b</sup>  | 43.67 $\pm$ 2.84 <sup>b</sup> |
| 3         | 40.00 $\pm$ 0.58 <sup>ab</sup> | 43.00 $\pm$ 0.58 <sup>b</sup> |
| 4         | 36.00 $\pm$ 1.73 <sup>a</sup>  | 40.00 $\pm$ 2.52 <sup>b</sup> |
| 5         | 34.67 $\pm$ 2.40 <sup>a</sup>  | 32.00 $\pm$ 3.05 <sup>a</sup> |
| Hb (g/dl) |                                |                               |
| 1         | 14.73 $\pm$ 0.37 <sup>b</sup>  | 15.20 $\pm$ 0.11 <sup>b</sup> |
| 2         | 14.23 $\pm$ 0.43 <sup>b</sup>  | 14.40 $\pm$ 0.70 <sup>b</sup> |
| 3         | 13.40 $\pm$ 0.31 <sup>ab</sup> | 14.80 $\pm$ 0.31 <sup>b</sup> |
| 4         | 12.17 $\pm$ 0.44 <sup>a</sup>  | 13.67 $\pm$ 0.73 <sup>b</sup> |
| 5         | 12.13 $\pm$ 0.88 <sup>a</sup>  | 10.50 $\pm$ 0.76 <sup>a</sup> |

Similar letter superscript across each column indicates not significantly different means ( $p > 0.05$ ). Different letter superscript across each column indicates significantly different means ( $p < 0.05$ )

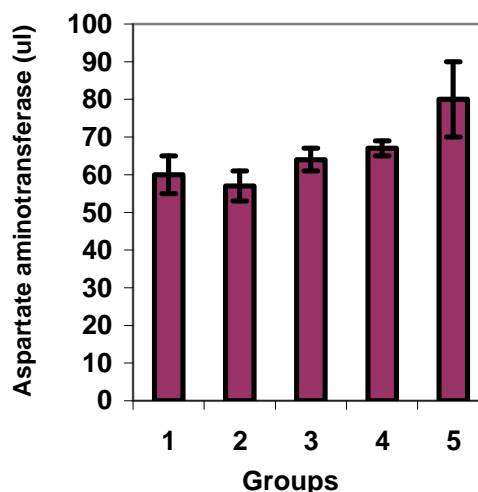
Results showed that there was no significant ( $p < 0.05$ ) change in the level of serum aspartate aminotransferase (AST) activity of rats in different test groups when compare to the normal group. Results showed that there was significant ( $p > 0.05$ ) increase in serum alanine aminotransferase activity of rats in different test

groups compared with serum alanine aminotranferase activity of rats that were not pretreated (group 5 negative control).

**Table 3: Effect of graded concentration of quail egg on mean corpuscular volume (MCV), mean corpuscular haemoglobin concentration (MCHC) and mean corpuscular haemoglobin of acetaminophen induced hepatotoxicity in rats**

| Groups      | Day 7<br>MCV (fl)             | Day 14<br>MCV (fl)            |
|-------------|-------------------------------|-------------------------------|
| 1           | 65.33 $\pm$ 1.86              | 63.67 $\pm$ 1.20              |
| 2           | 68.33 $\pm$ 5.69              | 64.67 $\pm$ 6.06              |
| 3           | 69.00 $\pm$ 5.51              | 69.33 $\pm$ 2.60              |
| 4           | 81.33 $\pm$ 8.41              | 65.67 $\pm$ 1.45              |
| 5           | 85.33 $\pm$ 6.93              | 82.33 $\pm$ 11.20             |
| MCHC (g/dl) |                               |                               |
| 1           | 32.70 $\pm$ 0.15 <sup>a</sup> | 33.33 $\pm$ 0.43 <sup>a</sup> |
| 2           | 33.33 $\pm$ 0.47 <sup>a</sup> | 32.90 $\pm$ 0.68 <sup>a</sup> |
| 3           | 35.97 $\pm$ 3.08 <sup>a</sup> | 33.30 $\pm$ 0.46 <sup>a</sup> |
| 4           | 33.50 $\pm$ 0.60 <sup>a</sup> | 33.00 $\pm$ 0.60 <sup>a</sup> |
| 5           | 33.27 $\pm$ 0.55 <sup>a</sup> | 32.30 $\pm$ 0.53 <sup>a</sup> |
| MCH (pg)    |                               |                               |
| 1           | 21.67 $\pm$ 0.67              | 21.00 $\pm$ 0.58              |
| 2           | 22.67 $\pm$ 1.86              | 20.67 $\pm$ 1.45              |
| 3           | 22.67 $\pm$ 1.86              | 23.00 $\pm$ 0.58              |
| 4           | 21.67 $\pm$ 0.33              | 27.00 $\pm$ 3.21              |
| 5           | 27.67 $\pm$ 3.93              | 27.67 $\pm$ 2.03              |

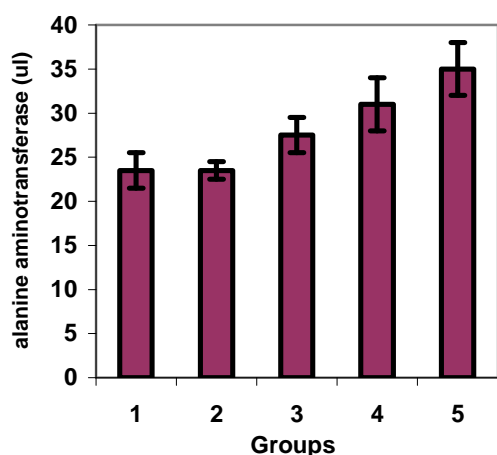
Similar letter superscript across each column indicates not significantly different means ( $p > 0.05$ ). Different letter superscript across each column indicates significantly different means ( $p < 0.05$ )



**Figure 1: Effects of quail egg pretreatment on aspartate aminotransferase of acetaminophen-induced hepatotoxicity in rats**

Group 2 rats showed significant ( $p < 0.05$ ) reduction when compared to groups 3, 4, and 5 rats. Furthermore, the results for the liver

enzymes showed that there was significant ( $p > 0.05$ ) increase in serum alanine aminotransferase in rats from the different test groups compared with serum alanine aminotransferase activity of rats that were not pretreated (group 5 negative control). Group 2 rats showed significant ( $p < 0.05$ ) reduction in ALT when compared to groups 3, 4 and 5 rats. Aspartate aminotransferase unlike ALT is not known to be a specific marker for liver damage (Nyblom *et al.*, 2006). ALT activities in group 5 rats were significantly ( $p < 0.05$ ) higher when compared with those of the quail egg-pretreated rats (Figure 2).



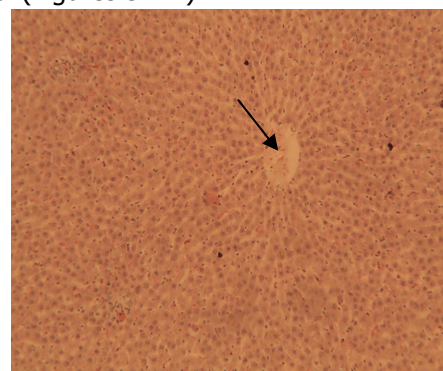
**Figure 2: Effects of quail egg pretreatment on alanine aminotransferase of acetaminophen-induced hepatotoxicity in rats**

This could be attributed to the effect of paracetamol on the liver (Robles-Daiz, 2014). The ALT activities of the normal control rats and that of group 2 rats were statistically comparable ( $p > 0.05$ ). This implied that the 30 mg/ml quail egg pretreatment prevented excessive leakage of ALT into the circulation. Quail egg could have achieved this by the presence of omega-3-fatty acid which according to Korever and Klasing (1997) is associated with decrease in inflammatory response, improvement in growth rate, erythropoiesis and leucopoiesis and increase specific immunity. It could be also be as a result of Vitamin C, and B<sub>2</sub> contained in the quail eggs which are known to be hepatoprotective (Takate *et al.*, 2010).

The liver enzymes, alanine aminotransferase (ALT), aspartate

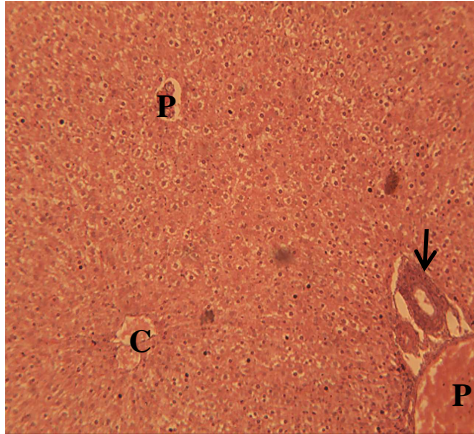
aminotransferase (AST) are measures of liver homeostasis (Robert, 1999). Serum aminotransferase (AST and ALT) are markers of hepatocellular injury (Nyblom *et al.*, 2006). The aminotransferases are sensitive indicators of liver cell injury and are most helpful in recognizing acute hepatocellular diseases. In most acute hepatocellular disorder, the ALT is higher than AST (Robert, 1999). Paracetamol is a commonly and widely used analgesic and antipyretic agent, but over doses of paracetamol depletes the normal levels of hepatic glutathione. Cytochrome P450 enzyme system metabolizes paracetamol and forms a minor but significant alkylating metabolite known as NAPQI (N-acetyl-p-benzoquinone imine), which in turn is irreversibly conjugated with the sulfhydry groups of glutathione (Jollow *et al.*, 1973). Production of NAPQI (responsible for the toxic effects of paracetamol) is mainly because of two isoenzymes of cytochrome P450 (CYP2E1 and CYP1A2). Excess production of paracetamol metabolite caused the initial hepatic damage and subsequent activation of inflammatory mediator TNF- $\alpha$ , which in turn contributed to tissue necrosis (Jollow *et al.*, 1973).

Histopathology results indicated that the quail eggs in the pre-treated groups had lesser vacuolar degeneration of their hepatocytes compared to the hepatocytes of the negative control (Figures 3 – 7).

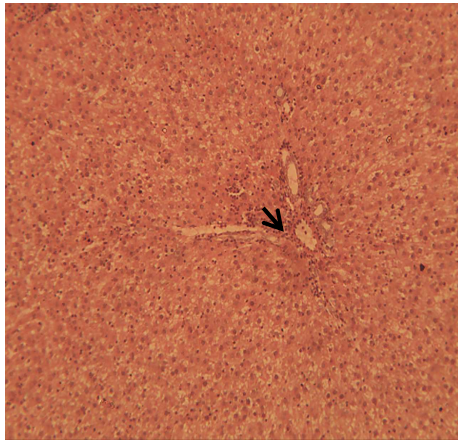


**Figure 3: Section of liver from group one rats showing normal hepatocytes arranged in cords. Central vein (arrow), H&E X100**

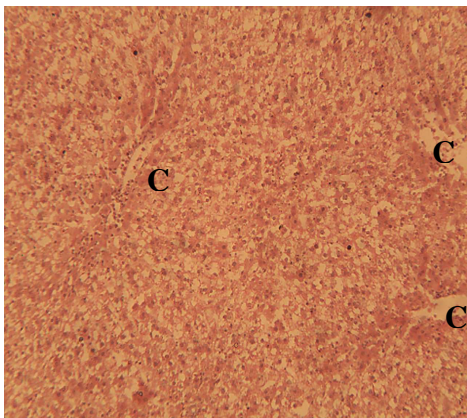
The hepatocytes of the group 2 rats (pretreated with 30 mg/ml of quail egg) had lesser damage compared to the hepatocytes of the other test groups.



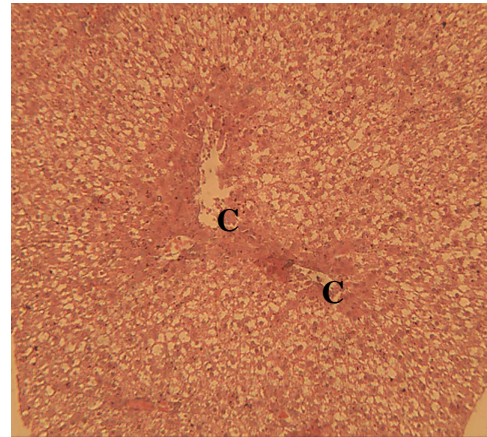
**Figure 4: Section of liver from group two rats showing moderate vacuolation of the hepatocytes. Central vein (C), portal area (P), bile duct (arrow), H&E X 00**



**Figure 5: Section of liver from group three rats showing severe diffuse vacuolar degeneration and a moderate periportal cellular infiltration (arrow), H&E X100**



**Figure 6: Section of liver from group four rats showing varying hepatocellular vacuolar degeneration. It tends to vary from moderate to severe, panlobular to midzonal and periportal, and random. Central vein (C), H&E X 100**



**Figure 7: Section of liver from group five rats showing varying hepatocellular vacuolar degeneration. However, the degenerative change tends to involve primarily the periportal and midzonal areas of the hepatic lobules. Note; the hepatocytes around the central vein appears normal. Central vein (C), H&E X 100**

This indicates that quail egg pretreatment at this concentration was able to mitigate injury to the hepatocytes. The samples collected from the kidney showed no histopathological lesion. The glomeruli, Bowman's capsule and renal tubules were normal in all groups. In conclusion, results of the study indicate that quail egg could be hepatoprotective and erythropoetic in acetaminophen-induced hepatotoxicity in rats

## REFERENCES

- ANCA, P., PRELIPCEAN, A. and TEUSAN, N. (2008). Investigation on the structure, chemical composition and calorificity of the quail eggs deposited at the plateau phase of laying period. *Journal of Poultry Science*, 3(15): 56 – 113.
- DRURY, R. A., WALLINGTON, A. and CAMEROUN, S. R. (1967). *Carleton's Histological Techniques*. Oxford University Press, New York.
- HAWKINS, L. C., EDWARDS, J. N. and DARGAN, P. I. (2007). Impact of restricting paracetamol pack sizes on paracetamol poisoning in the United Kingdom: A review of the literatures. *Drug Safety*, 30(6): 465 – 479.

- HIGGINS, T., BEUTLER, E. and DOUMAS, B. T. (2008). Measurement of haemoglobin in blood. Pages 514 – 515, *In: BURTIS C. A., ASHWOOD E. R. and BRUNS D. E. (Eds.), Tietz Fundamentals of Clinical Chemistry, 6<sup>th</sup> Edition, Saunders Elsevier, Missouri, USA.*
- HILLMAN, R. S., ALILT, K. A. and RINDER, H. M. (2005). *Hematology in Clinical Practice.* McGraw Hill, New York.
- JOLLOW, D. J., MITCHELL, J. R., POTTER, W. Z., DAVIS, D. C., GILLETTE, J. R. and BRODIE, B. B. (1973). Acetaminophen-induced hepatic necrosis: Role of covalent binding *in vivo*. *Journal of Pharmacology and Experimental Therapeutics*, 187(1): 195 – 202.
- KEFFE, E. B. and FRIEDMAN, L. M. (2004). *Hand Book of Liver Diseases.* Churchill Livingstone, Edinburgh, United Kingdom.
- KOREVER, D. R. and KLASSING, K. C. (1997). Dietary fish oil alters specific inflammatory immune responses in chicks. *Journal of Nutrition*, 127: 2039 – 2046.
- KRONFELD, D. S. and MEDWAY, W. (1969). Blood chemistry. *In: MEDWAY W., PRIER, J. E. and WILKINSON, J. S. Textbook of Veterinary Clinical Pathology, 12<sup>th</sup> Edition, Williams and Wilkins, Baltimore.*
- NYBLOM, H., BYORNSON, E., SIMREN, M., ALDENBORG, F., ALMER, S. and OLSSON, R. (2006). The AST/ALT ratio as indicator of cirrhosis in patients with PBC. *Liver International*, 26(7): 840 – 845.
- OJO, O. O., NADRO, M. S. and TELLA, I. O. (2006). Protection of rats by extracts of some common Nigeria trees against acetaminophen-induced hepatotoxicity. *African Journal of Biotechnology*, 5(9): 755 – 760.
- PARASURAMAN, S., RAVEENDRAN, R. and KESAVAN, R. (2010). Blood sample collection in small laboratory animals. *Journal of Pharmacology and Pharmacotherapy*, 1(2): 87 – 93.
- REITMAN, S. and FRANKEL, S. (1957). Colorimetric method for determination of serum transaminases. *American Journal of Clinical Pathology*, 28: 56 – 61.
- ROBERT, L. S. (1999) *Clinical Reference Laboratory.* Lenexa, USA.
- ROBLES-DAIZ, M. (2014). Use of Hy's law and a new composite algorithm to predict acute liver failure in patient with drug-induced liver injury. *Gastroenterology*, 147(1): 109 – 118.
- SCHALM, O. W., JAIN, N. C. and CAROL, E. J. (1975). *Veterinary Haematology.* 3<sup>rd</sup> Edition, Lea and Febringer, Philadelphia, USA.
- TAKATE, S. B., POKHARKAR, R. D., CHOPADE, VV. and GITE, V. N. (2010). Hepatoprotective activity of aqueous extract of *Launaea intybacea* (Jacq) Beauv against carbon tetrachloride-induced injury in albino rats. *Journal of Pharmaceutical Science and Technology*, 2(7): 247 – 251.
- TANASOM, T., WANNA, T. and WATTASIT, S. (2013). Nutrient benefits of quail (*Coturnix coturnix japonica*) eggs. *International Journal of Scientific Research and Publications*, 3(5): 1 – 8.
- THRALL, M. A. and WEISER, M. G. (2002). Haematology. Pages 29 – 74. *In: HENDRIX C. M. (Ed.) Laboratory Procedures for Veterinary Technicians, 4<sup>th</sup> Edition, Mosby Incorporated, Missouri, USA.*
- VERMEULEN, N. P. E., BESSEMS, J. G. M. and VAN DE STREAT, R. (1992). Molecular aspects of paracetamol-induced hepatotoxicity and its mechanism based prevention. *Drug Metabolism Review*, 24: 367 – 407.
- WALLACE, J. L. (2004). Acetaminophen hepatotoxicity; No to the rescue. *British Journal of Pharmacology*, 143(1): 1 – 2.
- WEISS, G. and GOODNOUGH, L. T. (2005). Anemia of chronic disease. *New England Journal of Medicine*, 325: 1011 – 1023.