

Aspiration of a perforated pen cap: complete tracheal obstruction without radiologic evidence

Federico G. Seifarth^a, Jason Triana^b and Colin G. Knight^c

Foreign body aspiration is a common but underestimated event in children with potentially fatal outcome. Because of unreliable histories and inconsistent clinical and radiologic findings, diagnosis and treatment can represent a challenge. Inhaled pen caps predispose for complete airway obstruction and are difficult to extract because of their smooth surface. We report a case of an aspirated perforated pen cap with normal radiologic findings and describe a safe and easy bronchoscopic extraction technique using a Fogarty arterial embolectomy catheter. *Ann Pediatr Surg* 8:22–24 © 2012 Annals of Pediatric Surgery.

Annals of Pediatric Surgery 2012, 8:22–24

Keywords: children, flexible bronchoscopy, Fogarty catheter, foreign body aspiration, pen cap, rigid bronchoscopy

^aDepartment of Pediatric Surgery, Cleveland Clinic Foundation, Cleveland, Ohio, ^bDepartment of Internal Medicine, Roger Williams Medical Center, Providence, Rhode Island and ^cDepartment of Pediatric Surgery, Miami Children's Hospital, Miami, Florida, USA

Correspondence to Federico G. Seifarth, MD, Department of Pediatric Surgery/A120, Cleveland Clinic Foundation, 9500 Euclid Avenue, Cleveland, OH 44195, USA
Tel: + 1216 445 7878; fax: + 1216 445 1035; e-mail: seifarf@ccf.org

Received 19 September 2011 accepted 23 November 2011

Introduction

Foreign body aspiration (FBA) is a common and potentially life-threatening event in children. In 2005, more than 19 000 North American children were treated in hospital emergency rooms for choking-related episodes [1]. In 2000, 160 children under 14 years of age died in the United States from airway obstruction associated with inhaled or ingested foreign bodies [2].

The majority of childhood choking-related injuries are associated with food items, including nuts, beans, hot dogs, candies, grapes, carrots, and popcorn [3,4]. Aspirated pen caps account for 3–8% of all non-food-related aspirations [5,6].

While drawing or studying, children tend to chew on pens, which predisposes them to ingest and aspirate loose pen caps or push buttons. The size and cylindrical shape of pen caps and roller pen buttons make them a highly hazardous cause of airway obstruction. Owing to their shape, their rigid material (plastic or metal), and smooth surface they represent a therapeutical challenge. Rigid bronchoscopy is the gold standard technique for foreign body removal [7–9]. However, bronchoscopy forceps may not provide a sufficient grip to extract the caps, and the diameter of the caps can complicate the passage of the vocal cords.

Case report

A written consent was obtained from the parents of the child for publication of this case report. A 9-year-old boy was seen at an outside hospital for upper respiratory tract symptoms after choking on a plastic pen cap. A FBA was suspected. The chest radiograph did not show any pathology and the patient was discharged home with supportive measures. He remained afebrile but the cough did not resolve. Within 1 week the boy developed constant wheezing. Fifteen days after his initial visit he was re-evaluated at the same hospital. The repeat chest radiograph again failed to show a foreign body or signs of pneumonia. Three days later, 18 days after the initial

choking event, he was referred to Miami Children's Hospital for a surgical consult.

At the time of presentation the patient was in no respiratory distress and experienced bilateral expiratory wheezes on auscultation. His vital signs were normal and his transcutaneous oxygen saturation was 98% on room air. Albuterol inhalations did not resolve the wheezing. The chest radiograph in inspiration and expiration showed normal findings with symmetric aeration and no air trapping or infiltrates.

The next morning, flexible and subsequently rigid bronchoscopy was performed with a Storz bronchoscope of size 5. We found a cylindrical plastic foreign body with central perforation occluding the trachea in supracarinal position. During inspiration, we noted temporary translocation into the right main stem bronchus with spontaneous 180° longitudinal rotation.

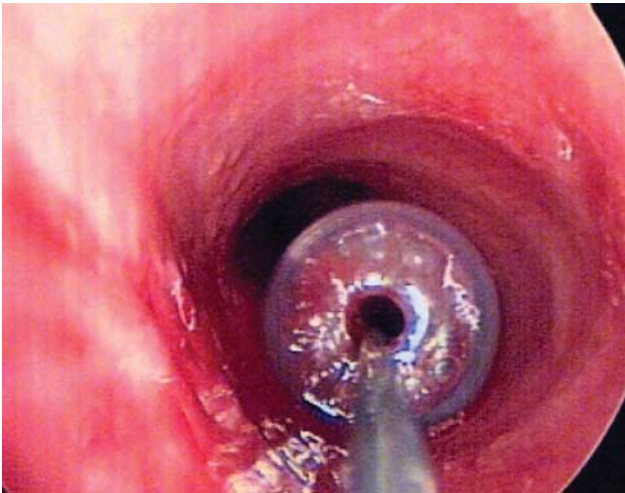
The foreign body grasper could not grasp the smooth plastic surface of the cap to extract it through the vocal cords. We introduced a 3-Fr Fogarty arterial embolectomy catheter through the rigid bronchoscopy working channel into the trachea. The catheter was passed through the central opening in the plastic cap's bottom. Inflation of the distal balloon allowed controlled extraction of the cap past the vocal cords (Figs 1 and 2).

The patient received two postoperative doses of intravenous steroids and was discharged home on postoperative day 1 without respiratory symptoms and an unremarkable pulmonary auscultation.

Discussion

FBA can lead to life-threatening emergencies that require prompt bronchoscopy and foreign body removal. Patients with missed diagnosis and left airway foreign bodies are prone to develop recurrent infections and undergo a significantly increased risk of delayed foreign body removal [10].

Fig. 1



Pen cap, in extraction using a Fogarty catheter.

Fig. 2



Aspirated a perforated pen cap.

Over 80% of all FBAs occur in children younger than 5 years of age. In this patient group, the history is often unreliable and symptoms are inconsistent. Retrospective studies have shown that more than 90% of all cases present with at least one of the following signs of aspiration: initial choking, followed by wheezing, cough, or stridor [8,9]. The sensitivity of the initial chest radiograph is reported to be 62–68% [11,12]. Absence of breath sounds present in only 30–60% of affected children and is suggestive of complete airway obstruction [8]. Decreased breath sounds can be found in up to 80% [9].

According to a retrospective analysis of 1015 cases, delayed diagnosis was made in over 40% of all patients presenting with FBA. In 29% of patients the diagnosis was delayed by more than a week; in 10% it was delayed by more than 30 days [13].

The vast majority of all inhaled foreign bodies are of organic nature with predominance of food items like peanuts, beans, hot dogs, and vegetables [8,9].

Inhalations of plastic caps account for only 3–8% of all FBA cases [5,6,9]. In contrast to toddlers who are at highest risk for food FBA aspiration, primarily school children suffer from pen cap inhalation. They represent a diagnostic and therapeutic challenge. Most pen caps are made of smooth, radiolucent material. Their cylindrical or cone shape predisposes them for airway obstruction.

Recent studies showed promising results of computed tomography (CT) virtual bronchoscopy in diagnosing pediatric FBA. This modality was successfully applied in children and has a reported sensitivity of over 90% [14,15].

Our patient presented with a complete tracheal obstruction. The central perforation allowed passage of air and aeration of the more distal airways. The combination of radiolucent material with central opening made the direct or indirect detection of this foreign body impossible using a routine radiograph. The CT virtual bronchoscopy may have shortened the delay in diagnosis. Pen cap aspiration predominantly affects children of school age. In most cases, the children can accurately describe the incident, compared with cases of toddlers with FBA, in which the history may not be as reliable, if not witnessed by an adult. Considering the low sensitivity of chest radiographs and conventional CT scans, caregivers must trust the reports of young patients and develop a high index of suspicion in a child with respiratory symptoms and a personal history that might suggest FBA – even if the diagnostics remain negative. Our patient who reported choking on a plastic pen cap was 9 years old and therefore assumed to be a reliable historian. A higher confidence in his report would have shortened the time between onset of symptoms and the diagnostic and therapeutic bronchoscopy.

To date, the largest series of inhaled pen caps in children is the one published by Jiaqiang *et al.* [5] and involves 34 patients. The researchers acknowledged the difficulties of bronchoscopic removal. They were able to perform this procedure successfully in all patients using a pair of reverse grasping forceps. Most of the Chinese school children in this study were able to clearly describe the incident and the pen cap. In a series of 19 patients with inhaled pen caps, Ülkü *et al.* [16] were able to bronchoscopically remove the caps in only nine patients (48%). Five patients (26%) required an additional tracheostomy for the extraction and the remaining five patients (26%) underwent a thoracotomy for removal. They attribute the high need for tracheostomy and thoracotomy to the slippery surface of the caps and the diameter that renders an extraction through the vocal cords difficult. They did not apply the reverse grasping forceps as described by Jiaqiang and colleagues, which seems to allow a better grip on the smooth surface of cylindrical pen caps. Another important aspect mentioned by Jiaqiang *et al.* [5] is the usage of a bronchoscope with a larger diameter than the pen cap itself. This way,

the glottis will be extended and extraction through the vocal cords alleviated.

The unusual finding of a perforated foreign body as in our case presents a diagnostic challenge; however, it allows removal by application of a Fogarty catheter. The catheter is inserted into the airway through the working channel of the rigid bronchoscope. Under direct vision, the tip of the catheter is passed through the perforation. After inflation of the Fogarty balloon the foreign body can be easily removed with safe passage of the vocal cords in a controlled manner.

In the last two decades, flexible bronchoscopy has been shown to be a useful alternative to rigid bronchoscopy for aspirated foreign body removal in children. Its use was initially limited because of the lack of adequate working channels and satisfactory ancillary extraction instruments. In a recent study including 1027 flexible bronchoscopies in children, a total of seven pen caps were successfully extracted [17].

Most foreign bodies enter the right bronchial tree because of its steeper angle and slightly larger caliber compared with the left side. In contrast to adults, in children, left-sided FBA is very common because of the anatomical variability of the carina [18]. Our patient displayed a floating foreign body between the right main stem bronchus and the carina with inhalation and exhalation.

Aspirated pen caps or push buttons come in different sizes and shapes and predispose for complete airway obstruction. Aspiration of a perforated pen cap does not lead to the classic secondary radiographic changes or decreased breath sounds on physical examination.

In patients with a vague history, a high degree of suspicion is necessary to avoid late complications of missed airway foreign bodies. Early management including advanced imaging techniques like CT virtual bronchoscopy and prompt rigid or flexible bronchoscopy is crucial. Use of a Fogarty arterial embolectomy catheter in the removal of perforated foreign bodies was shown to be easy and safe.

Acknowledgements

Conflicts of interest

There are no conflicts of interest.

References

- 1 National Center for Injury Prevention and Control (NCIPC). 2005 Available at www.cdc.gov/ncipc/wisqars [Accessed 1 October 2011].
- 2 Centers for Disease Control and Prevention. Nonfatal choking-related episodes among children – United States, 2001. *MMWR Morb Mortal Wkly Rep* 2002; **51**:945–958.
- 3 Rimell FL, Thome AJ, Stool S, Reilly JS, Rider G, Stool D, *et al*. Characteristics of objects that cause choking in children. *JAMA* 1995; **274**:1763–1766.
- 4 Centers for Disease Control and Prevention. *National vital statistics system National vital statistics system Mortality data*. National Center for Health Statistics 1999.
- 5 Jiaqiang S, Jingwu S, Yanming H, Qiuping L, Yinfeng W, Xianguang L, *et al*. Rigid bronchoscopy for inhaled pen caps in children. *J Pediatr Surg* 2009; **44**:1708–1711.
- 6 Sersar SI, Ismail MF, Elsoroghi HA, Abd El Mooty H. The value of open surgical approaches for aspirated pen caps: revisited. *J Pediatr Surg* 2006; **41**:875 author reply 875–876.
- 7 Louie MC, Bradin S. Foreign body ingestion and aspiration. *Pediatr Rev* 2009; **30**:295–301, quiz 301.
- 8 Rovin JD, Rodgers BM. Pediatric foreign body aspiration. *Pediatr Rev* 2000; **21**:86–90.
- 9 Zhijun C, Fugao Z, Niankai Z, Jingjing C. Therapeutic experience from 1428 patients with pediatric tracheobronchial foreign body. *J Pediatr Surg* 2008; **43**:718–721.
- 10 Esclamado RM, Richardson MA. Laryngotracheal foreign bodies in children. A comparison with bronchial foreign bodies. *Am J Dis Child* 1987; **141**:259–262.
- 11 Svedström E, Puhakka H, Kero P. How accurate is chest radiography in the diagnosis of tracheobronchial foreign bodies in children? *Pediatr Radiol* 1989; **19**:520–522.
- 12 Mu L, He P, Sun D. Inhalation of foreign bodies in Chinese children: a review of 400 cases. *Laryngoscope* 1991; **101** (6 Pt 1):657–660.
- 13 Saki N, Nikakhlagh S, Rahim F, Abshirini H. Foreign body aspirations in infancy: a 20-year experience. *Int J Med Sci* 2009; **6**:322–328.
- 14 Bhat KV, Hegde JS, Nagalotimath US, Patil GC. Evaluation of computed tomography virtual bronchoscopy in paediatric tracheobronchial foreign body aspiration. *J Laryngol Otol* 2010; **124**:875–879.
- 15 Cevizci N, Dokucu AI, Baskin D, Karadağ CA, Sever N, Yalçın M, *et al*. Virtual bronchoscopy as a dynamic modality in the diagnosis and treatment of suspected foreign body aspiration. *Eur J Pediatr Surg* 2008; **18**:398–401.
- 16 Ulkü R, Onen A, Onat S, Özçelik C. The value of open surgical approaches for aspirated pen caps. *J Pediatr Surg* 2005; **40**:1780–1783.
- 17 Tang LF, Xu YC, Wang YS, Wang CF, Zhu GH, Bao XE, *et al*. Airway foreign body removal by flexible bronchoscopy: experience with 1027 children during 2000–2008. *World J Pediatr* 2009; **5**:191–195.
- 18 Tahir N, Ramsden WH, Stringer MD. Tracheobronchial anatomy and the distribution of inhaled foreign bodies in children. *Eur J Pediatr* 2009; **168**:289–295.