

Assessment and management of urethrocutaneous fistula developing after hypospadias repair

Tamer Yassin^a, Khaled Husein Bahaaeldin^a, Ayman Husein^a and Hisham El Minawi^b

Background/Purpose To highlight and assess the different factors related to the development of urethrocutaneous fistulae (UCFs) after hypospadias repair, and the outcome of their repair using two different techniques.

Patients and methods In the period June 2009 to October 2010, all patients presenting to the Pediatric Surgery Unit at the Cairo University Pediatric Hospital with fistulae after hypospadias repair were divided into three groups. The first group included the patients with distal small fistula (less than 2 mm in size). The second group included the patients with more proximal and larger fistulae (2–4 mm in size). The third group included the patients with multiple fistulae or recurrent persistent fistulae (more than 4 mm in size). Risk factors related to the development of UCF were assessed, and the outcome of fistula closure was analyzed. The follow-up periods ranged from 6 to 12 months. The mean follow-up period was 8 months. The protocol of the study was approved by the Ethics Committee of the Cairo University.

Results Sixty-seven patients with posthypospadias repair fistulae were included in this study; 52 patients (77.6%) had fistula repair for the first time and 15 patients (22.3%) had fistula repair for recurrent fistula. Twenty-one patients (31.3%) had anterior penile fistulae, whereas 13 patients (19.4%) had coronal fistulae and nine patients (13.4%) had midpenile fistulae. Eight patients (11.9%) had acquired

penoscrotal fistulae. Sixteen patients (23.8%) had multiple and/or branching fistulae. Ten patients (14.9%) had direct closure of the fistula, whereas 57 patients (85.1%) had fistula closure with dartos flap coverage. Successful fistula repair was achieved in 56 patients (83.5%), whereas fistula recurrence occurred in 11 patients (16.5%).

Conclusion There is no single, universally applicable technique for repairing all types of UCF after hypospadias. The repair depends on the size and site of fistula, the complexity of previous operations performed for closure of fistula, the original hypospadias technique for repair of hypospadias, and the condition of the nearby skin. Primary repair of UCF and covering the repair with dartos flap give excellent results. It is suitable for repair of a wide variety of fistulae and is easier to perform by junior surgeons. *Ann Pediatr Surg* 7:88–93 © 2011 Annals of Pediatric Surgery

Annals of Pediatric Surgery 2011, 7:88–93

Keywords: hypospadias, urethra, urethrocutaneous fistula

^aDepartment of Surgery, Pediatric Surgery Unit and ^bPlastic Surgery Unit, Cairo University Pediatric Hospital, Cairo, Egypt

Correspondence to Tamer Yassin, MD, Department of Surgery, Pediatric Surgery Unit, Cairo University Pediatric Hospital, Cairo, Egypt
Tel: +2 012 2329023; fax: +2 0225931373;
e-mail: tamyassin@yahoo.com

Received 6 December 2010 Accepted 15 February 2011

Introduction

Urethrocutaneous fistula (UCF) is one of the most frequently seen complications of hypospadias surgery requiring reoperation. During the last decade, many principles of an ideal repairing technique have been clarified. Delicate tissue handling, inversion of the urethral mucosa after excising the epithelialized tract of the fistula, a multilayer repair with well-vascularized tissues, avoiding overlapping sutures and nonabsorbable or thick suture materials, a tension-free closure, use of optical magnification, and bipolar diathermy for coagulation are currently considered mandatory [1]. UCF after hypospadias repair remains a significant challenge for pediatric surgeons despite the advances in surgical techniques. The incidence of UCF varies from 4 to 28% [2–4]. The purpose of this study was to assess and evaluate the different factors associated with development of UCF and the outcome of their repair using two different operative procedures: (i) simple repair involving excision of fistula edges with a direct double-layered closure for small and pin-point fistulae and (ii) complex repair with the addition of dartos flap for large/multiple fistulae.

Patients and methods

All patients who had undergone UCF repair in the period October 2009 till June 2010 were included in this study with follow-up periods ranging from 6 to 12 months. The mean follow-up period was 8 months.

The study was conducted at the Pediatric Surgical Unit, Cairo University Pediatric Hospital, which is the largest referral children's hospital in Egypt. It accepts all acute and chronically ill neonates and children of all age groups in the Greater Cairo area (20 million population). There are some average 10–15 hypospadias repair surgeries performed every week in the General, Plastic, and Pediatric Urology Units.

All patients were subjected to detailed history as follows: (i) initial operative repair, that is, age at admission, urinary manifestations, hormonal therapy, degree of hypospadias, the operation performed for repair, size and type of suture material used, whether the patient had a stent or catheter or urinary diversion, and postoperative complications including infection and fistula development. (ii) Fistula repair, that is, timing of development of fistula after the operation, number of previous operations

if the fistula was recurrent, the operative techniques used. (iii) Specific risk factors for fistula recurrence, that is, position and number of fistulae, fistula size, presence of distal obstruction, stent and suture materials used and evidence of postoperative infection. Some patients who had undergone previous hypospadias or fistula repair outside our center and had some missing details due to absent documentation were included in this study.

Preoperative evaluation

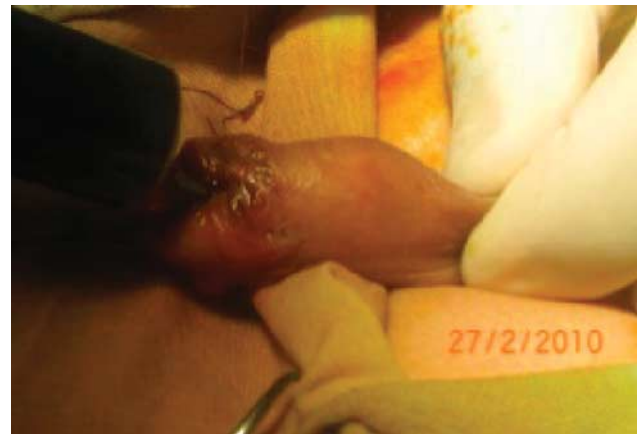All patients underwent physical examination as regards age, weight, height, built, general appearance, mentality and milestones of development (for associated endocrinal disorders), examination of external genitalia (for associated undescended testis and meatal stenosis), suprapubic area, and perineum. Investigations included routine preoperative laboratory investigations, urine analysis, and culture. Abdominal and pelvic ultrasounds were required in the severe proximal cases for evaluation of the urinary tract. In addition, anesthetic and surgical risks were assessed.

Patients were then divided into three groups according to the number of fistulae, their site, and the size and number of previous operations performed for fistula closure. (i) The first group included the patients with distal small fistulae (less than 2 mm in size), (ii) the second group included the patients with more proximal and larger fistulae (2–4 mm in size), and (iii) the third group included the patients with multiple fistulae or recurrent persistent fistulae (more than 4 mm in size). Repair was not attempted before 6 months provided the skin of the penis and around the fistula regained pliability.

Patients received a single intravenous dose of a first-generation cephalosporin (cephradine 50 mg/kg) as prophylaxis at induction. Patients with a stent after surgery, usually a 6-Fr catheter, were placed on oral antibiotic prophylaxis with sulphamethoxazole–trimethoprim (100 mg/kg/day in two divided doses) and ampicillin–clavulanic acid (100 mg/kg/day in two or three divided doses) until removal at 5–8 days after surgery. All patients received caudal anesthesia, and all surgeons used loupe (Neitz Instruments Co., Ltd., Shinjuku-Ku, Tokyo, Japan) magnification. Urethroplasty was performed with 6/0 polyglactin (Vicryl, Ethicon, Johnson & Johnson Pty Ltd, USA) sutures, with 5/0 polyglactin for the glanuloplasty.

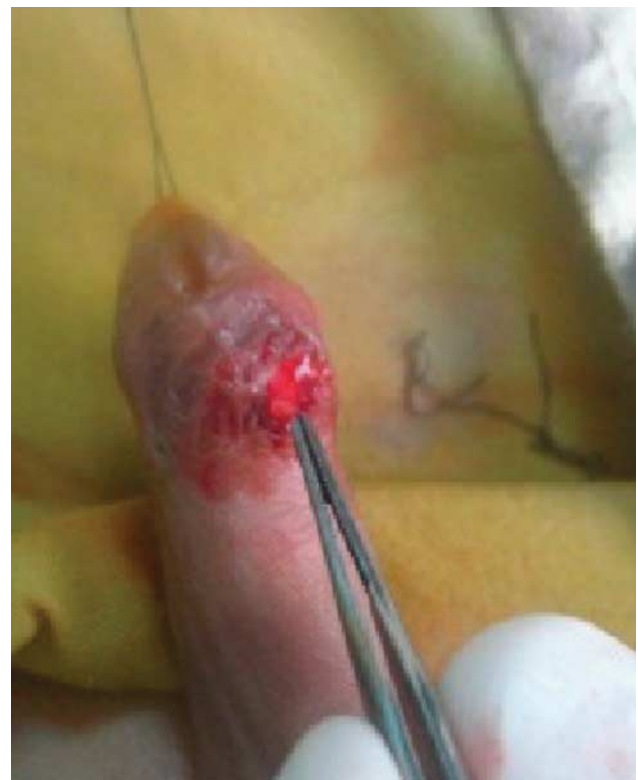After induction of anesthesia, the site of the fistula was identified by insertion of a catheter or the nozzle of a syringe filled with diluted povidone–iodine into the meatus and injection of the betadine into the urethra (Fig. 1). This maneuver has the advantages of identifying any additional fistulae and tracing the fistulous tract. Extensive debridement and elaborate excision of the fistulous tract down to the healthy thin urethral tissue were performed (Figs 2 and 3). Delicate instruments were required and healthy tissue was incorporated in the repair of all patients. Insertion of Nelaton's catheter (Hong An Medical Appliance Co., Ltd., Jiangsu, China) in the urethra was then performed (Fig. 4); the size of the catheter depended on the caliber of the urethra. The catheter was left in place to act as a stent postoperatively. The type of repair was chosen according to the size and location of

Fig. 1



Injection of betadine to demonstrate urethrocutaneous fistula.

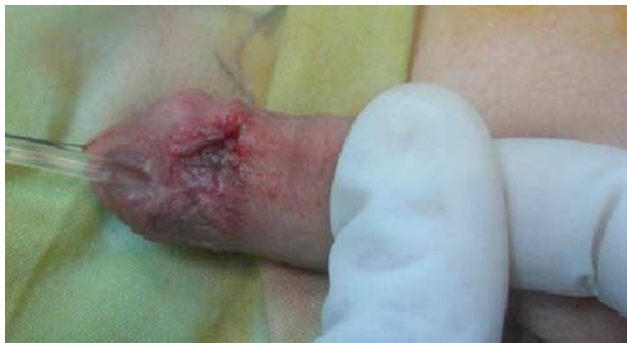Fig. 2



Dissection of pinpoint urethrocutaneous fistula.

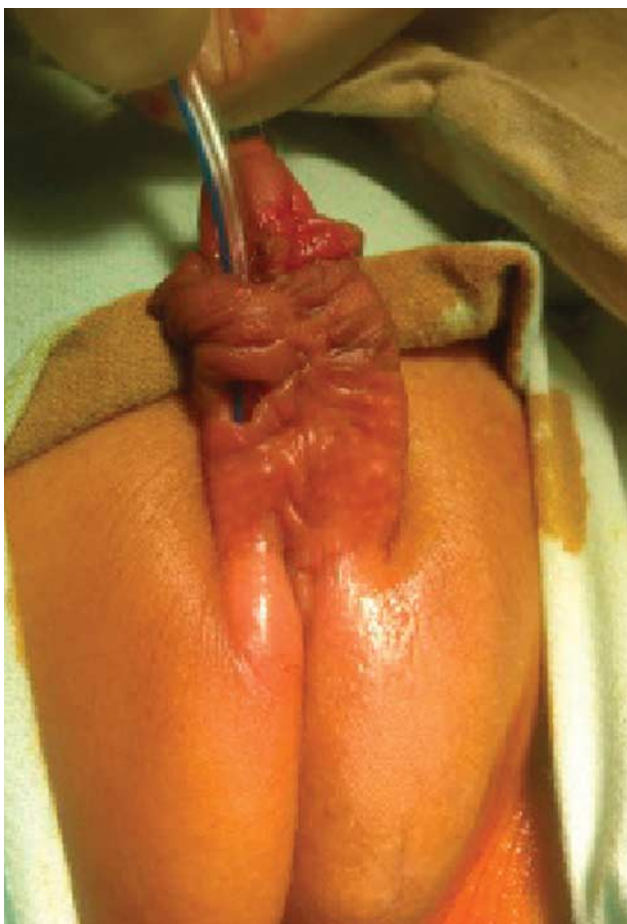
the fistula. For small group 1 fistulae, simple transverse approximation of healthy urethral tissue was carried out. A running subcuticular inverting suture of vicryl 6/0 (Ethicon, USA) had been used to close the urethral edges. In large/multiple fistulae (groups 2 and 3), an intermediate protective layer of dartos fascia was introduced (Fig. 5) to prevent fistula recurrence. In some patients, there were multiple fistulae very close to each other; we transformed them into one large fistula, which had a primary repair with subcuticular vicryl 6/0; then coverage with intermediate

Fig. 3



Direct double-layer closure of small urethrocutaneous fistula.

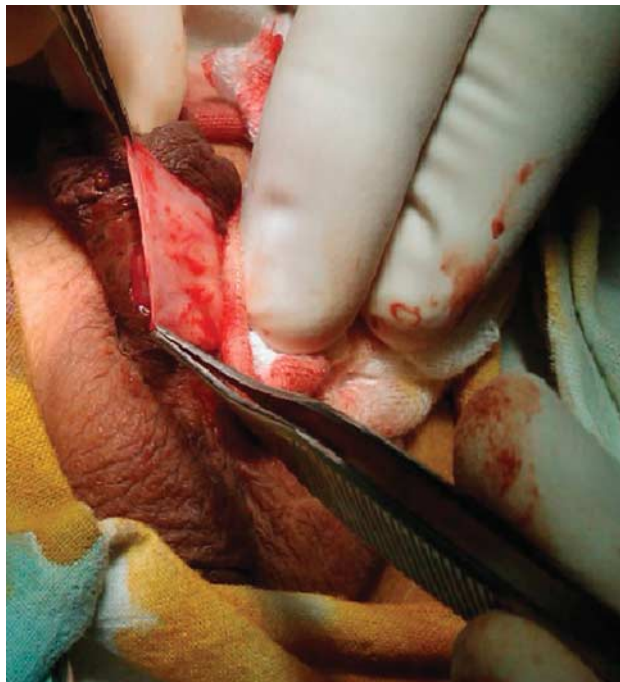Fig. 4



Large midpenile urethrocutaneous fistula.

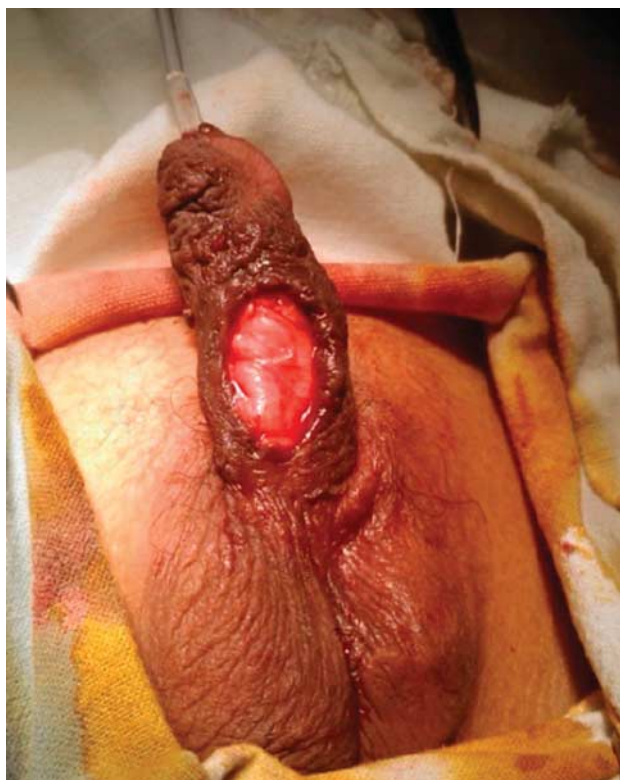
layer of dartos fascia was performed (Fig. 6). In other patients, there was a large fistula near the corona with complete meatal stenosis. In this situation, a complete redo operation was performed using the tubularized incised urethral plate technique (subcuticular 6/0 vicryl had been used). Penile skin closure was achieved with 6/0 vicryl, and the Nelaton's catheter was fixed by 5/0 silk. Postoperative dressing was applied for 3 days.

Fig. 5



Creation of dartos flap.

Fig. 6



Completed dartos flap coverage of the urethrocutaneous fistula site.

Postoperative care

The length of hospital stay ranged from 1 to 4 days according to the patient's clinical condition, as a lot of

mothers ignore the care of catheters postoperatively and to control cases with severe postoperative pain. All patients were followed regarding vital signs (pulse, blood pressure, respiratory rate, and temperature), regular observation of the penile dressing, and urine bag daily (for urine output, bleeding from the wound, and soaked dressing). Oral feeding started 2-h after the procedure if the patient was stable and could tolerate feeding. Analgesics and antibiotics were given (ampicillin–sulbactam) for 5–7 days. Dressing was removed on the third postoperative day, and the catheter was removed on the fourth day, and the patient was discharged home.

Follow-up

This included clinical and laboratory evaluations. Clinical evaluation included history taking, with special reference to urinary stream (force and caliber), any abnormal urinary flow (urine coming out from openings other than the meatus). Clinical examination included inspection for the site of the surgery (for penile deformities and scars) together with inspection for the act of voiding (for the stream of urine and the presence of recurrent fistulae). Evaluation was made on weekly basis for 1 month, then monthly for the next 6 months. Laboratory evaluation included urine analysis together with culture and sensitivity tests in selected cases. Dilatation was performed for cases suffering from meatal stenosis at follow-up.

Results

Analysis of collected data

Age

Of the 67 patients, 18 patients (26.8%) were aged 2 years or below, 14 patients (20.8%) were aged above 6 years, and 35 patients (52.2%) were aged between 2 and 6 years. The majority of cases at the time of repair of fistula belonged to the age group between 2 and 6 years.

Type of original hypospadias

The majority of UCF occurred after repair of anterior penile hypospadias. The initial site of hypospadias is shown in Table 1.

Operative technique used in the correction of the original hypospadias

The majority of cases (41 patients, 61%) have undergone tubularized incised plate (TIP) urethroplasty for repairing the original hypospadias. The initial technique was unknown in 12 patients (17.9%) who were operated outside our institute. The operative techniques used in the correction of the original hypospadias are shown in Table 2. The prevalence of post-TIP urethroplasty UCF represents approximately 5–7% failure rate of the total TIP cases performed at our center, and reflects the

Table 1 Degree of original hypospadias

Type	Number	Percent
Anterior penile	36	53.7
Pen scrotal	17	25.3
Midpenile	9	13.4
Posterior penile	5	7.4
Total	67	100.0

current trends of adopting the TIP procedure in most cases of distal penile hypospadias. The failure rate after Mathieu meatal-based flap represents a failure rate of approximately 8–10% of the total cases.

Time elapsed before appearance of the fistula

Five patients (7.4%) developed fistula immediately after hypospadias repair. The time elapsed before appearance of the fistula is shown in Table 3.

Site of the urethrocutaneous fistula

Twenty-one patients (31.3%) had developed anterior penile fistulae. The sites of occurrence of the UCF are shown in Table 4.

Outcome of urethrocutaneous fistula repair

Ten patients (14.9%) underwent direct double-layer closure of the fistula, and 57 patients underwent fistula closure with dartos flap coverage. Meatotomy for meatal stenosis was performed in 12 patients (17.9%). Successful fistula closure was achieved in 56 patients (83.5%), whereas recurrence of UCF was seen in 11 patients (16.5%). Of these 11 recurrences, five were after direct fistula closure and six were after dartos flap closure, of whom three cases suffered from postoperative wound infection and one suffered from accidental postoperative catheter removal. Failure rate after direct closure was greater than after dartos flap closure. Five of these failed

Table 2 Initial technique used for repair of hypospadias

Technique	Number	Percent
TIP	41	61.1
Mathieu	10	14.9
Onlay	4	5.9
Unknown	12	17.9
Total	67	100.0

TIP, tubularized incised plate.

Table 3 Time elapsed before appearance of urethrocutaneous fistula

Days	Number	Percent
2	5	7.4
7	9	13.4
10	3	4.4
14	4	5.9
21	17	25.3
30	12	17.9
60	8	11.9
90	7	10.4
180	2	2.9
Total	67	100.0

Table 4 Distribution of patients according to urethrocutaneous fistula site

Site of fistula	Number	Percent
Anterior penile	21	31.3
Coronal	13	19.4
Mi-penile	9	13.4
Coronal and subcoronal (multiple)	6	8.9
Penoscrotal	8	11.9
Proximal penile and penoscrotal (multiple)	5	7.4
Midpenile and penoscrotal (multiple)	5	7.4
Total	67	100.0

closures were after onlay island flap repair, whereas the other six had an unknown previous procedure.

Follow-up was feasible for at least 6 months after closure of UCF, then continued for varying durations but with some patients dropping off at follow-up. Of the 67 patients, 29 patients (43.2%) had been followed for 16 months after repair of UCF. Twenty patients (29.8%) had been followed for 12 months after repair. Fourteen patients (20.8%) had been followed for 9 months after repair, and four patients (5.9%) had been followed for 6 months after repair.

Discussion

Development of UCF after corrective surgery for hypospadias remains the most important complication. We analyzed the different aspects that may be associated with the development of UCF together with studying the efficacy of two simple techniques, which could be utilized by junior surgeons in treating UCF.

Many variables could influence the surgical management and outcome, that is, the use of magnification [5], the time of occurrence after urethroplasty, the location (glanular, coronal, mid shaft, etc.), size (pinpoint, large), the number, and the conditions of local tissue [6]. However, Waterman *et al.* [7] reported no significant difference in outcomes when comparing some variables, for example, whether to use a stent or catheter, optical magnification, patient age and interval between surgery at time of fistula repair, type of original hypospadias procedure, and number of previous fistula repairs. An algorithm was suggested by some researchers for the management of different types of UCF [8]. Successful repair of these UCF depends on several basic principles, which are the avoidance of procedures on inflamed tissue, correction of distal obstruction, a tension-free urethral closure with absorbable suture material, and covering of the urethral repair with well-vascularized tissue [1,7,9]. The operative approaches for UCF range from the simple closure to 'pants-over-vest' technique using either local tissues or tunneled tunica vaginalis flap (TVF) [10].

Most UCFs encountered in our study after hypospadias surgery were located at the distal penile region (40 of 67 cases, 59.7%). The most difficult healing site after reconstructive surgery is the coronal sulcus. This region is located between the corpus penis and glans penis, and is poorly vascularized. The dissection of the penile skin and the urethral plate in coronal sulcus may completely impede coronal vascularization. Especially in adolescent patients, erections in the postoperative period may aggravate the ischemia in the coronal sulcus, and increase the likelihood of fistula development and recurrence, creating serious problems in the healing process [8]. In some published data, the recommended process for repair of fistulae located in the coronal sulcus is to avoid repairing with simple skin flaps and to use advancement of rotation flaps [8]. In this region, our preference has been to repair the fistulae with dartos flaps. If the fistula in this localization is too large and too close to the external meatus, we feel that redo hypospadias surgery, instead of fistula repair, would be more suitable.

The frequency of success in fistula closure is based on the type of the original hypospadias procedure. This wide range is largely explained by the small number of patients in certain groups. Fistula repair rates were greater than 75% after glans approximation procedure (GAP)/pyramid, island onlay flaps, island tubes, and Snodgrass and meatal advancement and glanuloplasty (MAGPI) procedures. The repair rate for the King (distal shaft urethral repair without incision of the urethral plate) and the Yoke (used after scrotal or perineal hypospadias) procedures were 45 and 20%, respectively. These lower rates may be due to less intact vascular supply over the ventral portion of the neourethra and more extensive mobilization of the urethral plate required at original hypospadias repair. On the basis of these observations, one could expect greater success at repairing fistulae associated with less complex initial hypospadias repairs and those with a substantial and intact vascular pedicle [7]. Therefore, fistulae developing after complex operative techniques or located near the coronal sulcus or at the proximal penile area are better closed with flaps.

The repair can be successful without transurethral stenting. We have always used such stents because an indwelling catheter, inserted for few days, can support the healing urethra and prevent recurrences.

We found that the number of previous procedures did not negatively influence the rate of the success of subsequent fistula repair. Approximately 80% of first and second repairs were successful. This finding was surprising in that conventional thinking in hypospadias and fistula surgery would suggest that each procedure would induce additional poorly vascularized scar tissue around the fistula and diminish the chances for subsequent successful repair. Such possible problems may have been minimized by completely excising the fistulous tract and using a healthy and well-vascularized dartos or subcutaneous flap over the repair [7].

The objective of this study was to assess the development, management, and outcome of UCF repair fistula using two techniques for repair: simple double-layer closure and closure with dartos flap coverage. The published data show that the mean success rate of simple closure of fistula after hypospadias is 77% [8]. Holland *et al.* [11] reported that the risk of recurrent UCF was increased after a simple repair. This was supported by the findings in our series, in which recurrence of UCF occurred in five of 10 cases (50%) performed with direct fistula closure compared with six of 57 cases performed with flap coverage (10.5%). Therefore, simple closure of UCF although less time consuming and less technically demanding has a high risk of recurrence even in small-sized fistulae [10].

Performing the fistula repair 6 months after the initial operation has been advocated in all relevant series [12]. The time required for skin vascularization and resolution of the inflammation around the fistula is 6 months. In our study, all fistula repairs were performed at least 6 months after the initial hypospadias operation.

The interposition of vascularized tissue such as de-epithelized skin flap [8,13], scrotal dartos [14], external spermatic fascia [15], or tunneled TVF [16–19] has been suggested as an effective means of reducing the UCF formation rate. Galtzeiler and Belman [13] described the use of the two-layer skin advancement technique, and reported 100% and 91% success rates in 19 cases of midshaft fistulae and 11 cases of coronal fistulae, respectively. In another study of 94 patients who underwent both simple and complex fistula repairs, Santangelo *et al.* [12] reported an overall success rate of 93.4%. Cimador *et al.* [20] compared the outcomes of simple closure and layered (mobilized de-epithelized skin flaps) closure for UCF in 72 patients, and reported a 74% success rate for simple closure and 94% success rate for layered closure. This is in consistency with the results of our series (51 of 57 cases, 89.5% success rate). This was achieved by using simple fistula closure reinforced by mobilized penile dartos fascia flap coverage or perputial flap coverage if available. According to our results, the results of this technique are comparable with other flap-based techniques. It is also less complex, less technically demanding, and can be easily performed by junior surgeons.

Conclusion

The choice of technique of repair for UCF, which develops after repair of hypospadias, depends on several factors including the penile skin condition and the complexity of the previous operations for hypospadias and UCF repair attempts. The decision for UCF repairs either by simple or flap closure should be based on these factors in order to avoid the high recurrence rate (50%) seen with simple closures. Dartos fascia flap closure is a viable surgical option, which gives satisfactory results.

References

- Latifoglu O, Yavuzer R, Unal S, Cavusoglu T, Atabay K. Surgical treatment of urethral fistulas following hypospadias repair. *Ann Plast Surg* 2000; **44**:381–386.
- Nuininga JE, De Gier RP, Verschuren R, Feitz WF. Long-term outcome of different types of 1-stage hypospadias repair. *J Urol* 2005; **174** (4 Pt 2): 1544–1548. [discussion 1548]
- Demirbilek S, Kanmaz T, Aydin G, Yucesan S. Outcomes of one-stage techniques for proximal hypospadias repair. *Urology* 2001; **58**:267–270.
- Uygur MC, Unal D, Tan MO, Germiyanoglu C, Erol D. Factors affecting outcome of one-stage anterior hypospadias repair: analysis of 422 cases. *Pediatr Surg Int* 2002; **18**:142–146.
- Secrest CL, Jordan GH, Winslow BH, Horton CE, McCraw JB, Gilbert DA, *et al.* Repair of the complications of hypospadias surgery. *J Urol* 1993; **150** (5 Pt 1):1415–1418.
- Horton CE, Devine CJ, Graham JK. Fistulas of the penile urethra. *Plast Reconstr Surg* 1980; **66**:407–418.
- Waterman BJ, Renschler T, Cartwright PC, Snow BW, DeVries CR. Variables in successful repair of urethrocutaneous fistula after hypospadias surgery. *J Urol* 2002; **168**:726–730. [discussion 729–730].
- Elbakry A. Management of urethrocutaneous fistula after hypospadias repair: 10 years' experience. *BJU Int* 2001; **88**:590–595.
- Shankar KR, Losty PD, Hopper M, Wong L, Rickwood AM. Outcome of hypospadias fistula repair. *BJU Int* 2002; **89**:103–105.
- Muruganandham K, Ansari MS, Dubey D, Mandhani A, Srivastava A, Kapoor R, *et al.* Urethrocutaneous fistula after hypospadias repair: outcome of three types of closure techniques. *Pediatr Surg Int* 2010; **26**:305–308.
- Holland AJA, Abubacker M, Smith GHH, Cass DT. Management of urethrocutaneous fistula following hypospadias repair. *Pediatr Surg Int* 2008; **24**:1047–1051.
- Santangelo K, Rushton HG, Belman AB. Outcome analysis of simple and complex urethrocutaneous fistula closure using a de-epithelialized or full thickness skin advancement flap for coverage. *J Urol* 2003; **170** (4 Pt 2):1589–1592. [discussion 1592]
- Geltzeiler J, Belman AB. Results of closure of urethrocutaneous fistulas in children. *J Urol* 1984; **132**:734–736.
- Churchill BM, Van Savage JG, Khoury AE, McLorie GA. The dartos flap as an adjunct in preventing urethrocutaneous fistulas in repeat hypospadias surgery. *J Urol* 1996; **156**:2047–2049.
- Yamataka A, Ando K, Lane GJ, Miyano T. Pedicled external spermatic fascia flap for urethroplasty in hypospadias and closure of urethrocutaneous fistula. *J Pediatr Surg* 1998; **33**:1788–1789.
- Landau EH, Gofrit ON, Meretyk S, Katz G, Golijanin D, Shenfeld OZ, *et al.* Outcome analysis of tunica vaginalis flap for the correction of recurrent urethrocutaneous fistula in children. *J Urol* 2003; **170** (4 Pt 2): 1596–1599. [discussion 1599].
- Routh JC, Wolpert JJ, Reinberg Y. Tunneled tunica vaginalis flap is an effective technique for recurrent urethrocutaneous fistulas following tubularized incised plate urethroplasty. *J Urol* 2006; **176** (4 Pt 1): 1578–1580. [discussion 1581]
- Singh RB, Pavithran NM. Tunica vaginalis interposition flap in the closure of massive disruption of the neourethral tube (macro urethrocutaneous fistulae). *Pediatr Surg Int* 2004; **20**:464–466.
- Gurdal M, Karaman MI, Kanberoglu H, Kirecci S. Tunica vaginalis reinforcement flap in reoperative Snodgrass procedure. *Pediatr Surg Int* 2003; **19**:649–651.
- Cimador M, Castagnetti M, De Grazia E. Urethrocutaneous fistula repair after hypospadias surgery. *BJU Int* 2003; **92**:621–623.