

# Fistulectomy and anoplasty for low imperforate anus with anoperineal fistula in boys

Ibrahim Ali Ibrahim

**Purpose** To present our operative technique for the treatment of anoperineal fistula, discussing its advantages in comparison with other methods of treatment.

**Patients and methods** This study included 35 neonate boys, 34 were full term and one was preterm. Their age ranged from 1 to 4 days, and they were diagnosed to have low imperforate anus with anoperineal fistula, without associated major anomalies. They were treated by fistulectomy and anoplasty.

**Results** The operative time ranged from 25 to 40 min. The operation was completed successfully in all patients. All patients started gradual oral feeding 2 h postoperatively and were discharged after 24–48 h on oral feeding. Postoperative stricture occurred in two patients, one responded to dilation and the other needed redo surgery by a simple cutback technique. Continence could be assessed in 23 patients whose follow-up periods were

longer than 3 years. Twenty-one patients had a good score and two had a fair score. No patients had a poor score.

**Conclusion** Our approach has the following advantages: (i) the operation is simple and easy to perform. (ii) It has a minimal complication rate, with a good cosmetic and functional outcome. (iii) Anorectal function was not adversely affected in patients with anterior position of the anal orifice. *Ann Pediatr Surg* 7:19–22 © 2011 Annals of Pediatric Surgery

*Annals of Pediatric Surgery* 2011, 7:19–22

**Keywords:** anorectal anomalies, anoperineal fistula, low imperforate anus

Department of General Surgery, Pediatric Surgery Unit, Faculty of Medicine, Assiut University, Assiut, Egypt

Correspondence to Ibrahim Ali Ibrahim, Department of General Surgery, Pediatric Surgery Unit, Faculty of Medicine, Assiut University, Assiut, Egypt  
Tel: +00 20 105801291; fax: +00 20 882414381

Received 10 May 2010 Accepted 15 June 2010

## Introduction

Anorectal malformations consist of a wide spectrum of diseases, which can affect boys and girls, that involve the distal anus and rectum as well as the urinary and genital tracts. They occur in approximately one of the 5000 live births [1].

Defects range from very minor defects, which are easily treated with an excellent functional prognosis, to defects that are complex, difficult to manage, often associated with other anomalies, and have a poor functional prognosis.

Perineal fistulas in both male and female patients have traditionally been called 'low' defects. In these cases, the rectum opens in a small orifice, usually stenotic and located anterior to the center of the sphincter. Most of these patients have excellent sphincter mechanisms and a normal sacrum. In male patients, the perineum may exhibit other features that help in recognition of this defect, such as a prominent midline skin bridge (known as 'bucket handle') or a subepithelial midline raphe fistula that looks like a black ribbon because it is full of meconium. These features are externally visible and help diagnose a perineal fistula [2].

The anoperineal fistula could be treated by several approaches.

In the classic cutback procedure, a hemostat is placed in the anus and the tissue is cut back with cautery exactly in the midline to the posterior border of the external sphincter. A simple anoplasty enlarges the stenotic orifice and relocates the rectal orifice posteriorly within the limits of the sphincter complex. The operation is called a 'minimal posterior sagittal anoplasty' [1]. Anterior

sagittal approach, involving anterior perineal dissection (from the base of the scrotum to the posterior part of the anoderm), is used by some surgeons, with the aim of preserving the internal anal sphincter [3].

The aim of this study was to present our approach on fistulectomy and anoplasty.

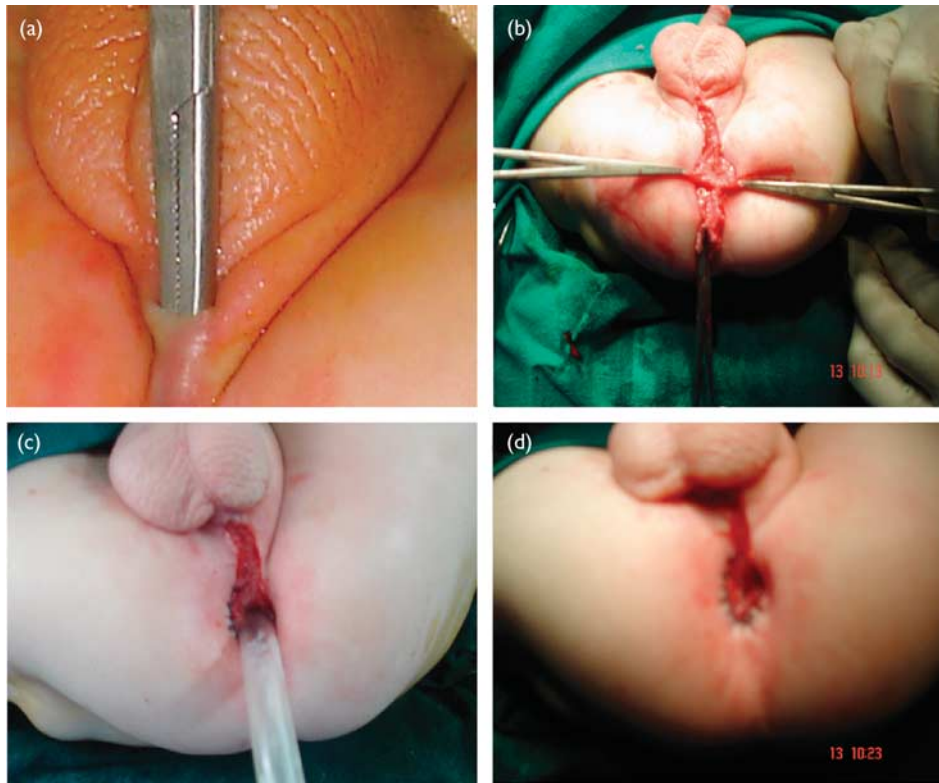
## Patients and methods

This study included 35 neonates who were treated at the Assiut University Hospital. Their age ranged from 1 to 4 days, and all of them were full term except one who was preterm. All of them were diagnosed on a clinical basis to have low imperforate anus with anoperineal fistula. None had major associated anomalies. All the patients underwent complete physical examination, abdominal sonography, and blood chemistry.

## Operative technique

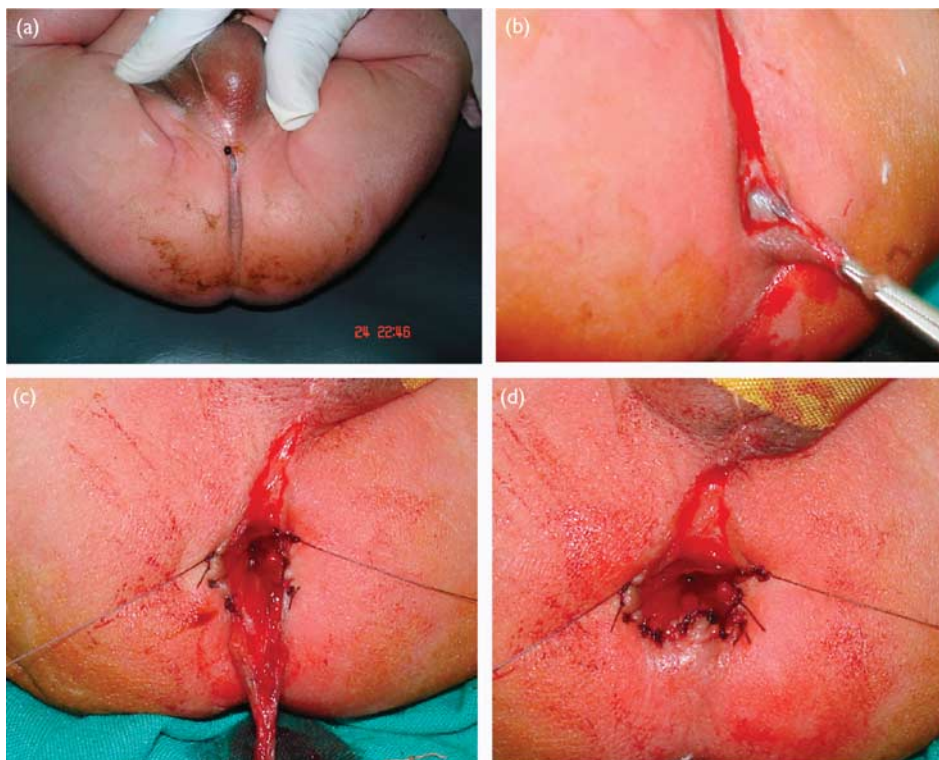
The operation was performed under general anesthesia with the patient in the lithotomy position. A semicircular incision was made around the fistulous opening; the fistulous tract was dissected posteriorly by a fine pair of scissors or a scalpel till the site of the anus was reached (Figs. 1b and 2b). The incision was completed on the lateral edges of the anal site as an inverted V and the triangular skin flap was dissected. The rectum was evacuated of meconium. The external sphincter fibers were identified precisely using a nerve stimulator on the skin. The external sphincter fibers were retracted posteriorly, and a posterior midline incision was made in the rectal pouch to widen the opening (Figs. 2c and 3c). The mucosa and anoderm at the cut edges were approximated with absorbable sutures and the triangular

Fig. 1



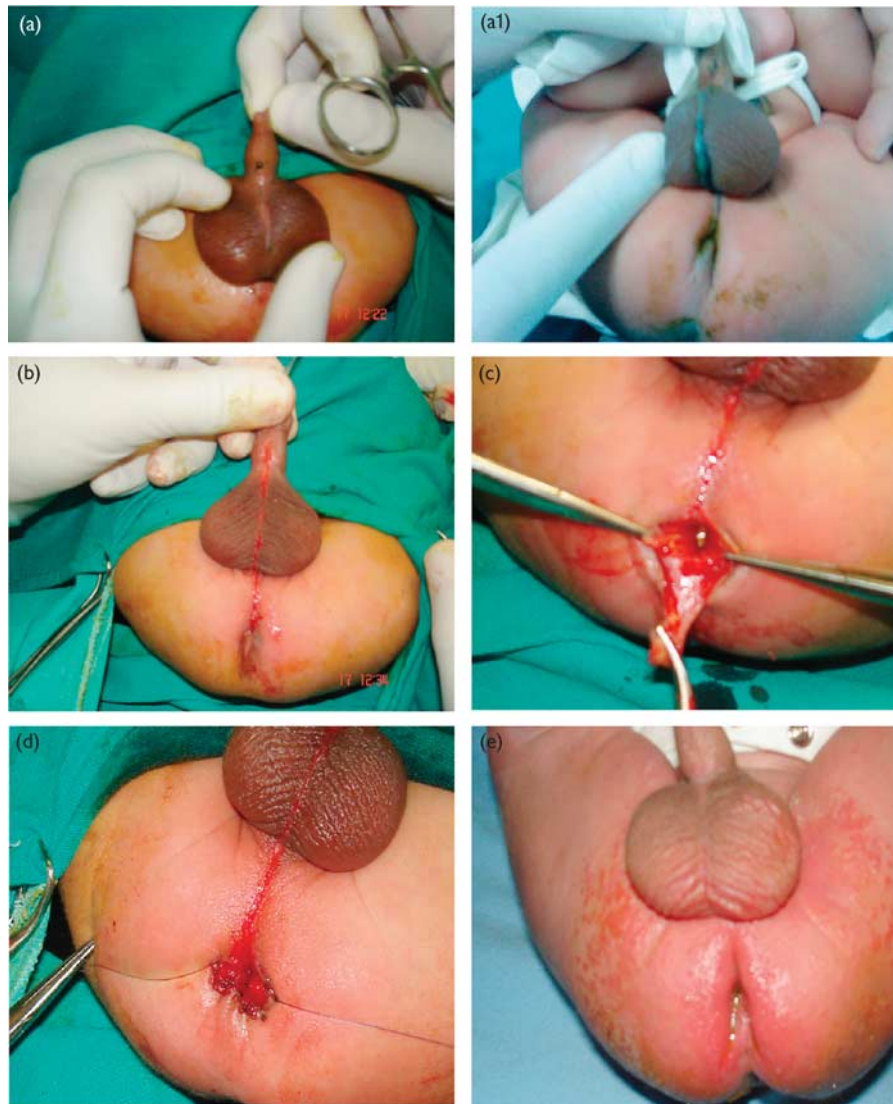
(a) Anoperineal fistula. (b) Excised fistulous tract. (c, d) Postoperative view.

Fig. 2



(a) Anoperineal fistula. (b) Dissection of the tract. (c) Excised tract. (d) Postoperative view.

Fig. 3



(a, a1) Anoperineal fistula (midpenile). (b) Excized tract. (c) Anoplasty. (d) Postoperative view. (e) 15 days postoperative.

skin flap was anastomosed to the incised posterior rectal wall to create a partially skin-lined anus (Figs. 1c, 2d and 3d). The wound was sterilized by povidone iodine and a small piece of gauze was put in the neoanus.

### Results

The operative time ranged from 25 to 40 min. The operation was completed successfully in all patients. All the patients started gradual oral feeding 2 h postoperatively and were discharged after 24 to 48 h on oral feeding. An oral antibiotic and metronidazole were given for 4 days.

- (1) Gradual anal dilation started 2 weeks postoperatively, and continued until the anus became pliable. Period range?
- (2) Postoperative stricture occurred in two patients, one responded to dilation and the other needed redo surgery by a simple cutback procedure.

Continence could be assessed in 23 patients whose follow-up periods were longer than 3 years using a clinical scoring method, and was scored as 'good', 'fair', and 'poor' [4]. Twenty-one patients had a good score and two had a fair score. No patients had a poor score. The incidence of smearing or staining did not diminish with age. Prolonged management was required in five patients who continued to have a poor level of fecal continence. Anorectal function was not adversely affected by the anterior position of the anal orifice in most patients after simple perineal surgery.

### Discussion

Anorectal malformations include a wide spectrum of defects in the development of the lowest portion of the intestinal and urogenital tracts. Many children with these malformations are said to have an imperforate anus because they have no opening where the anus should be. Perineal fistula is associated with good prognosis,

occurs in either sex, and involves a closed anus with a small connection that opens to the perineal body. Some babies with this malformation have a small loop of skin at the anal opening that resembles a bucket handle. This is pathognomonic for perineal fistula. Some boys may have no visible perineal opening but may accumulate mucous or meconium in the fistula, which can extend up to the median raphe of the scrotum and resemble a black cord (meconium) or a string of pearls (mucous) [5]. Meconium is usually not seen at the perineum in a baby with a rectoperineal fistula until at least 16–24 h. Abdominal distension does not develop during the first few hours [2].

The radiologic evaluation of a newborn with imperforate anus includes an abdominal ultrasound to evaluate urologic anomalies. A cross table lateral radiograph can help show the air column in the distal rectum in a small percentage of patients for whom clinical evidence does not delineate in 16–24 h [1]. In our study, the perineal fistulae were easy to diagnose even in the first 6 h, obviating the need for radiography. Abdominal ultrasonography was carried out as a routine in all cases and there were no associated renal anomalies in all cases. In one case, the fistula reached up to the mid penile position and there were no major associated anomalies except in one patient who had an associated hypospadias.

The decision to perform an anoplasty in the newborn period or to delay the repair and to perform a colostomy is based on the physical examination of the infant, the appearance of the perineum, and any changes that occur over the first 24 h of life [6,7].

Of our patients, all of them were operated upon within the first 24 h except those who presented on the second or the third day; they were operated on the same day of presentation.

Low imperforate anus with perineal fistula can be treated by many approaches

- (1) Cutback operation, an anterior sagittal approach, involving anterior perineal dissection (from the base of the scrotum to the posterior part of the anoderm), is used by some surgeons with the aim of preserving the internal anal sphincter [2]. However, it should be noted that this approach might damage the vesical nerve plexus when the rectourethral fistula is dissected up to its junction with the urethra. Furthermore, an internal sphincter-saving technique has been devised when performing the posterior sagittal approach [2].
- (2) The minimal posterior sagittal anoplasty is performed with the patient positioned prone with the pelvis elevated; multiple fine silk sutures are placed at the mucocutaneous junction of the bowel orifice for traction. A short (1–2 cm) midsagittal incision is made posterior to the fistula site, dividing the entire external sphincter complex. The fistula and lower part of the rectum are carefully dissected to allow mobilization of the rectum for backward placement

within the limits of the sphincter complex. The perineal body, the area in which the fistula was located, is repaired with a few long-term absorbable sutures [1]. In our technique, the fistula is dissected up to its connection to the anus; its site is left raw, which heals spontaneously within a few days. The anoplasty is performed as an inverted Y-V technique without mobilization of the rectum. The external sphincter is just retracted posteriorly to allow mobilization of the anus and the anoplasty is terminated by a skin-lined posterior quadrant.

Anorectal malformations have patient outcomes with greatly improved modern surgical techniques and neonatal care facilities during the last few decades. Early survival is a rule today, except in some rare cases with cardiac, urogenital, or chromosomal anomalies that are not compatible with life. Presently, the overall long-term functional outcome expectancy in terms of fecal and urinary continence is relatively optimistic. A majority of patients reaching adolescence and adulthood are able to maintain themselves as socially continent [8]. Using the Kelly–Kiesewetter scoring system in 23 patients of our series, 21 had a good score, two had a fair score, and none had a poor score [4]. Current mortality rates are low after repair of imperforate anus, and most of these deaths are attributable to problems with other organ systems, particularly the cardiovascular system and central nervous system. Sepsis (overwhelming infection) is occasionally a problem in patients with complicated high anomalies involving the genitourinary system. Mortality in patients was in the range of 5% for low anomalies [9]. In our series, there were no deaths.

Our approach has the following advantages: (i) the operation is simple and easy to perform. (ii) It has a minimal complication rate, with a good cosmetic and functional outcome. (iii) Anorectal function was not adversely affected in patients with anterior position of the anal orifice.

## References

- 1 Levitt MA, Peña A. Anorectal malformations. *Orphanet J Rare Dis* 2007; **26**:33–37.
- 2 Pena A, Levitt M. Anorectal malformations. In: Stringer M, Oldham K, Mouriquand PDE, editors. *Pediatric surgery and urology: long term outcomes*. Cambridge: Cambridge University Press; 2007. pp. 401–415.
- 3 Sigalek DL, Laberge JM, Adolph VR, Guttman FM. The anterior sagittal approach for high imperforate anus: a simplification of the Mollard approach. *J Pediatr Surg* 1996; **31**:625–629.
- 4 Kiesewetter WB, Chang JH. Imperforate anus: a five to thirty year follow-up perspective. *Prog Pediatr Surg* 1977; **10**:111–120.
- 5 Rosen NG, Beals DA. Imperforate anus. 2010; Available at: <http://emedicine.medscape.com/article/929904-overview>. [Accessed 12 February 2010]
- 6 Liu G, Yuan J, Geng J, Wang C, Li T. The treatment of high and intermediate anorectal malformations: one stage or three procedures? *J Pediatr Surg* 2004; **39**:1466–1471.
- 7 Peña A, Levitt MA. Anorectal malformations. In: Grosfeld JL, O'Neill JA, Fonkalsrud EW, Coran AG, editors. *Pediatric surgery*. Philadelphia: Mosby Elsevier; 2006. pp. 1566–1589.
- 8 Ong NT, Beasley SW. Long-term functional results after perineal surgery for low anorectal anomalies. *Pediatr Surg Int* 1990; **5**:238–240.
- 9 Rintala RJ. Congenital anorectal malformations: anything new? *J Pediatr Gastroenterol Nutr* 2009; **48** (Suppl 2):S79–S82.