



Symptomatic Non-parasitic benign hepatic cyst: Evaluation of Management by Deroofing in Ten Consecutive Cases

Khalid A. Ismail, Gamal I. Mousa, Osama. H. El Khadrawy, Hamdy A Mohamed

Department of Surgery, Tanta University Hospital, Tanta, Egypt

Background/Purpose: Solitary non-parasitic cysts of the liver are commonly asymptomatic and do not require treatment. Rarely, however, the cysts become symptomatic and are then best treated surgically. The optimal surgical treatment is debatable. The aim of this study was to evaluate the role of deroofing as a safe and effective approach in the management of simple non-parasitic hepatic cysts.

Materials & Methods: From January 2002 to October 2008, 10 patients (8 females and 2 males) with histologically proven non-parasitic, benign, simple hepatic cysts underwent deroofing at Tanta University Hospital. Deroofing was achieved by open surgery in 3 cases and by laparoscopic surgery in 7 patients. The principle of both open and laparoscopic approaches was to remove as much as possible of the cyst wall, destroy the endothelial lining and pack the residual cavity with omentum.

Results: All of our patients had a solitary cyst with a mean diameter of 12.5 cm (range; 9-18 cm) and all were symptomatic. The most common complaint was upper abdominal pain (n=7, 70%). Age ranged from 1 - 72 year with a median of 15 years. Three patients (30%) were treated with open deroofing while 7 patients (70%) underwent laparoscopic deroofing. One out of these 7 patients was converted to open surgery. Recurrence occurred in 2 patients but was asymptomatic and discovered on follow up because of the small diameter of recurrent cysts (3-4 cm). The follow up period ranged between 12 - 72 months (median 20 months).

Conclusion: with proper selection of patients, laparoscopic deroofing of symptomatic, benign, solitary, non-parasitic hepatic cysts is safe, effective and offers all the advantages of minimally invasive surgery. Open deroofing should be reserved for cysts inaccessible by laparoscopy, when the diagnosis is in doubt and for difficulties encountered at laparoscopy.

Index Word: hepatic cyst, laparoscopy.

INTRODUCTION

Non-parasitic simple liver cysts are a relatively common pathology which can affect up to 5% of people^{1, 2}. The term hepatic cyst usually refers to solitary non-parasitic cyst of the liver, also known as simple cyst. However several other cystic lesions of

the liver, including multiple cysts arising in the setting of polycystic liver disease, parasitic or hydatid (echinococcal) cysts, cystic tumors and hepatic abscesses which can be distinguished from simple cysts on the basis of patient's symptoms and the

radiological appearance of the lesion ³.

The cause of simple liver cysts is not known, but they are believed to be congenital in origin. As regard the pathology, they are lined by a uniform cuboidal or columnar epithelium resembling bile duct epithelium and perhaps resulted from progressive dilatation of biliary microhamartomas that fail to develop normal connections with the biliary tree. They contain fluid which mimics plasma and is continually secreted by the epithelial lining of the cyst; which may explain why needle aspirations are not curative ⁴.

The incidence of liver cysts rises with the age and they are frequently an incidental finding on abdominal ultrasound or CT scans. Although most cysts are asymptomatic, significant symptoms can develop as the result of increasing in the size. The most commonly presenting feature is pain which may arise in the right upper quadrant or epigastrium. Other symptoms are caused by pressure of the enlarging liver cysts on adjacent structures. Symptoms develop in approximately 15% of affected patients ^{5,6}.

Asymptomatic cysts are managed conservatively; whereas different treatment modalities have been used in symptomatic cysts, including percutaneous aspiration and sclerotherapy, open deroofting, laparoscopic deroofting radical cystectomy, or liver resection ^{7,8}. Advances in minimally invasive surgical technology have provided surgeons the chance to manage hepatic cysts laparoscopically either by resection or, in most cases, by deroofting or fenestration ⁹.

The aim of this study was to evaluate the role of deroofting of simple non-parasitic hepatic cysts either by laparoscopic or open surgery.

PATIENTS AND METHODS

This study included 10 patients with solitary simple hepatic cyst admitted to department of surgery, Tanta University Hospital, Egypt, from January 2002 to October 2008. Patient consent was obtained with complete discussion about the risk/benefit ratio.

Our study included only patients with symptomatic simple hepatic solitary cyst and excluded the patients with polycystic liver disease and parasitic liver cyst. All patients were subjected to thorough history taking (from the patient or his/her guardian), full clinical examination, routine laboratory investigations with

serological screening to exclude hydatid disease. The initial diagnosis for all patients was made first by abdominal ultrasonography. (Fig. 1) Abdominal computer tomography scan (CT scan) was done in all patients to give further information regarding the extent of the cyst and its deep and superficial relations to any vital structures within the liver. (Fig. 2).

Operative details:

Open surgery (Fig. 3) was done in 3 patients (2 patients were managed early before the laparoscopy became our standard approach for the treatment of non parasitic benign solitary hepatic cyst and the 3rd one was recurrent cyst after a previous laparoscopic trial). Seven patients underwent laparoscopic deroofting but one of them was converted to open surgery to control bleeding from the edge of the cyst. The laparoscopic approach was done successfully in the other 6 patients. (Fig. 4)

The principle of both laparoscopic and open deroofting was the same, in both aspirations was done first and then according to the size and extension of the cyst:

1. Wide excision of the cyst wall was under taken leading to wide opening of the cystic cavity
2. Excision or destruction by electro cauterization of the endothelial lining of the cyst.
3. Omentoplasty was done in 7 cases to obliterate the cavity and reduce the incidence of recurrence, in these cases omentum was clipped or sutured to the edge of the excision margin.
4. Careful hemostasis was done in all cases to control bleeding either by electro cautery in most cases; except 2 cases needed over running suture with 3/0vicryl
5. Intra-abdominal tube drain was placed in all cases and was removed from 2-5 days after the operation.
6. In all cases the excised cystic wall and the aspirated fluid were sent for pathological and cytological analysis.

Follow up:

All patients were examined 2 weeks after discharge and then every three months for the period of the study. Postoperative ultrasonography was done for all patients at 3 month post operatively

RESULTS

Males were 20% (2/10) and females were 80% (8/10) with female to male ratio 4:1 of the study group. Age was ranged from 1 year to 72 year with a median of 15 years. Four cases were in the pediatric age.

With respect to clinical presentation, 70% were suffering from upper abdominal pain and discomfort, while 30% complained mainly from right sided abdominal swelling. The duration of the presenting symptoms varied from 5 months to 18 months before management. Three patients (30%) had a history of recurrent cyst (one after laparoscopic deroofing and the other two after repeated trials of aspiration and alcohol injection). Table 1

All patients in our study presented with single cyst. Right sided cysts were the commonest (in 9 patients, 90%) and one patient had Left sided cyst. The diameter of the cyst varied from 9-18 cm with median of 12.5 cm on ultrasonography. Open surgery was done only in 3 patients while 7 patients underwent laparoscopic deroofing, but one of them was converted to open surgery to control bleeding from the edge of the cyst. The laparoscopic approach was done successfully in the other 6 patients. Table 2

The operative time ranged from 90min to 145 min with (mean 110±14 min). The laparoscopic approach was shorter in duration in comparison to open surgery while the recurrent cysts and converted operation were the longest. Hospital stay ranged from 3 to 10 days with shorter stay was reported in the laparoscopic approach. The abdominal drain was left for 2-5 days except one patient removed after 10 days due to prolonged drainage of serous discharge. Table 3

As regard the early postoperative complications, surgical site infection (SSI) was reported in 2 patients (20%) (One open and the other in the converted operation) While prolonged drainage of serous discharge was reported in one patient.

The follow up period was between 12 - 72 months (median 20 months).

Asymptomatic recurrence (n=2) was detected with abdominal ultrasonography during the follow up period (3, 4 cm in diameter) which didn't need further intervention.

Incisional hernia was reported in one patient with a history of SSI. Table 4

In all patients, the histopathological examination (Fig. 5) revealed simple benign non parasitic hepatic cyst

and the cytological examination was negative for either malignant or hydatid diseases.

Table 1: Symptoms and clinical presentation:

Clinical presentation	N (%)
Upper abdominal Pain	7 (70%)
Abdominal Swelling	3(30%)
Recurrent cyst	3(30%)

Table 2: Operative results:

Operative data	N (%)
Site of cyst	
- RT side	9(90%)
- LT side	1(10%)
Size of cyst	
- Large (>10cm)	7(70%)
- Small (<10cm)	3(30%)
Type of operations	
- Laparoscopic surgery	7(70%)
- Open surgery	3(30%)
- Converting operation	1(10%)

Table 3: Early postoperative data:

Operative time	90- 145 min (mean 110±14 min)
Hospital stay	3-10 days
Drain removal	2-5 days

Table 4: Early and late post-operative complications:

Complication	N (%)
Early	
-Surgical site infection	2(20%)
-Partial wound disruption	1(10%)
Late	
-Incisional hernia	1(10%)
-Recurrence cyst	2(20%)

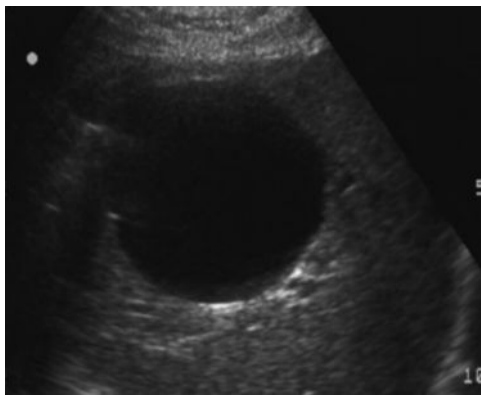


Fig. 1: Abdominal U/S of solitary simple hepatic cyst

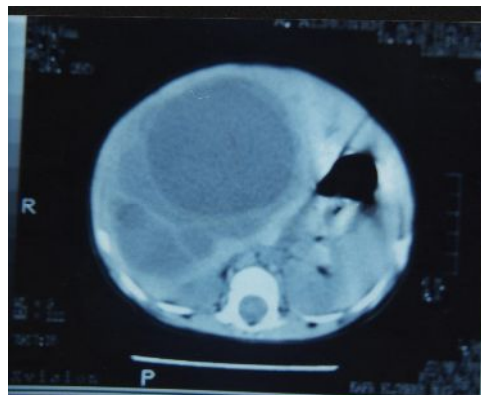


Fig. 2: Abdominal CT of huge simple hepatic cyst

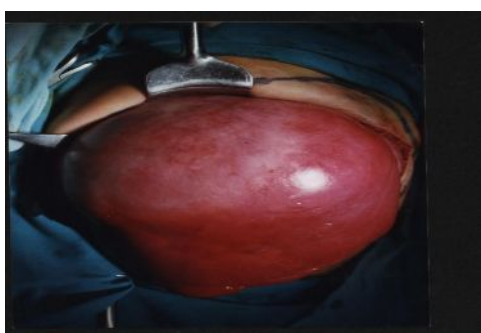

Fig. 3. A: Rt. Side simple hepatic cyst

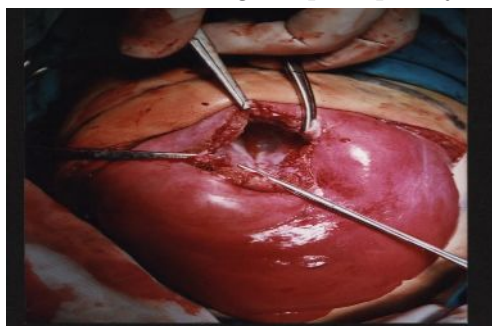


Fig. 3. B: deroofing of the cyst

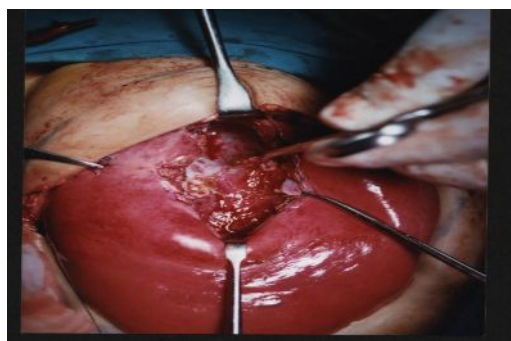


Fig. 3. C: Excision of the endothelial layer

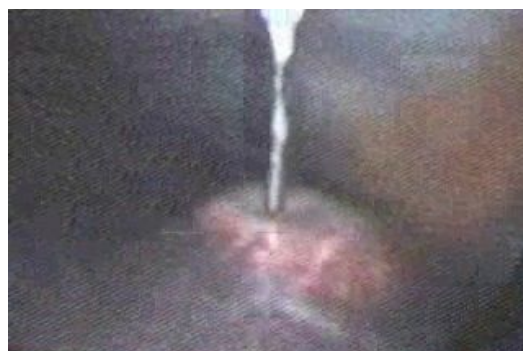

Fig. 4.A: Starting aspiration of the cystic fluid

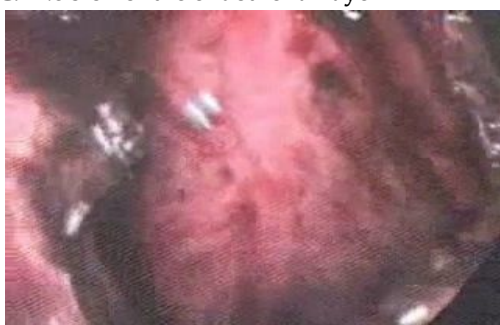

Fig. 4.B: Complete deroofing of the cyst

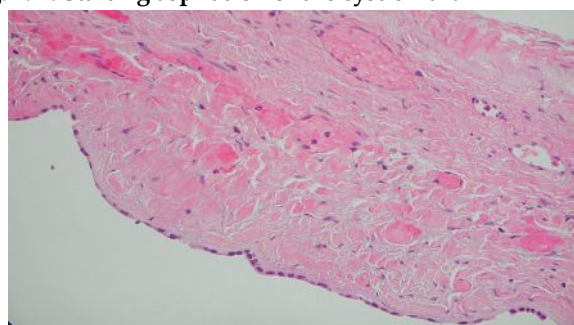


Fig. 5: Histopathologically simple hepatic cyst is lined by simple cuboidal epithelium

DISCUSSION

The true incidence of benign hepatic non-parasitic cysts is difficult to be estimated as it is usually asymptomatic, however, recently some advocated that the incidence range between 1 - 5% with increasing of incidence with age and being slightly more common in females¹⁰. Although the age of presentation is commonly late in life, a giant hepatic cyst was diagnosed in utero and some cases had been diagnosed and managed in newborns and infants^{11, 12}. Our study included 10 patients with simple non-parasitic hepatic cyst with age ranged from 1 year to 72 years, four of them were in the pediatric age and they were diagnosed and managed early with successful results and good long term follow up.

Simple hepatic non-parasitic cysts are often asymptomatic and therefore don't require treatment while the symptomatic cases are usually related to the size and location of the cyst and may be caused by compression of nearby structures¹³. Symptoms are usually vague and may be in the form of abdominal pain, nausea, vomiting, or dyspnea. There may be a palpable abdominal mass. Although it is easy to attribute symptoms to the presence of a large cyst, the possibility of a coexisting pathology must be excluded before intervention. In other words, conditions associated with upper abdominal pain such as peptic ulcer disease, cholecystolithiasis, intra abdominal abscesses or tumors must be ruled out before symptoms are attributed to hepatic cysts^{14, 15}. All of our patients were symptomatic and the most common complaint was upper abdominal pain in 70% which was matched with the results of other studies. Three patients presented with huge abdominal swelling. All patients were subjected to full clinical examination to exclude the coexisting pathology before dealing with the simple hepatic cyst

Most previous studies on hepatic cysts considered abdominal ultrasonography as the first diagnostic method because it is noninvasive, readily available, sensitive and cost-effective imaging technique, Also it is helpful for defining the number and location of the cysts as well as the internal structure of these cysts. The specificity is in the range of 90-95%^{12, 13, 16}. Others considered abdominal CT the diagnostic method of choice as it is more accurate than ultrasonography and it provides more detailed information about the location and the depth of the cyst in the liver.¹⁷ In our study, we considered CT as the most reliable diagnostic method in the management of the liver cyst as it was very accurate in the detailed information about the exact location

and depth of the cyst and detected the relation to nearby structures, so playing an important role in planning the approach of surgery, especially the laparoscopic approach. However, we performed abdominal ultrasonography as a routine investigation for all patients and were used for regular follow up to aid in early detection of any recurrence.

As regard the histological and morphological study of the cysts, all patients had a single cyst with a mean diameter of 12.5 cm and 90% were located in the right lobe of the liver. Also all cysts were benign in nature, unilocular and all lined by simple cuboidal epithelium. These results were matched with Garcea et al and Giuliante et al in their series on the management of simple hepatic cysts, they found that, cysts were frequently non-parasitic, simple, solitary, fluid-filled spaces within the liver and lined by cuboidal epithelium. Ninety percent are unilocular and most are in the anterior segment of the right lobe.^{18, 19}

Different treatment modalities have been used for simple hepatic cysts. Simple aspiration of the cyst has been abandoned as the recurrence rate is reported to approach 100% within a short time. There are several reports with different results using needle aspiration in combination with sclerotherapy with alcohol, minocycline/tetracycline hydrochloride or ethanol²⁰⁻²⁴. However, no published data exist regarding the toxic effect of this type of treatment on the liver. Nevertheless, treatment by needle aspiration and sclerotherapy seems to be a valid alternative to surgery, mainly in surgical risk patients. In our study, two cases were presented as recurrent cysts after repeated trials of needle aspiration, one of them with alcohol injection and were managed successfully by laparoscopic deroofing.

Surgical treatment of simple hepatic cysts consists of deroofing or complete excision of the cyst. Excision is associated with a higher morbidity rate than deroofing, therefore, should be reserved for polycystic liver disease or symptomatic recurrence after a deroofing procedure²⁵. Deroofing is considered the treatment of choice for benign non-parasitic hepatic cysts as cysts requiring treatment are almost always large and close to the surface of the liver, therefore deroofing is technically easy. Also, deroofing results in maximum sparing of the liver, as no liver tissue is resected²⁶. In our study, deroofing either open or laparoscopic was the standard approach, in both we tried to make wide and well drained opening to keep the cystic cavity open to avoid the recurrence.

Hansen et al found that the omentoplasty, as well as

over sewing the margins of the cyst after deroofting, reduced the incidence of recurrence²⁷. The omentum is thought to reabsorb fluid which may be produced by the residual endothelium, which may not be completely removed²⁸. In our study, we made omentoplasty in 7 cases. The omentum was used to obliterate the cystic cavity to decrease the incidence of recurrence.

As symptom relief and recurrence rate after laparoscopic deroofting appear to be similar to the open approach, but with less morbidity, earlier recovery, and shorter hospital stay, the laparoscopic approach is considered the gold standard for the management of simple hepatic cysts²⁹⁻³⁴. . Martin et al emphasized at proper selection of truly symptomatic patients with simple hepatic cysts for surgical intervention and concluded that laparoscopic deroofting gave the best results when used in its appropriate place and that open deroofting should be reserved for cysts that are inaccessible by laparoscopy³⁵.

Long term follow up after deroofting showed good results and high patient satisfaction, even when recurrence occurred as it remained asymptomatic in most cases³⁶. Seven of our patients were treated by laparoscopic deroofting and 3 were managed by open deroofting with asymptomatic recurrence in 2 cases.

CONCLUSION

Simple, solitary, non-parasitic hepatic cysts are often asymptomatic and therefore do not require treatment. Surgical treatment is indicated for symptomatic cases and in doubtful diagnosis. Laparoscopic deroofting of simple hepatic cyst is the standard treatment with minimal morbidity and good long term follow up. Open deroofting is reserved for cysts inaccessible by laparoscopy. Incomplete deroofting or presence of multiple cysts is the main cause of recurrence .

REFERENCES

1. Civello IM, Matera D, Maria G, et al. Laparoscopic fenestration of symptomatic non-parasitic cysts of the liver. *Hepatogastroenterology* 52:849-51, 2005
2. Till H, Schuster T, Boehm R, et al. Laparoscopic resection of a congenital liver cyst and simultaneous closure of a diaphragmatic defect in a 5-month-old infant. *Surg Endosc* 17:520, 2003
3. Arnold HL, Harrison SA. New advances in evaluation and management of patients with polycystic liver disease. *Am J Gastroenterol* 100:2569-82, 2005.
4. Katkhouda N, Mavor E. Laparoscopic management of benign liver disease. *Surg Clin North Am* 80:1203-11, 2000.
5. Schachter P, Sorin V, Avni Y, et al. The role of laparoscopic ultrasound in the minimally invasive management of symptomatic hepatic cysts. *Surg Endosc* 15:364-7, 2001
6. Diez J, Decoud J, Gutierrez L, et al. Laparoscopic treatment of symptomatic cysts of the liver. *Br J Surg* 85:25-7, 1998
7. Taylor BR, Langer B. Current surgical management of hepatic cyst disease. *Adv Surg* 31:127-48, 1997
8. Cherqui D, Husson E, Hammoud R, et al. Laparoscopic liver resections: a feasibility study in 30 patients. *Ann Surg* 232:753-62, 2000
9. Gloor B, Ly Q, Candinas D. Role of laparoscopy in hepatic cyst surgery. *Dig Surg* 19:494-9,2002
10. Beecherl EE, Bigman DL, Langer B: cystic disease of the liver. In; Zuidema GD, Yeo CJ eds. *Shakelford's Surgery of the Alimentary Tract*, 5th ed. Philadelphia, WB Saunders Co. pp 447-60, 2002.
11. Tsao K, Hirose S, Sydorak R, et al. Fetal therapy for giant hepatic cysts. *J Pediatr Surg* 37:E31, 2002
12. Quillin SP, McAlister WH. Congenital solitary nonparasitic cyst of the liver in a newborn. *Pediatr Radiol* 22:543-4, 1992
13. Sanchez H, Gagner M, Rossi RL, et al. Surgical management of nonparasitic cystic liver disease. *Am J Surg* 161:113-8, 1991
14. Kaul V V, FriedenberG F, Rothstein KD. Hepatic Cysts. *Curr Treat Options Gastroenterol* 3:439-444, 2000
15. Klingler PJ, Gadenstätter M, Schmid T, et al. Treatment of hepatic cysts in the era of laparoscopic surgery. *Br J Surg* 84:438-44, 1997
16. Gaines PA, Sampson MA. The prevalence and characterization of simple hepatic cysts by ultrasound examination. *Br J Radiol* 62:335-7, 1989
17. Mortelé KJ, Ros PR. Cystic focal liver lesions in the adult: differential CT and MR imaging features. *Radiographics* 21:895-910, 2001
18. Garcea G, Pattenden CJ, Stephenson J, et al. Nine-year single-center experience with nonparasitic liver cysts: diagnosis and management. *Dig Dis Sci* 52:185-91, 2007

19. Giuliani F, D'Acapito F, Vellone M, et al. Risk for laparoscopic fenestration of liver cysts. *Surg Endosc* 17:1735-8, 2003 Epub 2003 Jun 17.
20. Koperna T, Vogl S, Satzinger U, et al. Nonparasitic cysts of the liver: results and options of surgical treatment. *World J Surg* 21:850-4, 1997
21. Moorthy K, Mihssin N, Houghton PW. The management of simple hepatic cysts: sclerotherapy or laparoscopic fenestration. *Ann R Coll Surg Engl* 83:409-14, 2001
22. Simonetti G, Profili S, Sergiacomi GL, et al. Percutaneous treatment of hepatic cysts by aspiration and sclerotherapy. *Cardiovasc Intervent Radiol* 16:81-4, 1993
23. Erdogan D, van Delden OM, Rauws EA, et al. Results of percutaneous sclerotherapy and surgical treatment in patients with symptomatic simple liver cysts and polycystic liver disease. *World J Gastroenterol* 13:3095-100, 2007
24. Blonski WC, Campbell MS, Faust T, et al. Successful aspiration and ethanol sclerosis of a large, symptomatic, simple liver cyst: case presentation and review of the literature. *World J Gastroenterol* 12:2949-54, 2006
25. Gigot JF, Legrand M, Hubens G, et al. Laparoscopic treatment of nonparasitic liver cysts: adequate selection of patients and surgical technique. *World J Surg* 20:556-61, 1996
26. Tocchi A, Mazzoni G, Costa G, et al. Symptomatic nonparasitic hepatic cysts: options for and results of surgical management. *Arch Surg* 137:154-8, 2002
27. Hansen P, Bhojrul S, Legha P, et al. Laparoscopic treatment of liver cysts. *J Gastrointest Surg* 1:53-9; discussion 59-60, 1997
28. Emmermann A, Zornig C, Lloyd DM, et al. Laparoscopic treatment of nonparasitic cysts of the liver with omental transposition flap. *Surg Endosc* 11:734-6, 1997
29. Z'graggen K, Metzger A, Klaiber C. Symptomatic simple cysts of the liver: treatment by laparoscopic surgery. *Surg Endosc* 5:224-5, 1991
30. Morino M, De Giuli M, Festa V, et al. Laparoscopic management of symptomatic nonparasitic cysts of the liver. Indications and results. *Ann Surg* 219:157-64, 1994
31. Fiamingo P, Tedeschi U, Veroux M, et al. Laparoscopic treatment of simple hepatic cysts and polycystic liver disease. *Surg Endosc* 17:623-6, 2003
32. Fabiani P, Iannelli A, Chevallier P, et al. Long-term outcome after laparoscopic fenestration of symptomatic simple cysts of the liver. *Br J Surg* 92:596-7, 2005
33. Robinson TN, Stiegmann GV, Everson GT. Laparoscopic palliation of polycystic liver disease. *Surg Endosc* 19:130-2, 2005
34. Katkhouda N, Hurwitz M, Gugenheim J, et al. Laparoscopic management of benign solid and cystic lesions of the liver. *Ann Surg* 229:460-6, 1999
35. Martin IJ, McKinley AJ, Currie EJ, et al. Tailoring the management of nonparasitic liver cysts. *Ann Surg* 228:167-72, 1998
36. Zacherl J, Scheuba C, Imhof M, et al. Long-term results after laparoscopic unroofing of solitary symptomatic congenital liver cysts. *Surg Endosc* 14:59-62, 2000.