



## Anterior Urethral Advancement in Repair of Hypospadias: A Modification of the Technique

M.M.El-Saadi, Adel M. Tolba, Abd-Elrahman Sarhan

Department of General Surgery, Zagazig University

**Background/Purpose:** Anterior Urethral advancement as one stage technique for hypospadias repair was first described by Ti - Shang Cheng in 1984. It was used for repair of distal and midpenile hypospadias. It was also used for treating secondary cases and urethral fistulae. Stricture, fistulae and ventral curvature were among the complications that faced surgeons on applying the original technique.

**Materials & Methods:** In the period between March 1997 and December 2008, 140 patients with distal penile hypospadias or anterior urethral fistula were treated with anterior urethral advancement technique with certain modifications.

**Results:** The usual complications of the technique (ventral curvature of the penis, urethral fistula and meatal stenosis) were avoided.

**Conclusion:** This study represents certain modifications that helped to a great extent in improving the results and prevented stricture and fistula formation.

**Index Word:** Hypospadias, fistula, urethral advancement.

### INTRODUCTION

Hypospadias is a common developmental anomaly which affects approximately 1 per 300 live male births<sup>1</sup>.

Urethral reconstruction represents a great challenge in urological surgery. No method is appropriate for all types of repair. Therefore, approximately 200 urethral repair techniques have been developed mainly for hypospadias treatment<sup>2</sup>.

Anterior urethral advancement as one stage technique for repair of hypospadias and urethral fistula is an excellent idea that was first applied by Ti - Sheng Chang in 1984<sup>3</sup>. He realized that the extent of urethral advancement after mobilization (in children up to 1.8 to 2 cm and in adult 4.5 -5.0 cm), was sufficient to repair the penile variety of congenital hypospadias.

We used this technique for repair of coronal and distal penile hypospadias and fistulae. The complications faced by the Chang as stricture, fistulae and ventral curvature were avoided by application of some modifications on the technique.

### PATIENTS AND METHODS

A total of 140 patients with a mean age of 3 years (range from 2 years to 18 years) were treated in our unit during the period between March 1997 and December 2008 by the modified anterior urethral

advancement technique for distal hypospadias (120 patients) and anterior urethrocutaneous fistula (20 patients). The preoperative meatal sites or fistulae were coronal in 55 patients (39.2%), sub coronal in 45 patients (32.1%) and anterior penile in 40 patients (28.5%). Thirty five (25%) patients were circumcised. Chordee was present in 20 (14.2%) patients.

The general principles of repair for all our patients included minimal use of cautery, avoidance of tension on the repair and use of loop magnification. Follow up of the patients ranged from 2 months to two years.

#### ***Surgical technique:***

The technique described by Ti-Sheng Chang was applied with our modifications. Under epidural block anesthesia, a urethral catheter was inserted. An s-shaped skin incision was marked with methylene blue around the urethral opening and up to the middle part of the scrotum. The skin was then incised with a pointed knife and with the catheter as a guide, a meticulous dissection was performed to free the two penile skin flaps from the spongy urethra which was then dissected and mobilized from the groove formed by the two corpora cavernosa of the penis starting at the midpenile area. Special care should be taken during the dissection to avoid injury to corpora cavernosa, that may cause troublesome bleeding, or accidental penetration into the spongy urethra. The urethra should be freed as far as the mid portion of the bulbar urethra in such a way that the isolated spongy urethra, with the catheter in place, can be advanced to the tip of the glans penis after trimming of the distal end in oblique manner to reach the normal spongy urethra. Thorough release of the chordee was achieved by meticulous excision of all the remaining fibrous bands. The mobilized urethra was then passed through a tunnel made in the glans penis and the urethral opening was sutured to the opening made on the glans penis.

#### ***We introduced the following modifications:***

1- The technique was used only in distal penile hypospadias and distal penile fistulae, thus avoiding the use of distal skin paddle that is the cause of both stricture and fistula formation due to distal ischemia and distal necrosis.

2- Dissection of the spongy urethra has to start at the mid penile area proximal to the meatus or the fistula site. This will enable the surgeon to accurately identify the exact plane between the spongy urethra

and corpora cavernosa. This clean and clear dissection avoids both bleeding and injury to delicate layer of fascia that envelop the corpora cavernosa. Dissection into the exact plane is easy and rapid both distally and proximally. Chordee were removed completely and accurately by dissecting them out in the same plane of dissection.

3- The distal end of the advanced urethra was trimmed to the site of the normal meatus. This will help support good distal vasculature and perfect distal healing. The trimming of the distal end of the advanced urethra is done in an oblique manner making the distal end wider and less liable for stricture formation.

## **RESULTS**

Early post operative complications: postoperative bleeding occurred in two patients (1.4%), wound infection occurred in four patients (2.8%), and perpetual edema occurred in 14 non circumcised patients (10%). All of these complications were treated conservatively with satisfactory results.

The long-term outcome was satisfactory in regards of functional and cosmetic aspects (The patients were found to have normal caliber of the external urethral meatus which was located at the tip of the glans penis, voiding through it and they were found to have a good urine stream). There were no fistulae, or meatal stenosis.

**Table 1: Post operative complications:**

<b>Early complications</b>	
Bleeding	2 (1.4%)
Wound infection	4 (2.8%)
Preputal edema	14 (10%)
<b>Late complications</b>	
Fistula	0
Meatal stricture	0

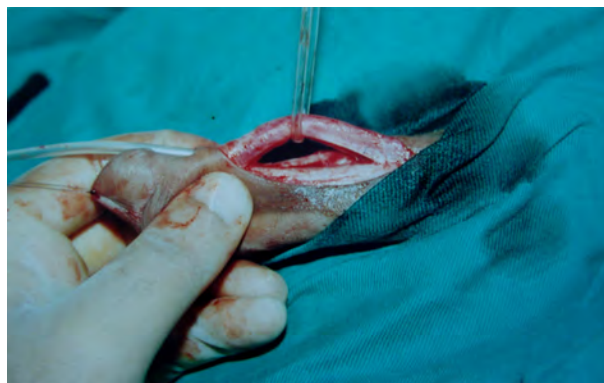
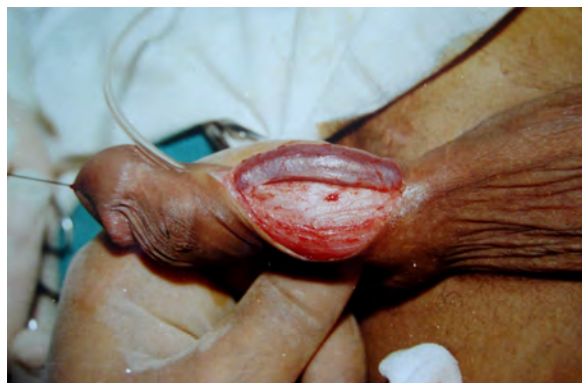
Fig. 1: Dissection starts at the mid penile area, The spongy urethra is dissected both distally and proximally

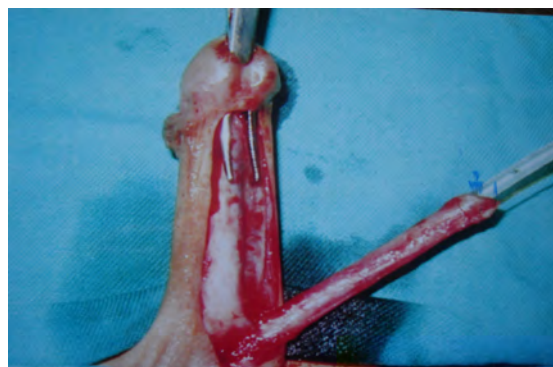
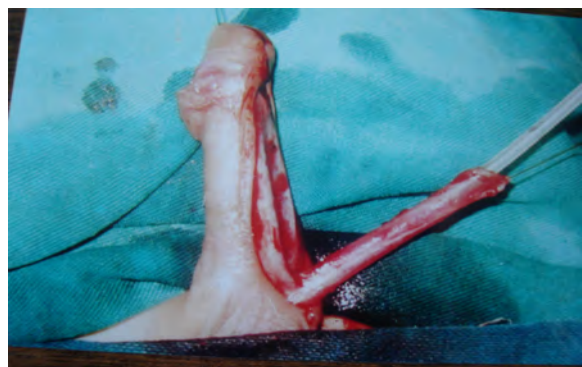

Fig. 2: The tunnel in the glans was performed after trimming of the distal end of the urethra to reach the spongy vascular part.

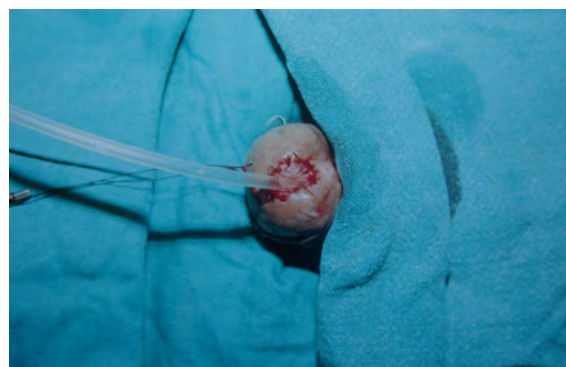
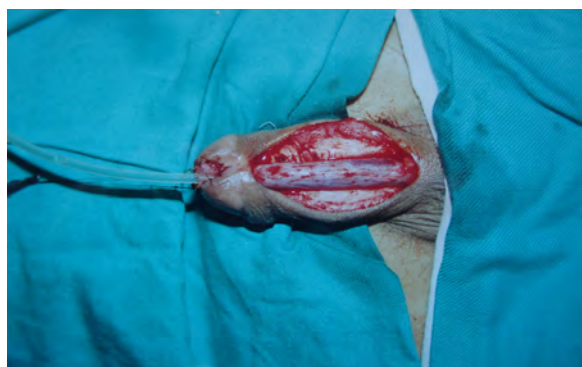
Fig. 3: The urethral end is sutured to the opening at the tip of the glans penis

## DISCUSSION

There are hundreds of procedures described for repair of hypospadias, none of these procedures can

be universally applied for all types. <sup>4</sup>

The urethral advancement as a one stage technique for repair of hypospadias is considered a good technique. However, lack of surgical experience and

early bad reputation of being a cause of ventral curvature resulted in avoiding the operation by most surgeons in favor of other techniques. However, limitation of the technique for coronal, sub coronal and anterior penile hypospadias with a maximum distance of about 1.5 cm as reported by El Saadi (1994) avoids these ventral curvatures<sup>5</sup>.

Urethrocutaneous fistula is the most common complication of the surgical techniques of hypospadias repair. The incidence of fistula formation has decreased gradually in the past two decades and its incidence can be used to judge the success of hypospadias repair<sup>6</sup>. Urethral advancement for distal hypospadias repair has a variable incidence of fistula from less than 1% to 16.7%<sup>7-8</sup>. Fistula occurrence could be attributed to ischemic necrosis at the distal end of the urethra due to reduction of the blood supply at the dystopic urethral meatus, or due to poor healing at the neourethra between the skin around the urethral meatus and that of the glans penis. With the modification described, excision of the unhealthy distal 2 mm of the urethra and also suturing of the healthy distal end of the urethra to the tip of the glans penis may be the reason of absence of any postoperative fistula.

Meatal stenosis is a complication that occurs when the meatus is brought to the tip of the glans penis. While Duckett<sup>2</sup>, reported that meatal stenosis could be avoided by creating a generous channel through the glans, excising tissue to make space to lay the neourethra. We think that trimming the distal end of the urethra in oblique manner makes it wider and less liable for stricture formation, and we did not encounter this complication among cases of this study.

So, The modifications added to Anterior urethral advancement technique prevent long term complications. The technique can be applied for distal hypospadias and anterior urethrocutaneous fistula in

circumcised and non circumcised patients with or without chordee.

## CONCLUSION

Modified anterior urethral advancement technique can be applied for distal hypospadias and anterior urethrocutaneous fistula with excellent cosmetic and functional results with least complications .

## REFERENCES

1. Backus HL, De Felice C.A.: Hypospadias, then and now. *Plast. Reconstr. Surg* 25: 147, 1960
2. Duckett JW. Hypospadias. *Clin. Plast. Surg* 7:149, 1980
3. Ti Sheng Chang. Anterior urethral advancement; a one-stage technique for hypospadias repair. *Br J Plast Surg* 37:530-535, 1984
4. Landau EH, Gofrit ON, Merety KS. Outcome analysis of the tunica vaginalis flap for the correction of urethrocutaneous fistula in children. *J Urol* 128:285-286, 1982
5. El-saadi MM. Anterior urethral advancement technique for repair of hypospadias, Experience with 55 patients. *Zagzig Med. Assoc J* 7(1):31-37, 1994
6. Retik AB, Keating AM, Mandell J :Complications of hypospadias repair. *Urol Clin North Am*15:223-236, 1988
7. Koff SA. Mobilisation of the urethra in the surgical treatment of hypospadias. *Urol* 125:394-397, 1981
8. Spence JR, Permuter AD. Sleeve advancement in distal hypospadias repair. *J Urol* 144:523-525, 1990.