

Bipolar diathermy as another method for testicular vascular division in laparoscopic two-stage Fowler–Stephens orchidopexy: a retrospective study

Hamdan H. Alhazmi

Objective The current study assessed the outcome of the two-stage laparoscopic Fowler–Stephens orchidopexy (LFSO) for intra-abdominal testis (IAT). Testicular blood vessels were divided by two different methods, bipolar diathermy or the conventional clipping method.

Summary background data The shortness of testicular vessels may play a role in making the surgical approach in IAT a technical challenge and can hinder the dragging of the testicles to the scrotum.

Patients and methods We reviewed 31 records of pediatric patients who underwent operations for IAT between July 2010 and July 2017, using the two-stage LFSO. We evaluated methods used for dividing the testicular vessels in the first stage. We evaluated the intrascrotal position and testicular size. Success was defined as a nonatrophic, intrascrotal testis.

Results Two-stage LFSO was performed in 31 boys with 39 IAT. The mean age at the first stage was 32.18 months and at the second stage was 42.25 months. Two methods were used to divide the testicular vessels in the first stage of the LFSO, which were clipping by metallic clips (5 mm) in

25 testes and bipolar diathermy (3 mm) in 14 testes. With an average follow-up of 16 months, the preoperative volume was maintained in 97.43% of the testes, whereas 94.87% of the testes were intrascrotal. One testicular atrophy was reported in the clipping group. Two testicles were outside the scrotum within the bipolar coagulation group.

Conclusion Two-stage LFSO is safe and feasible. Bipolar diathermy could be used as an alternate method for dividing testicular vessels. *Ann Pediatr Surg* 14:218–221 © 2018 Annals of Pediatric Surgery.

Annals of Pediatric Surgery 2018, 14:218–221

Keywords: Fowler–Stephens, intra-abdominal testis, laparoscopic, laparoscopic Fowler–Stephens orchidopexy, nonpalpable testes, orchidopexy, pediatrics

Department of Surgery, Division of Urology, College of Medicine and King Saud University Medical City, King Saud University, Riyadh, Saudi Arabia

Correspondence to Hamdan H. Alhazmi, MBBS, SBU, ABU, Department of Surgery (37), Division of Urology, College of Medicine and King Saud University Medical City, King Saud University, PO Box 7805, Riyadh 11472, Kingdom of Saudi Arabia
Tel: +966 1467 1538; fax: +966 114 679 493; e-mail: drhamdan@ksu.edu.sa

Received 10 July 2018 accepted 29 July 2018

Introduction

Of the nonpalpable testes (NPT), 15–34.1% are inside the abdominal cavity and ~29–44.8% of those testicles are considered ‘high.’ They are poorly identified, and they are not amenable for management by simple laparoscopic orchidopexy [1,2]. Laparoscopy for NPT was accepted for the diagnosis of the disorder to confirm their absence and to detect their location, particularly in the absence of reliable imaging studies [3–5].

Laparoscopic or open exploration techniques are the conventional initial approaches to NPT as proposed by the American Urological Association guidelines [6]. The shortness of testicular vessels may play a role in making the surgical approach in intra-abdominal testis (IAT) a technical challenge and can hinder the dragging of the testicles to the scrotum [7]. Laparoscopic Fowler–Stephens orchidopexy (LFSO) entails the division of the testicular vasculature to gain adequate length, thus allowing for testis relocation in the ipsilateral hemiscrotum. Testicular viability depends on collateral circulation from the vessels of inguinal canal, hypertrophy of the artery of the vas, and gubernacular vessels [8,9].

It was only a matter of time before therapeutic laparoscopic orchidopexy became popular with the invention of the clip applicator for the stage I Fowler–Stephens procedure [10,11].

AbouZeid *et al.* [12] reported the safety of monopolar diathermy and demonstrated no histological differences

when using clip ligation in the first stage of the LFSO. We suppose that bipolar diathermy is safer than monopolar diathermy, reporting our experience with two-stage LFSO, and determining the safety and outcome of bipolar diathermy in vascular ligation.

Patients and methods

We conducted a retrospective study after approval from the Internal Review Board. All patients who had direct laparoscopic orchidopexy were excluded from analysis. We included all boys with IAT who underwent two-stage LFSO in the period from July 2010 to July 2017.

We reported demographic data, side, location, operative findings, and surgical complications. All the patients were examined again after the induction of anesthesia to ensure that the testis was nonpalpable. If the testis was nonpalpable, we proceeded to diagnostic laparoscopy. The urinary bladder was emptied by catheterization before the insertion of the trocars. The telescope was placed through a 5-mm open technique transumbilical port. When laparoscopy revealed an IAT, two 3-mm (if bipolar coagulation of the testicular vessels) or two 5-mm (if clipping of the vessels) working ports were placed under camera control in the midclavicular line at or just below the level of the umbilicus lateral to the rectus abdominis. The abdomen was inspected for the following structures: testicular vessels, vas deferens, testis, and internal inguinal ring.

We tried to test the mobility of the testis by pulling it toward the contralateral internal inguinal ring. All cases where the testis was at the ring or within 1 cm of the ring underwent vessel-intact laparoscopic orchidopexy, without division of the testicular vessels, whereas those testes which were 1 cm or more above the ring underwent a two-staged LFSO.

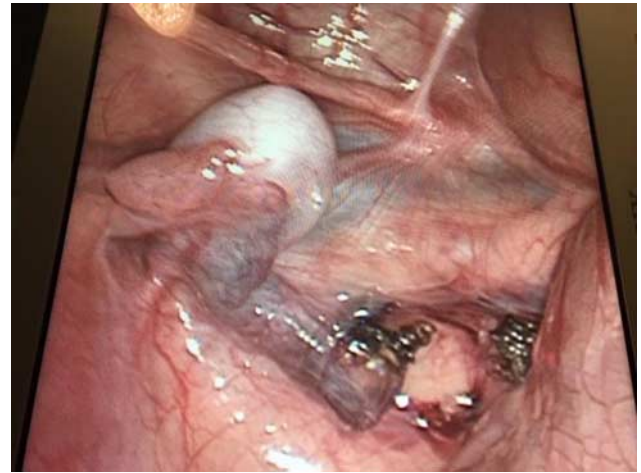
At the first stage, the spermatic vessels are mobilized minimally and doubly clipped proximally and distally at a site away from the testes using a 5-mm clip applicator or 3-mm bipolar diathermy, depending on the availability of each. With the bipolar diathermy, we induced coagulation in the same places where we put the clips. Then, we cut in between (Fig. 1).

The second stage of the surgery was scheduled ~4–6 months after the first stage. Here again, the same three-trocar approach was used using 3-mm instrument. The testis was again examined for size and consistency, and the vas was also examined for adequate neovascularization. The gubernaculum was pulled and divided far from testis only after visualizing the entry of the vas into the testicular pole. The testis and the vas with their peritoneal coverings were subsequently mobilized, preserving a broad peritoneal flap, based inferiorly along the vas. Once we could reach the opposite internal inguinal ring along with the testicles, it usually means that we have gained enough length to allow for an easy descent. Then, an ipsilateral subdartos pouch was created in a standard fashion and a long hemostat was passed through the scrotal incision to the peritoneal cavity on top of the pubic symphysis medial to the epigastric vessels and lateral to the urinary bladder wall. Then, it opened to create a path for the testis. The testis was grasped by the hemostat under direct visualization then pulled down into the subdartos scrotal pouch avoiding any twists or kinks. The patients were discharged the next day in both the stages on analgesics.

Follow-up was performed at 1, 3, 6, and 12 months postoperatively. During the follow-up, the testicular volume, consistency, and position in the scrotal sac were documented by clinical examination. Atrophy was diagnosed when the testis became fibrotic and hard with no detectable testicular tissue or blood flow on duplex ultrasound.


Data were analyzed using statistical package for the social sciences software (Released 2009, PASW Statistics for Windows, Version 18.0.; SPSS Inc., Chicago, Illinois, USA). We calculated the relative risk (RR), as well as odds ratio (OR) and stated the level of statistical significance at *P* value less than 0.005, to prove if a null hypothesis subedited before the establishment of the research is to be rejected or accepted. It also enables the detection of any statistically remarkable findings. We also calculated the confidence intervals (CI) to provide all information about the range in which the real values lie, with a definite degree of probability, and also the direction as well as the strength of the demonstrated effect. This allowed us to draw conclusions about the statistical reasonability and clinical significance of the study.

Fig. 1



Bipolar diathermy at the first stage in two-stage LFSO. LFSO, laparoscopic Fowler–Stephens orchidopexy.

Fig. 2



Position of testis in 39 patients.

Results

The study included 31 boys with 39 IAT who underwent two-stage LFSO between July 2010 and July 2017. Their ages ranged from 6 to 96 months (mean, 32.18 months) at the first stage and 12 to 108 months (mean, 42.25 months) at the second stage.

Of all 39 testes, 13 were unilateral with normal contralateral sides, eight were unilateral (managed by two-stage LFSO) with contralateral intracanalicular testis (managed by inguinal orchidopexy), and 18 were bilateral IAT (one was vanishing so nothing was done, whereas two-stage LFSO was done for the other 17 testes) (Fig. 2).

Bladder perforation was recognized intraoperatively in one patient. All patients were admitted for 1 day postoperatively. Follow-up ranged from 1 to 72 months, with an average of 16 months. We found two methods of dividing the testicular vessels in first stage of the LFSO, which was clipping by metallic clips in 25 testes (20 patients, with mean age of 30.15 months), whereas bipolar diathermy was used in 14 testes (11 patients, with mean age of 35.58 months).

Preoperative volume was maintained in 38 (97.43%) testes. Moreover, 37 (94.87%) testes were at the intrascrotal level except two testes. There was an overall success rate of 92.30 and failure of 3/39 (7.69%). When we analyzed the outcome according to the method of dividing the testicular vessels

Table 1 Relative risk and odds ratio comparing clipping and bipolar diathermy in terms of postprocedure testicular atrophy and site of testes

	Atrophy	No atrophy	Total	RR	P value	95% CI/Z statistic	OR	P value	95% CI/Z statistic
Clipping	1	24	25	1.7308	0.7318	0.0751–39.8654/0.343	1.7755	0.7304	0.0678–46.5242/0.345
Bipolar	0	14	14						
Total	1	38	39						
	Extrascrotal	Intrascrotal	Total	RR	P value	95% CI/Z statistic	OR	P value	95% CI/Z statistic
Clipping	0	25	25	0.1154	0.1540	0.0059–2.2472/1.426	0.0980	0.1434	0.0044–2.2002/1.463
Bipolar	2	12	14						
Total	2	37	39						

CI, confidence interval; OR, odds ratio; RR, relative risk.

and found one testicular atrophy in intrascrotal position (which was confirmed by color cobbler ultrasonography) in the clipping group (1/25, 4%), with RR of 1.7308, 95% CI of 0.0751–39.8654, and *P* value of 0.7318, whereas the OR was 1.7755, 95% CI of 0.0678–46.5242, and *P* value of 0.7304.

Two testicles were outside the scrotum with good size in the bipolar diathermy group (2/14, 14.28%), which was managed by redo inguinal orchidopexy, with RR of 0.1154, 95% CI of 0.0059–2.2472, and *P* value of 0.1540, whereas the OR was 0.0980, 95% CI of 0.0044–2.2002, and *P* value of 0.1434 (Table 1).

Discussion

Of the NPT, 15–34.1% are inside the abdominal cavity and ~29–44.8% of those testicles are considered 'high.' They were poorly identified and cannot be managed by simple laparoscopic orchidopexy [1,2]. We found that left-side IAT was more prevalent than right-side IAT. Associated comorbidities were more likely among bilateral IAT, such as prune belly syndrome, cardiac anomalies, and genitourinary anomalies. This was identical to the reported findings [8,9].

The surgical approach for IAT is technically challenging because testicular vessels may be too short to allow the testicles to be dragged to the scrotum. In 1959, Fowler and Stephens [13] proposed a new technique, and their idea was based on dividing the testicular vessels to gain adequate length while getting the blood supply from collateral circulation, the 'artery of the vas.' In 1984, Ransley *et al.* [14] modified this technique and performed it in two stages.

For the past 30 years, laparoscopy has been considered as the gold standard procedure for the assessment and management of boys with NPT [15]. Primary orchidopexy is preferred when the length of intra-abdominal testicular vessels is adequate. However, the presence of short intra-abdominal testicular vessels is a real challenge [16–20]. Bagga and colleagues noted that the length of the vas is associated with a higher testicular position from the internal ring. This, in turn, will facilitate the success of the outcome of the LFSO procedure. Consequently, high testicular position is favored for successful scrotal placement in LFSO procedures [21].

The clipping of the testicular vessels in stage I has no effect on the size and vascularity of the testis in stage II, as long as adequate time has elapsed before the second stage, so that collateral supply can sufficiently take over [10,12,21–23]. Law *et al.* [22] reported a 95% success rate in laparoscopically performed first-stage surgery, whereas

the second stage was performed via an open approach. Our success rate with the two-stage LFSO was 92.3%, which was the same as that reported by many recent series (94–95%) [24–26].

The greatest risk for all forms of laparoscopic orchidopexy include relative or complete testicular atrophy and testicular ascent [1,8,9,27,28], which were found in three testes in our study (one atrophy and two ascents in our study). The operated testis was always significantly smaller compared with the normal testis but was well vascularized [27]. Parents should be cautioned that nearly a quarter of IAT are smaller than the contralateral descended testes before surgery, for them to understand that not all size discrepancies may be due to the surgery [9].

Although clipping remained the standard method for performing LFSO in most centers, few authors thought of changing this method. In their report, Law *et al.* [22] explored techniques other than clipping for cosmetic and financial reasons, and they progressed to ligate the vessels with a free silk suture tied extracorporeally.

AbouZeid and colleagues reported that changing the method of transecting the testicular vessels did not alter the outcome (neither histologically nor macroscopically). They found no histologic differences between seven patients who underwent monopolar diathermy for ligation and 13 patients who underwent traditional clip ligation [12]. The harmonic scalpel can be used as another alternative method, but it is not available in small sizes (3 mm) and it is expensive. We used a 3-mm bipolar diathermy to achieve the same effects as the harmonic scalpel with a smaller size. When we used the bipolar diathermy, two testicles were extrascrotal with good size (2/14, 14.28%), which were managed by redo inguinal orchidopexy. We did not find any testicular atrophy. As opposed to the case in the clipping group, there was one testicular atrophy in the intrascrotal position (which was confirmed by color cobbler ultrasonography). We did not find studies evaluating the use of 3-mm bipolar diathermy as an alternative in dividing the testicular blood vessels in the first stage of the LFSO. We found that bipolar diathermy can be a simple and safe alternative to clipping in LFSO and can be more suitable for younger patients. However, there was no significant difference in successful outcome rates between the clipping and bipolar methods used in testicular vascular division in two-stage LFSO. This observation reflects postprocedure testicular size (atrophy) and postprocedure testicular site (intrascrotal or extrascrotal).

However, in terms of RR and OR, the bipolar modality showed superiority in postprocedure testicular size (atrophy) over the clipping method. In contrast, the clipping method showed excellence in postprocedure testicular site (intra-scrotal or extrascrotal) over the bipolar method.

The incidence of complications associated with laparoscopy in boys with NPT is rare. A recent study reported only one (0.2%) complication of 412 boys who had surgery for this pathology [29]. Bladder injury during creation of a transperitoneal tunnel for the testis medial to the medial umbilical ligament occurs in up to 3% of cases and may not always cause hematuria or be recognized intraoperatively [30]. We had one case of bladder injury recognized intraoperatively and was managed by insertion of urethral catheter for 10 days.

The current study was limited by its small sample size, the low power of the study, and the short duration of follow-up. Longer periods of follow-up and larger series will be needed to further validate the two-stage LFSO using bipolar diathermy for dividing testicular vessels.

Conclusion

Two-stage LFSO is safe and feasible. Bipolar diathermy (3 mm) could be used as an alternative method of dividing testicular vessels.

Conflicts of interest

There are no conflicts of interest.

References

- Baker LA, Docimo SG, Surer I, Peters C, Cisek L, Diamond DA, et al. A multi-institutional analysis of laparoscopic orchidopexy. *BJU Int* 2001; **87**:484–489.
- Papparella A, Romano M, Noviello C, Cobellis G, Nino F, Del Monaco C, Parmeggiani P. The value of laparoscopy in the management of non-palpable testis. *J Pediatr Urol* 2010; **6**:550–554.
- Hrebinko RL, Bellinger MF. The limited role of imaging techniques in managing children with undescended testes. *J Urol* 1993; **150**:458–460.
- Maghnie M, Vanzulli A, Paesano P, Bragheri R, Palladini G, Preti P, et al. The accuracy of magnetic resonance imaging and ultrasonography compared with surgical finding in the localization of the undescended testis. *Arch Pediatr Adolesc Med* 1994; **148**:699–703.
- Perović S, Janić N. Laparoscopy in the diagnosis of non-palpable testes. *Br J Urol* 1994; **73**:310–313.
- Kolon TF, Herndon CD, Baker LA, Baskin LS, Baxter CG, Cheng EY, et al. Evaluation and treatment of cryptorchidism: AUA guideline. *J Urol* 2014; **192**:337–345.
- Wayne C, Chan E, Nasr A. Canadian Association of Paediatric Surgeons Evidence-Base Resource. What is the ideal surgical approach for intra-abdominal testes? A systematic review. *Pediatr Surg Int* 2015; **31**:327–338.
- Alagaratnam S, Nathaniel C, Cuckow P, Duffy P, Mushtaq I, Cherian A, et al. Testicular outcome following laparoscopic second stage Fowler-Stephens orchidopexy. *J Pediatr Urol* 2014; **10**:186–192.
- Bracho-Blanchet E, Unda-Haro S, Ordorica-Flores R, Nieto-Zermeno J, Zalles-Vidal C, Fernandez-Portilla E, Davila-Perez R. Laparoscopic treatment of nonpalpable testicle. Factors predictive for diminished size. *J Pediatr Surg* 2016; **51**:1201–1206.
- Bloom DA. Tow-step orchidopexy with pelviscopic clip ligation of the spermatic vessels. *J Urol* 1991; **145**:1030–1033.
- Jordan G, Robey EL, Winslow BH. Laparoendoscopic surgical management of the abdominal transinguinal undescended testicle. *J Endourol* 1992; **6**:159–163.
- AbouZeid AA, Moussa MH, Shalaby MS, Safoury HS, El-naggar O, Hay S. Feasibility and safety of monopolar diathermy as an alternative to clip ligation in laparoscopic Fowler-Stephens orchidopexy. *J Pediatr Surg* 2012; **47**:1907–1912.
- Fowler R, Stephen FD. The role of testicular vascular anatomy in the salvage of high undescended testes. *Aust N Z J Surg* 1959; **29**:92–106.
- Ransley P, Vordermark J, Caldamaone A, Belinger M. Preliminary ligation of gonadal vessels prior to orchidopexy for the intra-abdominal testicle. *World J Urol* 1984; **2**:266–268.
- Docimo SG. The results of surgical therapy for cryptorchidism: a literature review and analysis. *J Urol* 1995; **154**:1148–1152.
- Denes FT, Saito FJ, Silva FA, Giron AM, Machado, Srougi M. Laparoscopic diagnosis and treatment of nonpalpable testis. *Int Braz J Urol* 2008; **34**:329–334.
- Moursy EE, Gamal W, Hussein MM. Laparoscopic orchidopexy for non-palpable testes: outcome of two techniques. *J Pediatr Urol* 2011; **7**:178–181.
- Singh RR, Rajimwale A, Nour S. Laparoscopic management of impalpable testes: comparison of different techniques. *Pediatr Surg Int* 2011; **27**:1327–1330.
- Stec AA, Tanaka ST, Adams MC, Pope JC 4th, Thomas JC, Brock JW 3rd. Orchidopexy for intra-abdominal testes: factors predicting success. *J Urol* 2009; **182**:1917–1920.
- Canavese F, Lala R, Valfrè S, Vinardi S, Bianco E, Cortese MG. Effectiveness of primary inguinal orchidopexy as treatment of non-palpable testes in the first two years of age. *Minerva Pediatr* 2010; **62**:245–248.
- Bagga D, Prasad A, Grover SB, Sugandhi N, Tekchandani N, Acharya SK, Samie A. Evaluation of two-staged Fowler-Stephens laparoscopic orchidopexy (FSLO) for intra-abdominal testes (IAT). *Pediatr Surg Int* 2018; **34**:97–103.
- Law GS, Pérez LM, Joseph DB. Tow-stage Fowler-Stephens orchidopexy with laparoscopic clipping of the spermatic vessels. *J Urol* 1997; **158**:1205–1207.
- Pascual JA, Villanueva-Meyer J, Salido E, Ehrlich RM, Mena I, Rajfer J. Recovery of testicular blood flow following ligation of testicular vessels. *J Urol* 1989; **142**:549–552.
- Burjonrappa SC, Al-Hazmi H, Barriera D, Barriera D, Houle AM, Franc-Guimond J. Laparoscopic orchidopexy: the easy way to go. *J Pediatr Surg* 2009; **44**:2168–2172.
- Radmayr C, Oswald J, Schwentner C, Neururer R, Peschel R, Bartsch G. Long-term outcome of laparoscopically managed nonpalpable testes. *J Urol* 2003; **170**:2409–2411.
- El-Anany F, Gad El-Moula M, Abdel Moneim A, Abdallah A, Takahashi M, Kanayama H, El-haggagy A. Laparoscopy for impalpable testis: classification-based management. *Surg Endosc* 2007; **21**:449–454.
- Esposito C, Vallone G, Savanelli A, Settini A. Long-term outcome of laparoscopic Fowler-Stephens orchidopexy in boys with intra-abdominal testis. *J Urol* 2009; **181**:1851–1856.
- Alam A, Delto JC, Blachman-Braun R, Wayne G, Mittal AG, Castellan M, et al. Staged Fowler-Stephens and single-staged laparoscopic orchidopexy for intra-abdominal testes: is there a difference? A single institution experience. *Urology* 2017; **101**:104–110.
- Esposito C, Lima M, Mattioli G, Mastroianni L, Centonze A, Monguzzi GL, et al. Complications of pediatric urological laparoscopy: mistakes and risks. *J Urol* 2003; **169**:1490–1492.
- Hsieh MH, Bayne A, Cisek LJ, Jones EA, Roth DR. Bladder injuries during laparoscopic orchidopexy: incidence and lessons learned. *J Urol* 2009; **182**:280–284.