

Onlay urethroplasty with unilateral paramental penopreputial flap: Mansoura modification of Koyanagi technique in the management of hypospadias without chordee

Adham Elsaied

Background/purpose One-stage urethroplasty with bilateral paramental foreskin flap was first described by Tomohiko Koyanagi for cases of severe hypospadias. He also introduced the onlay urethroplasty with unilateral paramental foreskin flap for distal hypospadias. Emir and colleagues in 2000 devised a modification of the bilateral Koyanagi repair of severe hypospadias. We in turn modified the (unilateral) Koyanagi technique for the repair of hypospadias without chordee. The aim of this study is to analyze the results of the Mansoura modification of the (unilateral) Koyanagi technique as a one-stage repair of hypospadias without chordee.

Patients and methods During the period from March 2013 to March 2015, 30 patients underwent treatment of hypospadias without chordee using the modified onlay urethroplasty with unilateral paramental penopreputial flap (modified unilateral Koyanagi technique).

Results The patients' age at the time of surgery ranged from 6 to 30 months. Sixteen cases had distal penile meatus, 10 had mid-penile meatus; and four had proximal penile meatus. The follow-up ranged from 3 months to 1 year. Primary success occurred in 28 (93%) cases with

Introduction

Hypospadias is a complex condition for which many surgical techniques have been devised [1]. Tubularized incised plate (TIP) urethroplasty has gained popularity in the treatment of hypospadias without chordee [2]. However, it is believed that the urethral plate may heal by fibrosis leading to stricture [3].

One-stage urethroplasty with paramental foreskin flap was first described by Tomohiko Koyanagi as a single-stage technique that is applicable to all types of proximal hypospadias with chordee [4]. The technique was modified to improve the blood supply to the neourethral flaps resulting in lower complication rates [5]. Koyanagi also introduced the onlay urethroplasty with unilateral paramental foreskin flap for distal hypospadias [6].

We devised our technique Mansoura modification of onlay urethroplasty with unilateral paramental penopreputial flap thus (Mansoura modification of unilateral Koyanagi) from the original and modified Koyanagi techniques, however using a unilateral instead of a bilateral paramental foreskin flap with preservation of the pedicle as well as the lateral blood supply.

Aim

This work aims at analyzing and evaluating the Mansoura modification of the unilateral Koyanagi technique (onlay urethroplasty with unilateral paramental penopreputial flap)

accepted cosmetic appearance. Complications occurred in two (7%) cases, in the form of urethrocutaneous fistula. There was no incidence of meatal stenosis nor recession, urethral stricture or flap necrosis.

Conclusion The Mansoura modification of the onlay urethroplasty with unilateral paramental penopreputial flap (unilateral Koyanagi) is applicable for all forms of hypospadias without chordee showing acceptable results. *Ann Pediatr Surg* 14:121–125 © 2018 Annals of Pediatric Surgery.

Annals of Pediatric Surgery 2018, 14:121–125

Keywords: hypospadias, modified Koyanagi, one-stage urethroplasty, onlay urethroplasty with paramental penopreputial flap, original Koyanagi

Department of Pediatric Surgery, Mansoura University, Mansoura, Egypt

Correspondence to Adham Elsaied, MD, PhD, Department of Pediatric Surgery, Mansoura University, Egypt, Mansoura University Children's Hospital, Gomhoria Street, Mansoura, 35516 Egypt
Tel: + 20 122 391 2996; fax: + 20 502 200 206; e-mail: adhamawe@yahoo.com

Received 26 March 2017 accepted 13 October 2017

in the repair of different degrees of hypospadias without chordee.

Patients and methods

The present study included 30 patients with hypospadias without chordee who were admitted to Mansoura University Children's Hospital during the period from March 2013 to March 2015. All cases had a distal penile, mid-penile, or proximal penile meatus. Patients with glanular hypospadias as well as those with penoscrotal or more severe types were excluded from our study. All our patients did not have chordee and none had previously undergone hypospadias surgery.

A written consent was taken from all parents after thorough information about the procedure was given. All patients were subjected to thorough clinical examination, routine laboratory investigations, and ultrasonography. Prophylactic antibiotics were given to all cases intraoperative and continued through the entire hospital stay in the form of ceftriaxone intravenous injection with a dose of 30 mg/kg.

We performed the Mansoura modification of onlay urethroplasty with unilateral paramental penopreputial flap thus (Mansoura modification of unilateral Koyanagi technique) for all our cases. During the follow-up, special interest was taken to calibration of the meatus and the urethral tube using Nelaton catheters.

Mansoura modification of unilateral Koyanagi technique

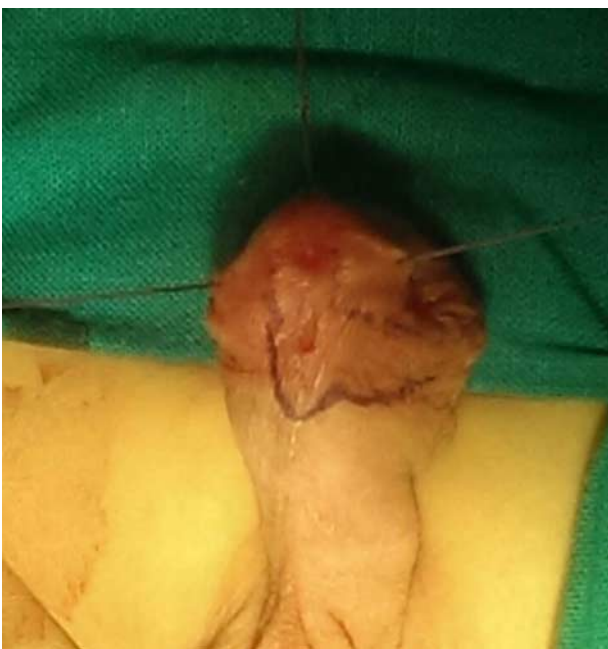The meatal-based yoke was outlined on one side only; starting the outlining of the incision on the right side of the urethral plate encircling the meatus proximally and extending to the left side taking an adequate length of the yoke proportional to the length of the tube proposed. Then the left part of the incision was outlined directly abutting the urethral plate and going to the left side once below the coronal sulcus to present the left part of the yoke flap (Fig. 1 and Diagram 1).

The left incision was made first (Fig. 2), which allows adequate control of the width of the lateral yoke flap (7–8 mm) defined by the right-sided incision. The right-sided incision was then made and complete harvest of the flap was done with preservation of both the pedicle and the lateral blood supply (Figs 3 and 4 and Diagrams 2 and 3).

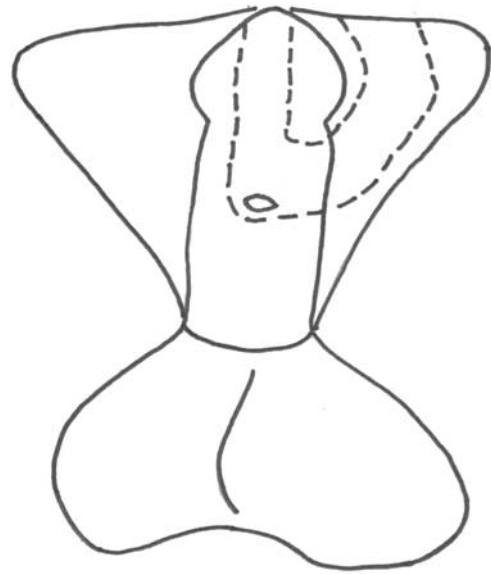
The penis was degloved circumferentially; glanular cleavage and creation of the glanular wings were performed. Then urethra was tubularized using 7/0 vicryl sutures along two lateral suture lines involving the two incisions (Fig. 5 and Diagram 4). A tunica vaginalis wrap was used as an intervening layer between the two suture lines. The glans was closed in two layers using 6/0 vicryl sutures. Then the penile shaft was covered by skin without compromising the lateral blood supply to the flap.

A 6-Fr feeding tube was used for diversion of urine and as a stent, and the repair was covered by sterile dressing. The urethral stent was removed 3 days postoperatively and the patient was discharged.

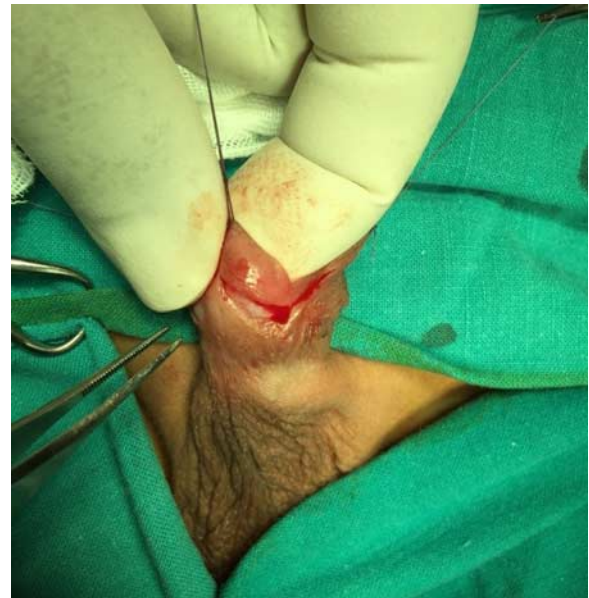The protocol of the study was accepted by the the IRB/ethical committee of Mansoura Faculty of Medicine (Code Number: R/17.06.75).

Fig. 1

Outlining the skin incisions of the flap.

Diagram 1

Outlining the skin incisions of the flap.

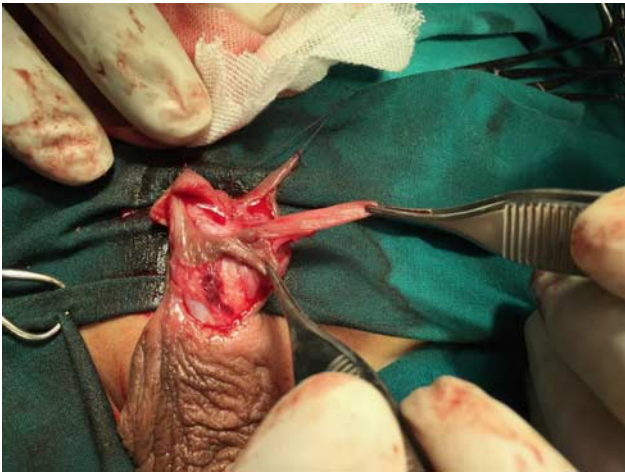Fig. 2

Harvesting the flap.

Results

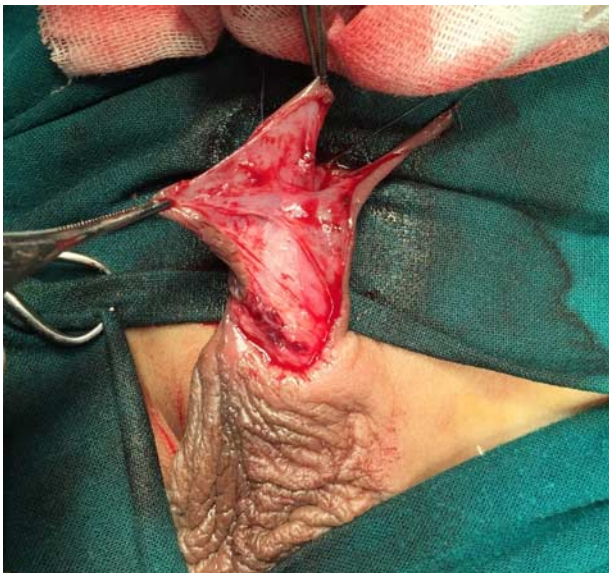Mansoura modification of the unilateral Koyanagi technique was used to treat 30 patients suffering from hypospadias without chordee. The patients' age at the time of surgery ranged from 6 to 30 months (mean: 20 months). Sixteen (53%) cases had distal penile meatus; 10 (33%) cases had mid-penile meatus; and four (14%) cases had proximal penile meatus. The operative time ranged from 90 to 120 min (mean 100 min). Most of the operative time was consumed in the harvest of the flap, which was found easier in cases of mid-penile and proximal penile hypospadias than in cases of distal

Fig. 3



Complete harvest of the flap.

Fig. 4

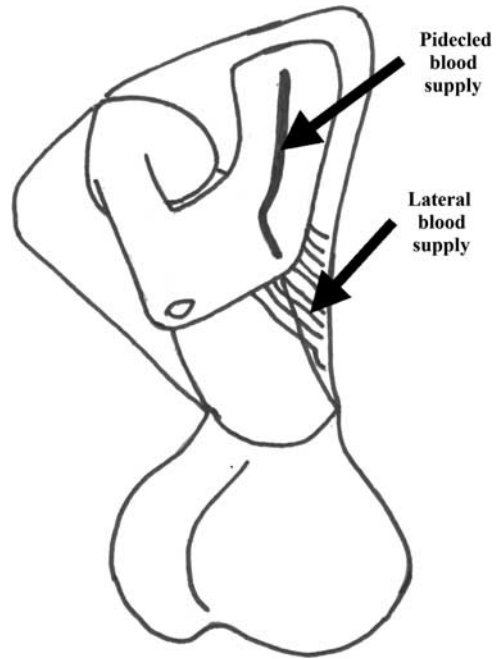


The lateral and pedicle blood supply of the flap.

hypospadias. The width of the flap in all our cases was 7–8 mm; however, the width of the urethral plate ranged from 3 to 9 mm (mean: 5 mm). The circumference of the urethral tube ranged from 11 to 16 mm (mean: 13 mm). The urethral tube was removed 3 days postoperatively in all cases and were all discharged on the fourth postoperative day.

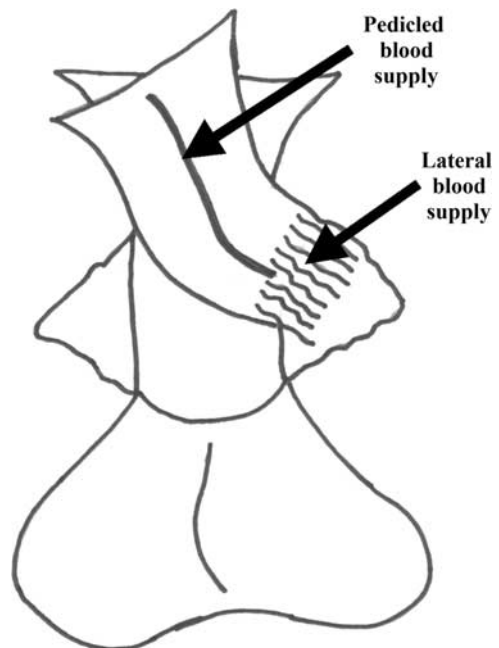
The follow-up ranged from 3 months to 1 year (mean: 9 months). They visited our outpatient clinic twice per week for 2 weeks, then weekly for a month, then every 2 weeks for 2 months, and then monthly for a year. The postoperative evaluation was mainly clinical, no dilatation was needed in any of the cases; however, gentle probing of the meatus and urethral calibration was done using Nelaton catheters 6–8 Fr 1 month postoperatively

Diagram 2



Harvesting the flap.

Diagram 3

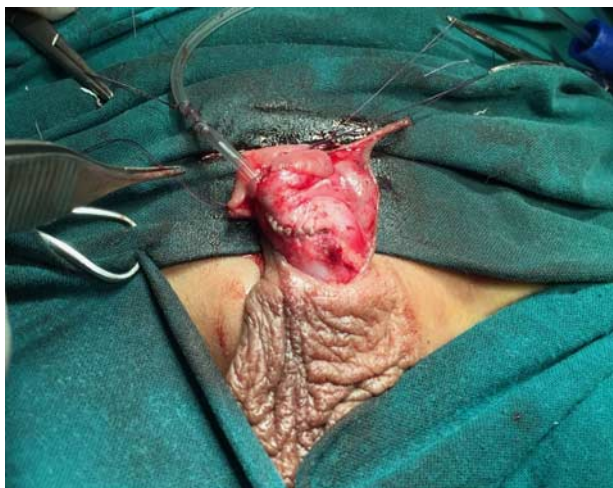

The lateral and pedicle blood supply of the flap.

and repeated monthly for 6 months to ensure that there was no meatal nor urethral stricture.

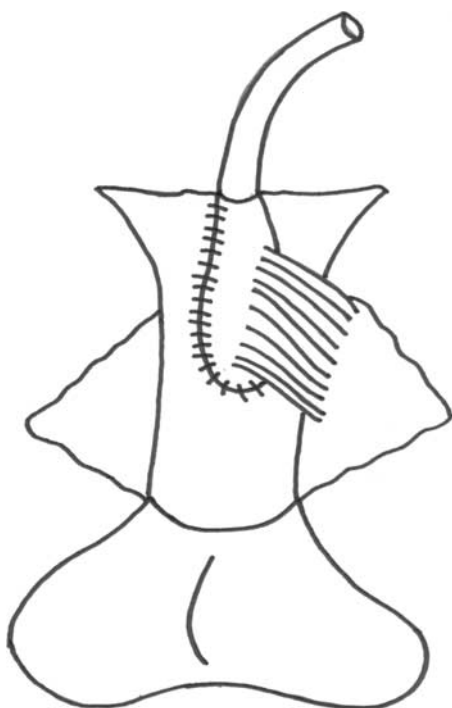
Primary success occurred in 28 (93%) cases with adequate parent satisfaction and accepted cosmetic appearance. Complications occurred in two (7%) cases, in the form of urethrocutaneous fistula. There was no incidence of

Fig. 5



Tubularization of the flap.

Diagram 4



Tubularization of the flap.

meatal stenosis nor recession, urethral stricture or flap necrosis.

The two cases with urethrocutaneous fistula occurred in the group of distal penile hypospadias and both needed an operation to close the fistula 6 months later.

Discussion

There are many novel techniques for the repair of hypospadias anomaly with different changes in patient management plans and the application of plastic surgical

principles that have improved the results. However, to the day surgeons agree that no single procedure has gained unanimous support [7]. We always assume that there is no such thing as a simple case of hypospadias; thus avoiding to use a minor repair in a major situation which will mostly result in complications. Preoperative planning is also essential to achieve the goals of the surgery [8].

All surgeons aim to achieve what is called a normal penis using different surgical techniques, but what is the standard and how do we measure against it? [9] Urethroplasties must necessarily walk a fine line between luminal stenosis and redundancy. The urethral reconstructions in babies and older boys are planned to have a circumference of 13–15 and 18–20 mm, respectively. Calibration with a 12–14-Fr Nelaton catheter is a useful gauge of patency at the completion of every case [10].

John Duckett was interested to know the limitations and exact measurements involved in the TIP urethroplasty from Snodgrass himself during a meeting a week before he died. He was concerned about the width of the urethral plate before and after the TIP incision [9]. We do not really know if Duckett would have shared our concerns regarding the TIP procedure. In our experience, we found that its main drawback is the incidence of postoperative meatal and urethral stenosis. This may be due to healing of the urethral plate incision by fibrosis causing these complications.

Snodgrass denies that the TIP urethroplasty procedure may be a cause of stricture urethra or meatal stenosis. He states that his technique gives the best cosmetic results having complication rates as low as 7% in many studies [9]. However, not all hypospadiologists share the opinion of Warren Snodgrass. During a meeting in Alexandria in 2016, I personally communicated with Hadidi [3] who shared my opinion of the possibility of stricture urethra and meatal stenosis after TIP urethroplasty. He backed this by a research he published in 2013.

Koyanagi *et al.* [4] devised a one-stage technique for the repair of proximal hypospadias with chordee. They harvested a bilateral paramental-based foreskin flap, which was handy in length but lacked the adequate blood supply. This resulted in a high rate of complications and many abandoned the technique [4]. Koyanagi *et al.* [6] also described the onlay urethroplasty with unilateral paramental foreskin flap for distal hypospadias.

Emir *et al.* [5] modified the Koyanagi technique in a brilliant manner harvesting the flap with preservation of the pedicle as well as the lateral blood supply which created a well-vascularized flap thus improving the results significantly. We tried the modified Koyanagi technique in cases of proximal hypospadias with chordee and we had a 90% success rate [11].

These results inspired us to harvest a unilateral paramental-based penopreputial flap with preservation of the pedicle as well as the lateral blood supply (Mansoura modification of the unilateral Koyanagi technique, which is a modification

of onlay urethroplasty with paramental foreskin flap devised by Koyanagi and colleagues) [6].

We believed that this technique would be superior to the classic TIP urethroplasty in avoiding postoperative urethral stricture and meatal stenosis. We also believed it to be superior to the Mathieu procedure as our flap is better vascularized and is applicable to more proximal forms of hypospadias.

We used this flap in all 30 cases of hypospadias without chordee included in our study with satisfactory results. We also paid great attention to meticulous dissection and fine surgical technique using fine instruments and optical magnification using a $\times 2.5$ optical loupe. This stands in agreement with most hypospadiologists [12].

All patients were followed up for 3 months to 1 year. Gentle probing of the meatus and urethral calibration using Nelaton catheters 6–8 Fr proved that there was no meatal nor urethral stricture in our series. We had an overall complication rate of 7% which is acceptable and found comparable to the results of those using TIP urethroplasty and Mathieu procedures in cases of hypospadias without chordee [9].

We had two cases of urethrocutaneous fistulae in our series; these occurred in patients with distal penile hypospadias. We were not surprised because we found the harvest of the flap more difficult in distal cases than proximal and mid-penile ones. This is because of the fact that the flap in distal cases is closer to the coronal sulcus at the angle with the urethral plate causing a hindrance to application of the technique and increasing difficulty. However, this becomes evident only with repetition of the procedure.

We find the Mansoura modification of the unilateral Koyanagi technique is not suitable for cases of hypospadias with chordee of even less than 30° . These cases are better managed by the modified Koyanagi one-stage repair of proximal hypospadias which we prefer to the two-stage procedures. Snodgrass would agree with us on only the first half of this statement as he has abandoned the TIP urethroplasty in favor of the two-stage procedures for similar cases [9].

We feel that application of this technique to many more patients is necessary to give a solid evaluation. Hopefully, we can convince more parents to approve our novel technique which is based on traditional principles of plastic surgery.

Conclusion

The Mansoura modification of the unilateral Koyanagi technique is an innovative technique that fulfills many criteria for successful surgical results in cases of hypospadias without chordee. In our limited experience, it is an alternative to TIP urethroplasty avoiding urethral stricture and meatal stenosis. It still stands as a new procedure that needs a lot of time and further studies to be truly evaluated.

Conflicts of interest

There are no conflicts of interest.

References

- 1 Evan J, Kass, David B. Single stage hypospadias reconstruction without fistula. *J Urol* 1994; **144**:250–255.
- 2 Braga LH, Pippi Salle JL, Lorenzo AJ, Skeldon S, Dave S, Farhat WA, *et al*. Copmparative analysis of tubularized incised plate versus onlay island flap urethroplasty for penoscrotal hypospadias. *J Urol* 2007; **178** (Pt 1):1451–1456. Discussion 1456–1457.
- 3 Hadidi AT. Functional urethral obstruction following tubularised incised plate repair of hypospadias. *J Pediatr Surg* 2013; **48**:1778–1783.
- 4 Koyanagi T, Matsuno T, Nonomura K, Sakakibara N. Complete repair of severe penoscrotal hypospadias in one stage: experience with urethral mobilization. Wing flap-flipping urethroplasty and glanulomeatoplasty. *J Urol* 1983; **130**:1150–1154.
- 5 Emir M, Jaynathi VR, Nitahara K, Danismend N, Koff SA. Modification of Koyanagi technique for the single stage repair of proximal hypospadias. *J Urol* 2000; **164**:973–976.
- 6 Koyanagi T, Nonomura K, Asana Y, Gotoh T, Togashi M. Onlay urethroplasty with paramental foreskin flap for distal hypospadias. *Eur Urol* 1991; **19**:221–224.
- 7 Furness PD 3rd, Hutcheson J. Successful hypospadias repair with ventral based vascular dartos pedicle for urethral coverage. *J Urol* 2003; **169**:1825–1827.
- 8 Shukla AR, Patel RP, Canning DA. The 2-stage hypospadias repair. Is it a misnomer. *J Urol* 2004; **172**:1714–1716.
- 9 Snodgrass W, Bush N. Primary hypospadias repair techniques: a review of evidence. *Urol Ann* 2016; **8**:403–408.
- 10 Keating MA, Duckett JW Jr. Chapter 64: operations for distal hypospadias. In: Fowler JE Jr, Nyhus LM, Baker RJ, editors. *Mastery of surgery, urologic surgery*. Boston, MA: Little & Brown and Company; 1992. p. 523.
- 11 Elsaied A, Saied B, El-Ghazaly M. Modified Koyanagi technique in management of proximal hypospadias. *Ann Pediatr Surg* 2010; **6**:22–26.
- 12 Van der Werff JF, Ultee J. Long-term follow up of hypospadias repair. *Br J Plast Surg* 2000; **53**:588–592.