

A new approach on treatment of esophageal atresia: uniportal vats for surgical repair – a report of two cases

Lorena M. Fortes^a, Miriam G. González^b, Noelia C. Mata^b, María R. Ruiz^b and Manuel G. Tellado^b

Esophageal atresia is a rare congenital malformation affecting one in every 3500 live births. Treatment consists in surgical ligation of the fistula and esophageal anastomosis of the two pouches by conventional thoracotomy or by thoracoscopic approach. In recent years, uniportal video-assisted thoracic surgery has been a revolution in thoracic surgery but it had never been used for treatment of congenital pathologies like esophageal atresia. We have used this technique for the treatment of two newborns with this condition. We made a reparation with fistula ligation and end-to-end anastomosis, video-assisted using one only incision. We have excellent results with this technique. A larger list of patients and an increased surgical experience is needed but this can be a new and appropriated alternative in the reparation of esophageal

atresia-tracheoesophageal fistula. *Ann Pediatr Surg* 14:95–97 © 2018 Annals of Pediatric Surgery.

Annals of Pediatric Surgery 2018, 14:95–97

Keywords: children, esophageal atresia, neonates, uniportal video-assisted thoracic surgery

^aDepartament of Pediatric Surgery, Hospital Teresa Herrera, Complejo Hospitalario Universitario de A Coruña and ^bDepartament of Pediatric Surgery, Children's Hospital Teresa Herrera, A Coruña, Spain

Correspondence to Lorena M. Fortes, MPH, Department of Pediatric Surgery, Hospital Teresa Herrera, Complejo Hospitalario Universitario de A Coruña, As Xubias 84. s/n 15004 A Coruña, Spain
Tel: + 34 646 895 278;
e-mails: lorenamiguezfortes@gmail.com, lorena.maria.miguez.fortes@sergas.es

Received 23 March 2017 accepted 25 August 2017

Introduction

Esophageal atresia (EA) is a congenital malformation affecting ~1 in every 3500 live births [1–3]. EA type C, which consists of a proximal esophageal pouch and a distal tracheoesophageal fistula (TEF) accounts for 84% of the cases. Many surgical techniques had been described to correct this anomaly. However, no single technique is universally accepted. [4,5].

Classical operation is done by open thoracotomy but in 1941 thoracoscopic approach was described by Rothenber [6]. Thoracoscopy is now currently accepted and used by an increasing number of pediatric surgeons for a variety of indications, including EA-TEF.

Since 2010 when uniportal video-assisted thoracic surgery (VATS) was introduced for major pulmonary resections this technique has been spreading worldwide especially in adults patients [7] but its use is not widespread in children and until now it had never been described for the repair of this condition.

We propose the use of uniportal VATS for reparation of EA-TEF and we present two cases of type IIC EA-TEF treated in our department with this technique with excellent results.

Operative technique and cases presentation

Operative technique

Patients were placed in left lateral decubitus position. Single-incision VATS was performed by only one incision of 3 cm at level fifth right intercostal space (Fig. 1a and b).

We performed an extrapleural approach. The parietal pleura is swept away from the thoracic wall taking care

not to open it. Next step it is dissection and section of the azygos vein. The distal TEF is freed from surrounding tissue and traction sutures are placed at the tracheal and esophageal segments (Fig. 2). The esophageal fistula is divided and simultaneously closed by fine absorbable sutures. Care is taken to avoid damage to the vagal fibers and blood supply to the distal esophageal segment. We suture the two ends with a tension-free end-to-end one layer interrupted esophageal anastomosis with absorbable suture (Polisorb 4-0). A feeding tube is passed through the anastomosis. Chest drain was used in both cases.

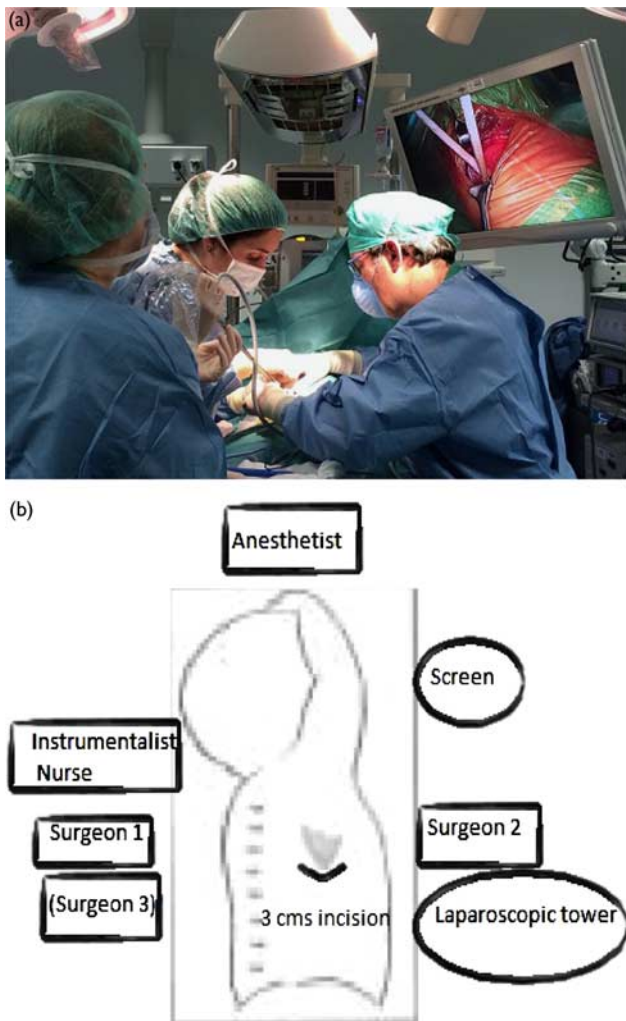
Case 1

A low birth weight male neonate of 1040 g born at 28 weeks was operated by uniportal VATS without incidents. Later the patient precise exploratory laparotomy for retroperitoneal hematoma secondary to extravasation of femoral catheter which it was resolved with conservative measures. Enteral nutrition was started at 26 days of life without incidents. He was discharged at 56 days of life. Patient is at 1-year follow-up with good weight gain, no respiratory problem or any regurgitation and satisfactory cosmetic outcome of scars.

Case 2

A female neonate of 18 h of life full term was transferred to our hospital for suspected EA. The diagnostic was confirmed and the patient underwent surgery on 24 h of life by uniportal VATS. Enteral nutrition was initiated the fourth day of life. She was discharged on the 10 postoperative day with good looking surgical wound without evidence of infection.

Fig. 1



(a) Surgical repair of esophageal atresia by uniportal video-assisted thoracic surgery approach. As we can observe at the picture we benefit from a direct vision of the open minithoracotomy and the amplified image of the camera that we introduce by the same incision. (b) Placement surgical team: head surgeon must be on the right side of the patient. One or two assistant surgeons can help to operate and to take the camera. Patient's position is left lateral decubitus and we perform a 3 cm single incision at five right intercostal space.

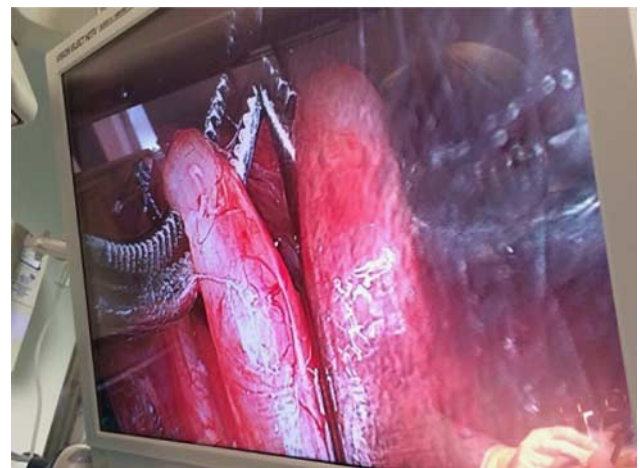Discussion

Success in the repair of EA and TEF has been a main index of quality of a pediatric surgical service [8].

Advances in anesthesia, neonatal intensive, surgical, and cardiac care have improved the overall survival rate in infants with EA since Haight and Towsley [9] reported the first successful primary repair in 1943 by thoracotomy. The early complications after repair of EA are associated with surgical techniques and patient factors [10].

Thoracoscopy is now used by pediatric surgeons for several indications, including EA [11]. This technique use a video thoracoscopic approach and two to four incisions. The thoracoscopic repair of EA/TEF can be safely performed by experienced surgeons. The results are comparable to previous reports of babies undergoing repair through a thoracotomy [11,12].

Fig. 2



Dissection of esophageal segments to identify and repair fistula and to perform end-to-end anastomosis between proximal and distal esophageal pouches. We can observe amplified image of camera.

Actually, both techniques, open and thoracoscopic, are accepted for repair of EA with TEF.

Uniportal thoracic surgery is a technique with limited experience in children. Very few uniportal reports exists in pediatric patients. These include the treatment of thoracic disorders like empyema debridement, lung abscesses, or lung biopsies [13] but there are no reports in literature of its use for the treatment of this congenital malformation.

The uniportal surgery was initially described by Bertolaccini *et al.* [14] first for the management of minor procedures.

González-Rivas *et al.* [15] described uniportal VATS. He reports his first 100 cases of VATS lobectomy in adults with impressive results.

Since its description, uniportal VATS is accepted for a wide variety of procedures worldwide in adults offering a number of advantages over conventional surgery.

One of the most important aspects of this pathology is the anesthetic management. First, these patients are at risk of airway anomalies [16], second position of the fistula it may difficult to intubate and patients with a small fistula can present a ventilation challenge [17,18]. During the surgery, ipsilateral lung is compressed to achieve an adequate working space and deoxygenation can occur. This is one of the great advantages we have observed with this access: we get a better vision of the surgical field because of direct and camera vision so we need less lung compression. Because of this we have observed that anesthetic requirements decrease. Both patients were hemodynamic and ventilatory stable during surgery.

One of the great challenges of pediatric surgeon and especially of this pathology is the dissection and careful handling of tissues and structures in very low weight neonates. In our series, we present a case of a premature male of 1040 g.

Thanks to the video-assisted surgery, the superior and magnified visualization of the thoracic cavity is extremely useful particularly in operating TEF repair where the fistula is seen very clearly with this procedure, with the advantage we do not need adding an incision to the placement of the camera.

In addition we get access to thoracic cavity, using a minimal incision of 3 cm. The smaller incision decrease rib spreading what also may result in less postoperative pain without losing the advantages of open thoracotomy like extrapleural approach.

Operating time was no longer than other reports with open or thoracoscopic surgery [19].

Both patients had good evolution, with a 100% survival without postoperative anastomotic leaks or other complications.

Conclusion

We proposed the use of uniportal VATS for the esophageal anastomosis in EA. This procedure is feasible, safe, and secure procedure in expert hands. Only one incision is used, which is less invasive than open conventional procedure or multi portal technique.

We know that more experience and a greater number of patients is needed to compare the results with conventional techniques, however, we believe that uniportal VATS offers clear advantages without increasing the number of complications so it should be considered in the treatment of this pathology and other thoracic diseases in pediatric age.

Conflicts of interest

There are no conflicts of interest.

References

- 1 Spitz L. Esophageal atresia: lessons I have learned in a 40-year experience. *J Pediatr Surg* 2006; **41**:1635–1640.

- 2 Pedersen RN, Calzolari E, Husby S, Garne E. Oesophageal atresia: prevalence, prenatal diagnosis and associated anomalies in 23 European regions. *Arc Dis Child* 2012; **97**:227–232.
- 3 Sfeir R, Bonnar A, Khen-Dunlop N, Auber F, Gelas T, Michaud L, et al. Esophageal atresia: data from a national cohort. *J Pediatr Surg* 2013; **48**:1664–1669.
- 4 Nakayama DK. Congenital abnormalities of the esophagus. In: O'Neill JA, Grosfeld JL, Fonkalsrud EW, Coran AG, Caldamone AA, editors. *Principles of pediatric surgery*, 2nd ed. St Louis, MO: Mosby; 2003. 385–394.
- 5 Foker JE, Linden BC, Boyle EM Jr, Marquardt C. Development of a true primary repair for the full spectrum of esophageal atresia. *Ann Surg* 1997; **226**:533–543.
- 6 Rothember S. Thoracoscopic repair of a tracheoesophageal fistula in a newborn. *Pediatr Endosurg Innov Techn* 2000; **4**:289–294.
- 7 Fieira Costa E, Roel Delgado M, Paradela de la Morena M, Gonzalez-Rivas D, et al. Technique of uniportal VATS major pulmonary resections. *J Thorac Dis* 2014; **6** (Suppl 6):S660–S664.
- 8 Koivusalo AI, Pakarinen MP, Rintala RJ. Modern outcomes of oesophageal atresia: single centre experience over the last twenty years. *J Pediatr Surg* 2013; **48**:297–303.
- 9 Haight C, Towsley H. Congenital atresia of the esophagus with tracheoesophageal fistula. Extrapleural ligation of fistula and end-to-end anastomosis of esophageal segments. *Surg Gynecol Obs* 1943; **76**:672–688.
- 10 Mortell AE, Azizkhan RG. Esophageal atresia repair with thoracotomy: the Cincinnati contemporary experience. *Semin Pediatr Surg* 2009; **18**:12–19.
- 11 Shah R, Reddy AS, Dhend NP. Video assisted thoracic surgery in children. *J Minim Access Surg* 2007; **3**:161–167.
- 12 Holcomb GW III, Rothenberg SS, Bax KMA, Martinez Ferro M, Albanese CT, Ostlie DJ, et al. Thoracoscopic repair of esophageal atresia and tracheoesophageal fistula: a multi-institutional analysis. *Ann Surg* 2005; **242**:422–430.
- 13 Oak SN, Parelkar SV, SatishKumar KV, Pathak R, BH Ramesh, S Sudhir, M Keshav. Review of video-assisted thoracoscopy in children. *J Minim Access Surg* 2009; **5**:57–62.
- 14 Bertolaccini L, Rocco G, Viti A, Terzi A. Geometrical characteristics of uniportal VATS. *J Thorac Dis* 2013; **5** (Suppl 3):S214–S216.
- 15 González-Rivas D, Paradela M, Fernandez R, Delgado M, Fieira E, Mendez L, et al. Uniportal video-assisted thoracoscopic lobectomy: two years of experience. *Anna Thorac Surg* 2013; **95**:426–432.
- 16 Shanbhag S, Millar C. Anesthetic management of subglottic stenosis complicating tracheo-esophageal fistula in a newborn. *Pediatr Anesth* 2008; **43**:e1–e3.
- 17 Holzki J. Bronchoscopic findings and treatment of tracheo-oesophageal fistula. *Pediatr Anesth* 1992; **2**:297–303.
- 18 Andropoulos DB, Rowe RW, Betts JM. Anaesthetic and surgical airway management during tracheo-oesophageal fistula repair. *Pediatr Anesth* 1998; **8**:313–319.
- 19 Martinez Ferro M, Elmo G, Bignon H. Thoracoscopic repair of esophageal atresia with fistula: inicial experience. *Pediatr Endosurg Innov Techn* 2002; **6**:229–237.