

# Successful intralesional bleomycin injections for the management of a huge life-threatening cervical lymphangioma in a 3-day-old neonate

Saad S. Alqahtani<sup>a</sup>, Ashraf H.M. Ibrahim<sup>b</sup>, Hamad A. Hader<sup>b</sup> and Magdy A. Al Dumairy<sup>c</sup>

**Intralesional bleomycin injections (IBI) for the management of a huge life-threatening cervical cystic hygroma is superior to surgery. Surgery has a high rate of morbidity and even mortality. Recurrence and injury to major vessels, nerves, and lymphatics may be unavoidable. The authors report on a 3-day-old male infant who was diagnosed antenatally as a case of a huge cervical cystic hygroma. Postnatally, the patient required mechanical ventilation. The patient was treated successfully with IBI without complications. To our knowledge, this is the youngest case presenting acutely to be treated successfully with IBI without complications. *Ann Pediatr Surg* 14:92–94 © 2018 Annals of Pediatric Surgery.**

## Case report

A 35 weeks' gestational age boy was found to have a huge neck mass antenatally on ultrasonography (US). Soon after delivery, the patient required mechanical ventilation due to respiratory distress. Clinically, the baby was 2 kg. General examination was unremarkable. Locally, there was a huge cystic swelling mainly on the right side of the neck and extending to the left side (Fig. 1). Laboratory workup was unremarkable. US of the neck at 1 day of age showed bilateral cystic lesions more sizable in the right side. The right and left masses were inseparable from each other. The diagnosis was in favor of a lymphangioma or a cystic hygroma. A computed tomography of the neck with contrast confirmed the above-mentioned findings (Fig. 2a and b). The cystic lesions showed multiple enhancing internal septations and multiple enhancing vascular lesions at the superior aspect. On the third day of life, the lesion in the neck was aspirated and then injected with water-soluble bleomycin solution (0.5 mg/1 ml) under US guidance. The aspirate showed altered blood in areas and serosanguinous fluid from other areas. A total of 2 ml (0.5 mg/1 ml/kg) was injected at different sites into

*Annals of Pediatric Surgery* 2018, 14:92–94

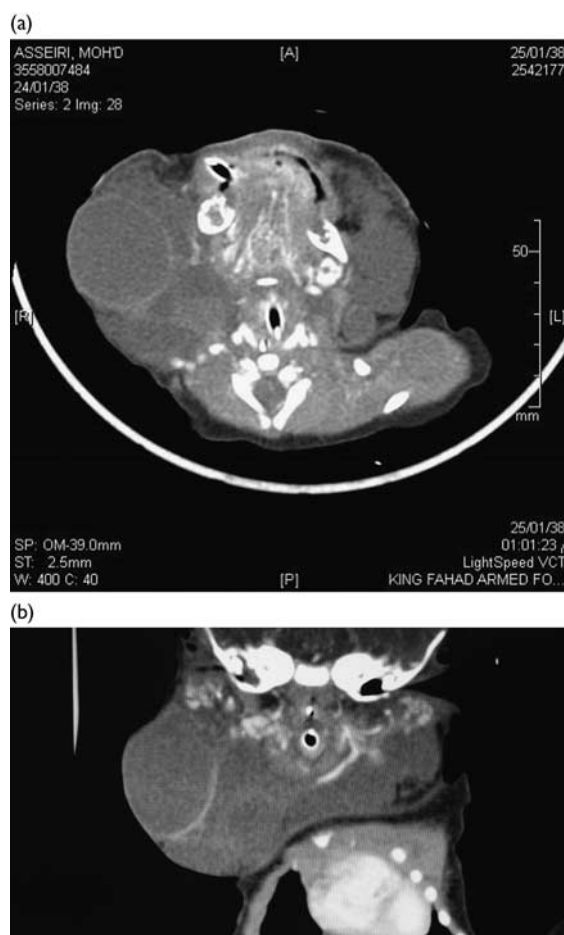
**Keywords:** bleomycin, neonatal cystic hygroma, respiratory distress

<sup>a</sup>Department of Interventional Radiology, <sup>b</sup>Department of Pediatric Surgery and <sup>c</sup>US Unit, Department of Obstetrics/Gynecology, Armed Forces Hospital, Southern Region, Khamis Mushait, Saudi Arabia

Correspondence to Ashraf H.M. Ibrahim, MD, FRCSI, DPS, Department of Pediatric Surgery, Armed Forces Hospital, Southern Region, PO Box 101, Khamis Mushait 61961, Saudi Arabia  
Tel: +966 1725 00001 x22154; e-mail: ash\_ib@hotmail.com

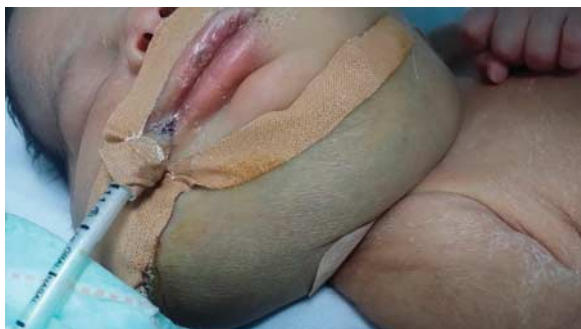Received 7 July 2017 accepted 18 July 2017

**Fig. 2**



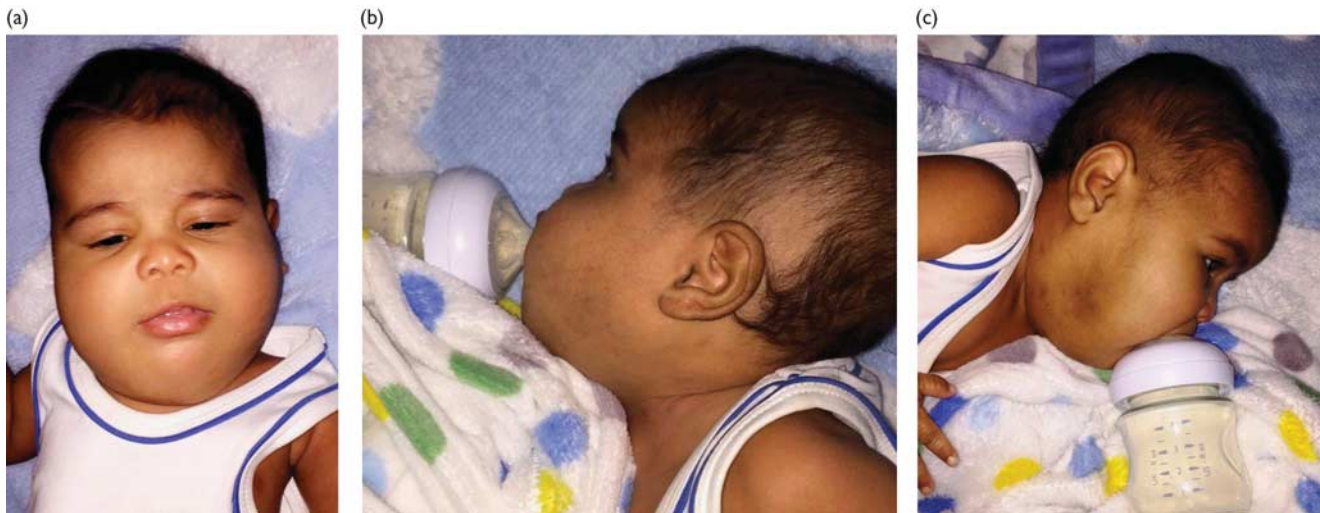(a) Computed tomography with contrast at 1 day of age showing a large multilocular cystic mass more sizable at the right side. The right and left masses are connected together in the midline. There were multiple enhancing internal septations supporting the diagnosis of a lymphangioma. (b) A coronal view.

**Fig. 1**



Initial presentation of the patient soon after delivery.

Fig. 3



The baby at 5 months of age in different positions. Note the discoloration at the right side due to intralesional bleomycin injections, which usually disappears with time. (a) Anterior view, (b) left side view, (c) right side view.

the swelling. This was repeated after 1 week. There was a significant reduction in the swelling after the second intralesional bleomycin injections (IBI) and the patient could be extubated safely. Thereafter, IBI was repeated every 2 weeks under US guidance for up to six injection sessions. The dose was adjusted according to the weight. In the last two sessions the dose of IBI was increased to 1 mg/1 ml/kg. The IBI was tolerated well except for local mild erythema and oropharyngeal disorder requiring nasogastric tube feeding that resolved spontaneously. The swelling markedly decreased in size (Fig. 3a–c). There is no recurrence now for 7 months.

### Discussion

A lymphangioma or a cystic hygroma mainly affects the neck and axilla in 75 and 20% of cases, respectively. The lesion may grow and cause compression, infection, and hemorrhage [1]. It may present with clinical signs of bronchiolitis [2,3]. Surgery is the main tool for therapy except in premature infants and when neurovascular structures are involved [4]. The aim of surgery is to remove the swelling without complications. This might not be possible, especially in a huge cervical or cervicomedial lymphangioma. There is a mortality rate of 2–10% and morbidities that include damage to neurovascular structures, lymphorrhea, chylothorax, recurrence, oropharyngeal disorders that may persist for several months, and bad cosmetic appearance due to heroic and mutilating surgery [4–7]. Ming *et al.* [8] successfully treated a case of bilateral diaphragmatic lymphangioma with IBI after a failed surgical excision.

IBI is as effective as surgery. It causes regression in 88% of cystic hygromas and complete resolution in 44% [9]. It can be used in primary or recurrent cases. However, it is claimed that it cannot be used in a huge cystic hygromas involving the mediastinum, the abdomen, or in life-threatening emergency situations [4,9]. After injection, the lesion may enlarge in size and cause more

compression. This has been challenged by Ibrahim *et al.* [10] by treating a huge life-threatening cervicomedial cystic hygroma using IBI. In such emergency situations the tracheal intubation should continue during IBI until the lesion regresses in size when extubation can be tried with extreme caution.

Side effects of IBI mentioned in the literature include fever, the risk for marked increase in size, local erythema, temporary oropharyngeal disorder, and pulmonary toxicity. Many authors denied pulmonary toxicity if IBI is given locally in proper doses [4,6,11]. The technique of IBI whether soluble solution or fat emulsion is well reported in the literature [4,9,11–13].

Spontaneous resolution is uncommon but has been reported in up to 15% of cases [14]. The authors of the present report do not recommend waiting for spontaneous resolution to occur. This may end up with respiratory distress or acute respiratory failure requiring tracheal intubation. A difficult intubation should be anticipated. Neuromuscular blockers should be avoided [15]. Alternative equipments should be available. This includes light stylet, a bougie, a video laryngoscope, or a laryngeal mask airway. Rigid bronchoscopy, emergency cannula cricothyrotomy with transtracheal jet ventilation, surgical cricothyroidotomy, or tracheostomy may also be required [16,17].

In conclusion, IBI is a safe and effective alternative to surgery. It can be used as a primary therapy in a huge cervical lymphangioma in a newborn even in acute life-threatening emergency.

### Conflicts of interest

There are no conflicts of interest.

### References

- 1 De Lorimier AA. Congenital malformation and neonatal problems of the respiratory tract. In: Welch KJ, Randolph JG, Ravitch MM, *et al*, editors. *Pediatric surgery*. Chicago, IL. 1986. pp. 631–644.

- 2 Balkaran BN, Maharaj P, Pitt-Miller P. Intrathoracic cystic hygroma in an infant with respiratory failure. *West Indian Med J* 1997; **46**:128–129.
- 3 Bosdure E, Mates M, Mely L, Guys JM, Devred P, Dubus JC. Cystic intrathoracic hemolymphangioma: a rare differential diagnosis of acute bronchiolitis in an infant. *Arch Pediatr* 2005; **12**:168–172.
- 4 Okada A, Kubota A, Fukazawa M, Imura K, Kamata S. Injection of bleomycin as a primary therapy of cystic lymphangioma. In: Fukazawa M, Imura K, Kamata S, editors. *J Pediatr Surg* 1992; **27**:440–443.
- 5 Grosfeld JL, Weber TR, Vane DW. One-stage resection for massive cervicodiastinal hygroma. *Surgery* 1982; **92**:693–699.
- 6 Tanaka K, Inomata Y, Utsunomiya H, Uemoto S, Asonuma K, Katayama T, et al. Sclerosing therapy with bleomycin emulsion for lymphangioma in children. *Pediatr Surg Int* 1990; **5**:270–273.
- 7 Cystic hygroma. *Lancet* 1990; **335**:511–512.
- 8 Ming YC, Wong KS, Wang CJ, Lai JY. Successful management of a bilateral diaphragmatic lymphangioma. In: Wong KS, Wang CJ, Lai JY, editors. *Pediatr Surg Int* 2007; **23**:591–593.
- 9 Orford J, Barker A, Thonell S, King P, Murphy J. Bleomycin therapy for cystic hygroma. In: Barker A, Thonell S, King P, Murphy J, editors. *J Pediatr Surg* 1995; **30**:1282–1287.
- 10 Ibrahim AHM, Kandeel A, Bazeed MF, Shaker M, Al Rawaf A. Successful non-surgical management of a huge life threatening cervicodiastinal cystic hygroma. Case report and review of the literature. *J Pediatr Surg Spec* 2009; **3**:48–49.
- 11 Muir T, Kristen M, Fourier P, Dippenaar N, Ionescu GO. IBI treatment for hemangiomas and congenital vascular malformation. *Pediatr Surg Int* 2004; **19**:766–773.
- 12 Yura J. Bleomycin treatment for cystic hygroma in children. *Arch Jap Chir* 1977; **46**:607–614.
- 13 Tanigawa N, Shimomatsuyz T, Takatrashi K, Inomata Y, Tanaka K, Satomura K, et al. Treatment of cystic hygroma and lymphangioma with the use of bleomycin fat emulsion. *Cancer* 1987; **60**:741–749.
- 14 Alqahtani A, Nguyen LT, Flageole H, Shaw K, Laberge JM. 25 years' experience with lymphangiomas in children. *J Pediatr Surg* 1999; **34**:1164–1168.
- 15 Fernandez-Alantud J, Hortelano-Arague A, Aranda-Romero C, Reinoso-Barbero F, Lahoz AI, Rabanal I. Undiagnosed cervical cystic hygromas a cause of airway obstruction and difficult intubation in a child. *Paediatr Anaesth* 2008; **18**:442–446.
- 16 Sharma S, Aminuldin AG, Azlan W. Cystic hygroma: anaesthetic considerations and review. *Singapore Med J* 1994; **35**:529–531.
- 17 Au CC, Chau SK, Chan HY, Tsoi NS. Cystic hygroma in the neck causing airway compromise: case report review of literature. *J Paediatr Respirol Crit Care* 2015; **11**:13–15.