

# Early surgical correction of buried penis

Hesham Kassem, Wael Alshahat and Mohamed Khalifa

**Introduction** Buried penis is a developmental condition characterized by normal size penis that appears smaller or hidden by suprapubic fat. Many complications are associated with buried penis, including poor cosmeses, poor hygiene, difficult accessibility, and recurrent balanitis. Urinary tract infection, negative feeling by parents and patients. Different surgical techniques have been described to correct the condition.

**Aim** The aim of this study was to present our result of early surgical correction of buried penis.

**Results** A total of 94 patients underwent correction of buried penis. 80 (85%) patients were less than 2 years of age. The mean follow-up was 8 months, ranging from 6 to 22 months. The most common types of anomaly were buried penis [65 (59.5%)], concealed penis [21 (22.3%)], and trapped penis [eight (8.5%)]. The early postoperative complications were edema [10 (10.6%)], bleeding [four (4.2%)], excess inner prepuce [three (3.1%)],

redundant skin [two (2.1%)], and infection [one (1.06%)]. The late postoperative complications were partial recurrence in 6.3%. In 63.8% the skin was adequate and there was no need for additional skin flap; in 27.6% we created payers flap and in 8.5% we used the long inner prepuce.

**Conclusion** Early surgical correction of buried penis is safe and is associated with minimal complications. *Ann Pediatr Surg* 14:83–86 © 2018 Annals of Pediatric Surgery.

*Annals of Pediatric Surgery* 2018, 14:83–86

**Keywords:** buried penis, circumcision, trapped penis

Pediatric Surgery Department, Zagazig University, Zagazig, Egypt

Correspondence to Hesham Kassem, MD, Pediatric Surgery Department, Zagazig University, PO Box 44511, Zagazig, Egypt  
Tel: +20 055 236 9063; e-mail: kassemhesham91@yahoo.com

Received 8 May 2017 accepted 8 June 2017

## Introduction

Buried penis is a developmental condition characterized by normal size penis that appears smaller or hidden by suprapubic fat. It was first described by Keyes in 1919 [1–4]. The etiology is not clear, but the most widely accepted hypothesis is abnormal dartos fascia tethering the penis; other causes include lack of penile skin fixation to Buck's fascia [3,4] and ventral skin deficiency [5,6], excessive prepubic fat [7,8], and abnormal ventral displacement of the penis [9]. It can also occur as a complication of circumcision due to formation of cicatrized scar over the glans [3,10]. Many complications are associated with buried penis, including poor cosmeses, poor hygiene, difficult accessibility, and recurrent balanitis. Urinary tract infection, negative feeling by parents and patients [10,11]. Different surgical techniques have been described to correct the condition [3]. In the present study we assess our results of early surgical correction of buried penis.

## Aim

The aim of this study was to present our result of early surgical correction of buried penis.

## Patients and methods

### Clinical data

A retrospective review was performed for 94 patients who underwent correction of buried penis between November 2012 and January 2015. The indication for surgery includes inability to visualize the penis, difficulty with proper hygiene, preputial adhesion, and parents' concern for future fertility. All patients underwent complete local examination to exclude any associated anomalies such as hypospadias, severe chordee, and severe torsion. Preoperative investigation was carried out in the form of

complete blood count and prothrombin time, partial thromboplastin time, and international normalized ratio. Informed consent was taken from the parents.

### Surgical procedures and follow-up

The patient was placed in the supine position; anesthesia combined with caudal block was induced through inhalation, and prophylactic antibiotic was given. A stay suture was applied in the glans penis for traction. A circumferential incision was made 0.5 cm proximal to the coronal sulcus. The penis was completely degloved to the penopubic junction, and the dissection was performed between Buck's fascia and dartos muscle. Ventrally the dissection was carried out to the penoscrotal junction and dorsally the dissection was completed to the base of the penis; care was taken to avoid injury to the neurovascular bundle. Excision of the redundant mucosa was carried out, and fixation of the dermis of the skin to Buck's fascia was carried out at 3, 9, and 12 O'clock positions using 6/0 PDS suture at the base of the penis. The inner and outer preputial skin was approximated with 6/0 monocrile. Compression dressing was applied.

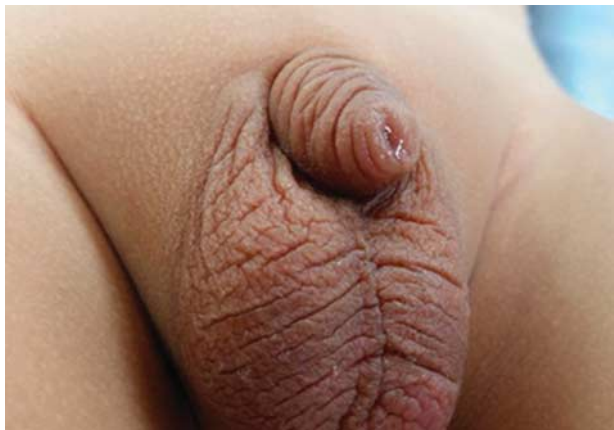All patients were discharged on the same day after full recovery and tolerating feeding and no bleeding from the dressing. All patients were scheduled for regular postoperative follow-up in the clinic after 1 week, 6 months, and 12 months (Figs 1–5).

The study has been approved by IRB committee in international medical center Jeddah and Zagazig university hospital Egypt.

## Results

A total of 94 patients underwent correction of buried penis. Eighty (85%) patients were less than 2 years of age.

Fig. 1



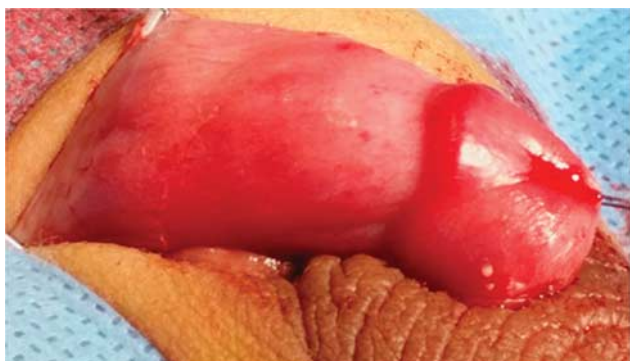
Buried penis noncircumcised.

Fig. 2



buried penis circumcised

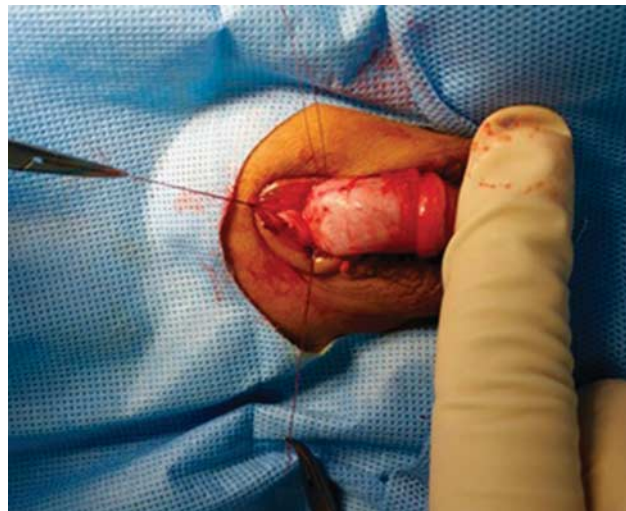Fig. 3



Long inner prepuce.

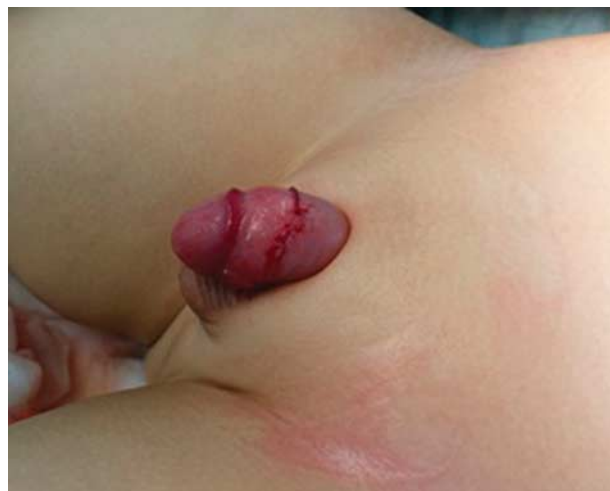The mean follow-up was 8 months, ranging from 6 to 22 months (Table 1). The types of buried penis are shown in Table 2. The indication for surgery is shown in Table 3.

Fig. 4



Fixation of Buck's fascia to the skin.

Fig. 5



Postoperative.

Table 1 Demographic data

Mean age (months)	8 ± 3.2
Mean operative time (min)	34 ± 14.7
Mean follow-up (8 months)	10 ± 3.8

Table 2 Types of anomalies

Buried [n (%)]	65 (59.5)
Concealed [n (%)]	21 (22.3)
Trapped [n (%)]	8 (8.5)

The early and late postoperative complications are shown in Tables 4 and 5. As regards the adequacy of preputial skin, in 60 cases the skin was sufficient to cover the penile shaft and there was no need for additional skin or mucosal flap. Moreover, we did not perform suprapubic

**Table 3 Patients complain**

Routine circumcision [n (%)]	40 (42.5)
Redo circumcision [n (%)]	27 (28.7)
Inability to visualize the penis [n (%)]	10 (10.6)
Poor hygiene [n (%)]	8 (8.5)
Recurrent balanitis [n (%)]	6 (6.3)
Family concern for fertility [n (%)]	4 (4.2)

**Table 4 Early postoperative complications**

Edema [n (%)]	10 (10.6)
Redundant skin [n (%)]	2 (2.1)
Redundant mucosa [n (%)]	3 (3.1)
Wound infection [n (%)]	1 (1.06)
Bleeding [n (%)]	4 (4.2)

**Table 5 Late postoperative complications**

Complete recurrence (n)	0
Partial recurrence [n (%)]	6 (6.3)

lipectomy or liposuction to any of the patients; in 26 patients we used payers flap and in eight patients we used the redundant inner mucosa to cover the ventral skin defect. The surgical repair was successful to improve the penile appearance as well as improving the hygiene. There was no recurrence to the pretreatment penile condition. The edema was transient and subsided within 1 week, Bleeding was mild and was controlled with compression.

Infection was mild and controlled by continuing the oral and local antibiotic for 7 days.

## Discussion

Many classification systems have been proposed for buried penis. Maizels *et al.* [2] described a classification consisting of four categories based on the mechanism of concealment: buried penis (due to poor skin suspension in a child or a prominent prepubic fat in an adolescent), webbed penis (penoscrotal web), trapped penis (the shaft of the penis is trapped in scar skin usually after circumcision), and micropenis (a normally formed penis that is less than two SDs below mean in stretched length). Jung *et al.* [12] classified hidden penis as concealed, buried, webbed, and entrapped penis. They suggested that concealed penis is due to deficiency of the outer penile skin or inelasticity of the dartos fascia and that buried penis is due to poor penile skin fixation at the penile base or excessive suprapubic fat, a webbed penis is characterized by a ventral fold of the skin that joins the distal shaft and scrotum obscuring the penoscrotal angle, and an entrapped penis is covered by scar tissue that occurred secondary to circumcision.

In our study according to this classification we had 45 buried penis, 30 concealed penis, and 19 trapped penis, which was diagnosed by proper clinical examination; patients with micropenis and webbed penis were excluded from the study. The indication for surgical repair of buried penis includes improper hygiene,

repeated urinary tract infection, or family concern regarding future fertility [6,10,11]. In the present study most of the cases came for routine neonatal circumcision and were diagnosed with buried penis or concealed penis and advised to undergo the circumcision and correction of buried penis at 6 months; the other indications for correction were mainly due to preputial adhesion in 15 patients, followed by cosmetic appearance of the penis in 12 patients and improper hygiene in seven patients.

Our study showed that circumcision has been performed in up to 68% of the patients without preoperative diagnosis of the condition.

There is still controversy on the timing of surgery in cases of buried penis. Eroglu *et al.* [13] described that patients with buried penis should not undergo surgery until they have completed puberty, as this is a developmental condition and will improve with growth and puberty. However, Ferro *et al.* [14] and Philip and Nicholas [15] advised early correction of buried penis to avoid negative psychological impact and to resolve both the dysuria and the cosmetic abnormality. We agree with Ferro *et al.* [14] and Philip and Nicholas [15] in that correction of buried penis should be performed early once diagnosed, not only because of the psychological impact it can cause and the difficulty in maintaining hygiene but also because the surgical repair is much easier and is associated with less morbidity.

The principals of surgical correction of buried penis involve complete degloving of the penis, release of abnormal dartos band [3,10,11,13,16], and application of fixation suture between Buck's fascia and skin [3,10].

Cromie *et al.* [3] used a circumferential incision 1 cm away from the corona and released all dysgenetic abnormal Dartos fascia. They then sutured the penile skin to Bucks' fascia at 2 and 10 O'clock positions laterally to avoid injury to the neurovascular bundle. They treated 74 patients with this technique, with excellent results. None of their cases required additional procedure. Frenkl *et al.* [17] used a similar technique with fixation at 3 and 9 O'clock positions; they treated 79 patients. The overall recurrence rate was 16.5 and 3.5% and required repeated repair. Chu *et al.* [19] and Alexander *et al.* [18] did not recommend fixation of the penile skin to Buck's fascia and relied on the natural healing process for fixation of the skin to Buck's fascia.

In our study we used a technique similar to that described by Frenkl *et al.* [17], but we performed fixation at three points, 3, 9, and 12 O'clock positions, to maintain the penopubic angle with excellent results. We found abnormal Dartos bands in all cases. Redman *et al.* [6], however, did not observe any abnormalities of the dartos fascia or any tethering bands in their personal series of 31 boys. We agree with Hadidi [20] in that abnormal long inner prepuce is a constant finding in all cases of buried penis. Maizels *et al.* [2] and Frenkl *et al.* [17] advise liposuction, especially in obese children, but Brisson *et al.* [10] and Perger *et al.* [11] did not recommend liposuction or lipectomy. In our study we did not perform lipectomy or liposuction in any of our cases.

In case of insufficient skin coverage many surgical techniques have been used, such as ventral V plasty [18], Z plasty [5], unfurling of the prepuce [3,4], free skin graft [21], scrotal flap [22,23], or island pedicle flap. In our study we performed unfurling of the prepuce in four cases and pyars flap in 20 cases. In our study most of the cases (74.4%) could be corrected without the need for skin graft or flap.

The long-term outcome of surgical correction of buried penis is excellent in improving the penile appearance and hygiene [24]. Most of the complications are temporary and usually resolve with conservative measures. These include penile edema, hematoma, and superficial infection [3,25]. In our study most of the early complications were penile edema, mild bleeding, and superficial infection that responds well to the conservative measures.

In our study the mean follow-up was 1 year, with excellent results, better appearance, and good accessibility in most of the cases.

## Conclusion

Early surgical correction of buried penis is safe and associated with minimal complications. Although there are numerous operative procedures that have been described for the management of buried penis, we found that simple degloving of the penis and fixation of the penile skin to Bucks' fascia at the base of the penis at 3, 9, and 12 O'clock positions can correct the condition and achieve good cosmetic and is associated with fewer complications.

## Conflicts of interest

There are no conflicts of interest.

## References

- 1 Chuang JH, Chen LY, Shieh CS, Lee SY. Surgical correction of buried penis: a review of 60 cases. *J Pediatr Surg* 2001; **36**:426–429.
- 2 Maizels M, Zaontz M, Donovan J, Bushnick PN, Firlit CF. Surgical correction of the buried penis: description of a classification system and a technique to correct the disorder. *J Urol* 1986; **136** (Pt 2):268–271.
- 3 Cromie WJ, Ritchey ML, Smith RC, Zagaja GP. Anatomical alignment for the correction of buried penis. *J Urol* 1998; **160**:1482–1484.
- 4 Ruiz E, Vagni R, Apostolo C, Moldes J, Rodriguez H, Ormaechea M, et al. Simplified surgical approach to congenital megaprepuce: fixing, unfurling and tailoring revisited. *J Urol* 2011; **185** (Suppl):2487–2490.
- 5 Donahoe PK, Keating MA. Preputial unfurling to correct the buried penis. *J Pediatr Surg* 1986; **21**:1055–1057.
- 6 Redman JF. Buried penis: congenital syndrome of a short penile shaft and a paucity of penile shaft skin. *J Urol* 2005; **173**:1714–1717.
- 7 Casale AJ, Beck SD, Cain MP, Adams MC, Rink RC. Concealed penis in childhood: a spectrum of etiology and treatment. *J Urol* 1999; **162** (Pt 2):1165–1168.
- 8 Shenoy MU, Srinivasan J, Sully L, Rance CH. Buried penis: surgical correction using liposuction and realignment of skin. *BJU Int* 2000; **86**:527–530.
- 9 Joseph VT. A new approach to the surgical correction of buried penis. *J Pediatr Surg* 1995; **30**:727–729.
- 10 Brisson P, Patel H, Chan M, Feins N. Penoplasty for buried penis in children: report of 50 cases. *J Pediatr Surg* 2001; **36**:421–425.
- 11 Perger L, Hanley RS, Feins NR. Penoplasty for buried penis in infants and children: report of 100 cases. *Pediatr Surg Int* 2009; **25**:175–180.
- 12 Jung EH, Son JH, Jang SH, Lee JW. Simple anchoring of the penopubic skin to the prepubic deep fascia in surgical correction of buried penis. *Korean J Urol* 2011; **52**:787–791.
- 13 Eroglu E, Bastian OW, Ozkan HC, Yorukalp OE, Goksel AK. Buried penis after newborn circumcision. *J Urol* 2009; **181**:1841–1843.
- 14 Ferro F, Spagnoli A, Spyridakis I, Atzori P, Martini L, Borsellino A. Surgical approach to the congenital megaprepuce. *J Plast Reconstr Aesthet Surg* 2006; **59**:1453–1457.
- 15 Phillip I, Nicholas JL. Congenital giant prepucial sac: case reports. *J Pediatr Surg* 1999; **34**:507–508.
- 16 Chuang JH. Penoplasty for buried penis. *J Pediatr Surg* 1995; **30**:1256–1257.
- 17 Frenkl TL, Agarwal S, Caldamone AA. Results of a simplified technique for buried penis repair. *J Urol* 2004; **171** (Pt 1):826–828.
- 18 Alexander A, Lorenzo AJ, Salle JL, Rode H. The ventral V-plasty: a simple procedure for the reconstruction of a congenital megaprepuce. *J Pediatr Surg* 2010; **45**:1741–1747.
- 19 Chu CC, Chen YH, Diau GY, Loh IW, Chen KC. Preputial flaps to correct buried penis. *Pediatr Surg Int* 2007; **23**:1119–1121.
- 20 Hadidi AT. Buried penis: classification surgical approach. *J Pediatr Surg* 2014; **49**:374–379.
- 21 Gillett MD, Rathbun SR, Husmann DA, Clay RP, Kramer SA. Split-thickness skin graft for the management of concealed penis. *J Urol* 2005; **173**:579–582.
- 22 Alter GJ, Ehrlich RM. A new technique for correction of the hidden penis in children and adults. *J Urol* 1999; **161**:455–459.
- 23 Radhakrishnan J, Razzaq A, Manickam K. Concealed penis. *Pediatr Surg Int* 2002; **18**:668–672.
- 24 Mitsukawa N, Kubota Y, Akita S, Saiga A, Satoh K. Postsurgical fixation of a buried penis. *J Plast Reconstr Aesthet Surg* 2015; **68**:439–441.
- 25 Herndon CD, Casale AJ, Cain MP, Rink RC. Long-term outcome of the surgical treatment of concealed penis. *J Urol* 2003; **170** (Pt 2):1695–1697. [Discussion 7].