

Evaluation of laparoscopic-assisted anorectoplasty for the management of intermediate and high anorectal malformations in boys: Mansoura experience

Sherif A. Abdelmaksoud^a, Adham W. El-Saied^a, Nabil M. Dessouky^b and Kamal A. Aly^a

Introduction Laparoscopic-assisted anorectoplasty (LAARP) has been gaining great popularity for management of imperforate anus. This study aims to evaluate the use of this technique for high and intermediate anorectal malformations in boys.

Patients and methods From December 2012 to December 2016, we performed LAARP on 20 boys, all of which were colostomized at birth. Findings regarding the patients' age at operation, type of anomaly, associated morbidities, sacral ratios, operative time, intraoperative complications, hospital stay, immediate/long-term postoperative complications, and reoperations were noted. Postoperatively, we evaluated the patients using barium enema, an ascending and voiding cystourethrogram, pelvic MRI, and a functional continence evaluation questionnaire.

Results A total of 11 patients presented with rectourethral bulbar fistula (RBF), seven with rectourethral prostatic fistula (RPF), one with rectovesical fistula, and one with no fistula. Mean sacral ratio was 0.82 ± 0.19 . Mean age at time of LAARP was 236 ± 77 days. Mean operative time was 152 ± 32 min. Our most common intraoperative complication was peritoneal contamination (20%). Incidence of rectal mucosal prolapse was 40%.

Introduction

The management of anorectal malformations (ARMs) remains a challenge till this day. Laparoscopic-assisted anorectoplasty (LAARP) was first introduced by Georgeson *et al.* [1] in the year 2000 to manage patients with ARMs as an alternative to the posterior sagittal anorectoplasty (PSARP) introduced by deVries and Pena [2]. The greatest advantage of this technique is that the sphincter mechanism is left intact. It is the division of the muscles that leads to fibrosis and a decrease in rectal compliance postoperatively. In theory, it would also cause weakness of the levator and external muscle complex [1,3–6].

This report details our institution's experience with LAARP over a 4-year period for the management of male patients with intermediate and high ARMs in addition to clinical and radiological outcomes observed with this technique.

Patients and methods

From December 2012 to December 2016, 20 boys with intermediate and high ARMs were operated on using LAARP at the Pediatric Surgery Department of the Mansoura University Children's Hospital, Mansoura, Egypt.

Barium enema revealed a mean rectoanal angle of $107 \pm 13^\circ$. Ascending and voiding cystourethrogram revealed a residual urethral diverticulum in seven cases, six of which had RBFs. Mean MRI placement score obtained was 0.76 ± 0.51 denoting excellent rectal position.

Conclusion Usage of LAARP to manage high and intermediate anorectal malformations in boys is feasible, allowing accurate rectal placement within the muscle complex and with good postoperative functional results. Residual urethral diverticulum occurred more frequently in patients with RBF. Incidence of mucosal prolapse is high after LAARP and should be avoided. *Ann Pediatr Surg* 14:72–77 © 2018 Annals of Pediatric Surgery.

Annals of Pediatric Surgery 2018, 14:72–77

Keywords: laparoscopic-assisted anorectoplasty, anorectal malformations, residual urethral diverticulum post LAARP

^aDepartment of Pediatric Surgery, Mansoura University Children's Hospital, Mansoura University and ^bDepartment of Pediatric Surgery, Abu El-Reesh Children's Hospital, Cairo University, Cairo, Egypt

Correspondence to Sherif A. Abdelmaksoud, MD, PhD, 206 El-Gomhorria Street (Nile View Tower), 6th Floor, Mansoura 35500, Egypt
Tel: +20 502 311 414; e-mail: sherifmohd@hotmail.com

Received 23 March 2017 accepted 28 August 2017

All our patients were diagnosed with an intermediate or high anomaly both clinically (by inspection of the perineal development) and radiologically (using a crossed table lateral film). They also had a plain pelvic radiography done (to assess the sacral development and calculate the sacral ratio) and an abdominal ultrasonography (to exclude renal anomalies). All of our patients received a descending divided loop colostomy with a skin bridge in the neonatal period within 2 or 3 days after birth [7].

The type of anomaly in each patient was determined using a high-pressure distal colostogram to demonstrate the presence or absence of a rectourethral fistula and site of fistula if it was found. Our patients were classified according to the Krickbeck classification [8]. We only included male babies with rectourinary or rectovesical fistulas or patients who had an ARM without a fistula where the skin to bowel distance on the crossed table lateral film was greater than 2 cm. Babies with severe associated comorbidities were excluded from our study.

Our findings regarding the patients' age at operation, type of anomaly, associated morbidities, sacral ratios, operative time, intraoperative complications, hospital stay, immediate

postoperative complications, long-term postoperative complications, and reoperations were noted.

Operation

All patients received a LAARP as described by Georgeson [5]. However, some modifications were done. The muscle complex was initially mapped out using a transcutaneous electrical nerve and muscle stimulator set to 100 mA and marked with stitches. We only used three ports in all our patients: an umbilical 5-mm port for the camera, a right upper quadrant 10-mm working port with a 5-mm reducer, and a left upper quadrant 5-mm port for grasping and handling of the rectum. A 2–0 poly-prolene U-shaped bladder stitch was placed to elevate the urinary bladder away from the rectum (Fig. 1). The rectum was dissected using a 5-mm hook electrocautery or harmonic scalpel down to the site of the fistula. We then used a 10-mm clip applier to occlude the fistula using one or two titanium clips (KARL STORZ – ENDOSKOPE, Germany) then proceeded to divide it as low down as possible with scissors. We then went on to the perineal stage and performed an incision of 1–1.5 cm at the site of the previously mapped muscle complex. Blunt dissection was done with a hemostat under laparoscopic surveillance to create the pull-through canal. This was then dilated with Hegar dilators till it was wide enough to admit a 10-mm port. The rectum was then grasped and pulled down to the perineum, and any redundant tissue was excised. A single-layer rectocutaneous anastomosis was done with 4–0 polyglactin 910 sutures (Fig. 2). We did not fix the rectum to the presacral fascia with stitches as described originally by Georgeson [5].

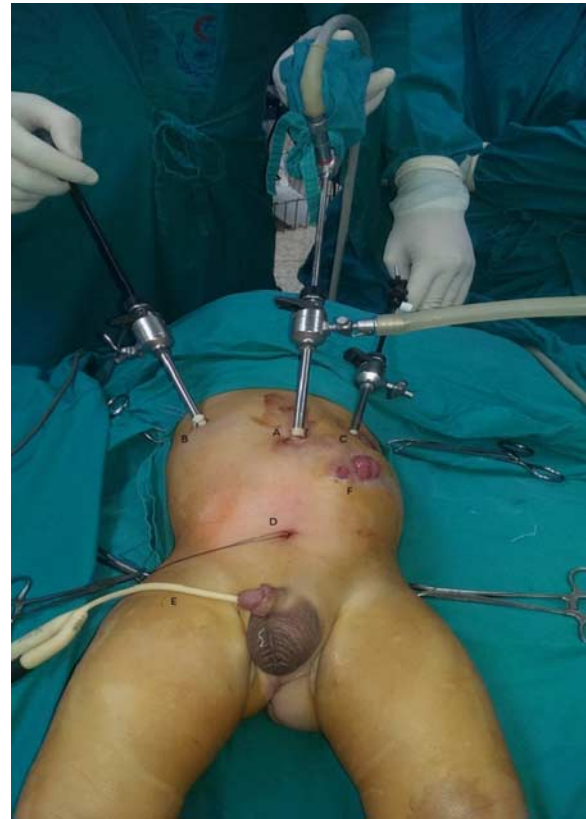Postoperative assessment

During follow-up, none of our patients were subjected to a routine anal dilatation program as recommended by Keily and Pena [9]. We only calibrated the anal opening to ensure that there was no stenosis during the follow-up visits to our outpatient clinic. All our patients received a barium enema to assess the rectoanal angle (RAA), an ascending and voiding cystourethrogram (ACUG and VCUG) to exclude presence of a residual urethral diverticulum (RUD), and an MRI to assess rectal placement within the levator ani and external sphincter muscle complex. Functional outcome was determined in patients older than 3 years only using a functional continence evaluation questionnaire [6].

All our living patients (except those requiring a redo-PSARP) received a barium enema in the postoperative period after closure of their colostomies. The RAA was determined by measuring the angle between a line drawn through the central portion of the anal canal and a line drawn parallel to the posterior wall of the rectum. Barium studies were performed on the patient during rest in the lateral decubitus position [10].

The ACUG and VCUG were done to exclude the presence of a posterior urethral diverticulum or a recurrent rectourethral fistula. The catheter was introduced into the bladder, and a dye was injected filling it, then the catheter was gradually withdrawn while

Fig. 1



Port placement during surgery. (a) Umbilical 5-mm port for the telescope. (b) 5 or 10-mm working port with reducer. (c) 5-mm working port. (d) Transcutaneous 2/0 prolene bladder hitch stitch. (e) Self-retaining 8-Fr urinary catheter. (f) Pena colostomy.

injecting the dye to demonstrate whether a fistula or diverticulum was present. The presence of vesicoureteric reflux was also noted [11].

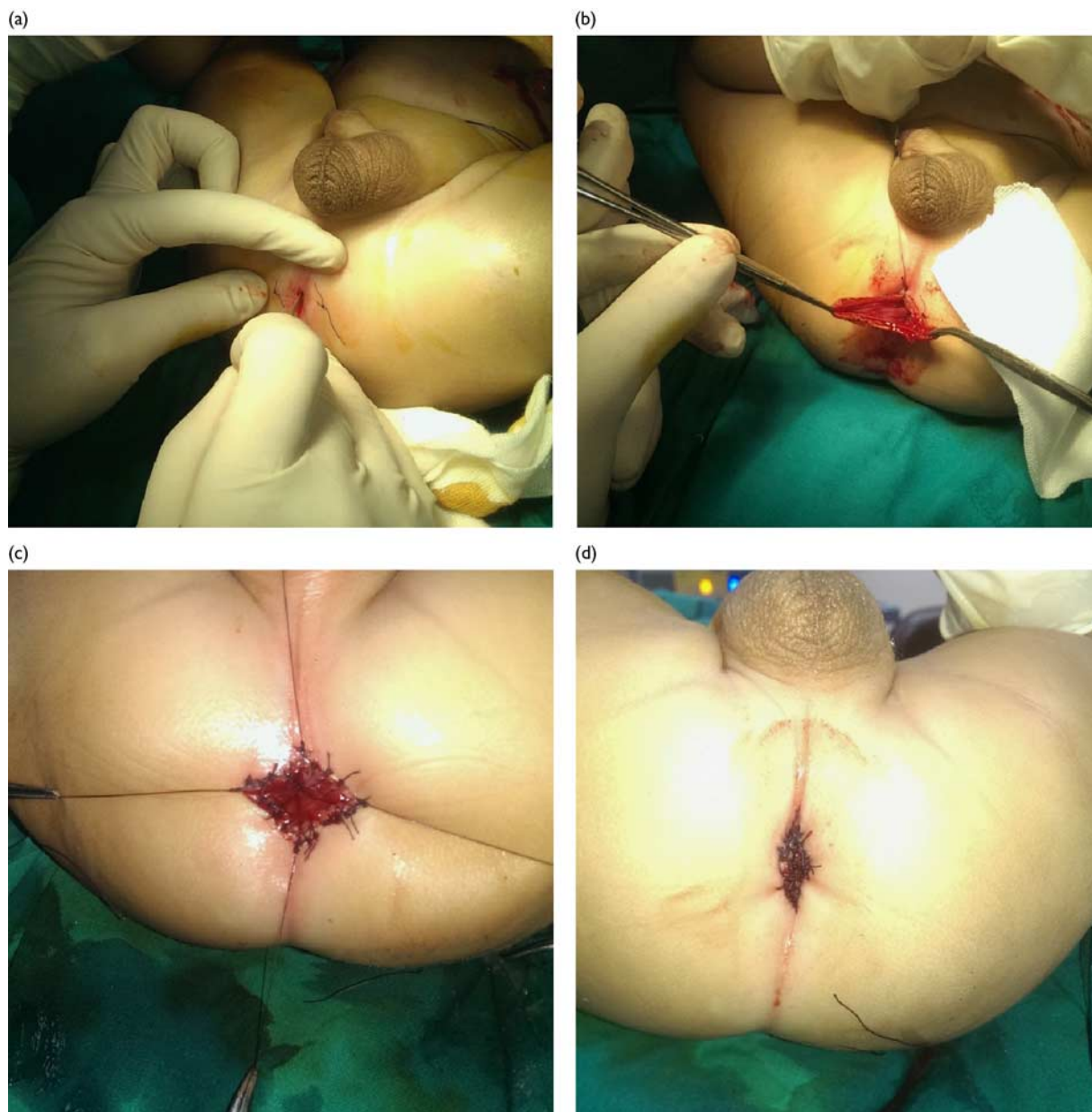
A pelvic MRI was performed on all our living patients (except those requiring a redo-PSARP) to assess the rectal placement within the levator ani and external sphincter muscle complex. Cuts were evaluated at the level of the puborectalis and external sphincter at 3 and 9 o'clock positions for the symmetry of the muscle thickness around the rectum. A score of 0 was given if the muscle around the rectum was symmetrical (Fig. 3), slight asymmetry was given a score of 1, and marked asymmetry was given a score of 2. The worst score was 4, 2 for each muscle level [6,12]. All of these radiological investigations were performed during the postoperative period 2–3 months after closure of the colostomy.

Functional outcome was evaluated using a score proposed by Ichijo *et al.* [6] (Table 1). Only patients who were older than 3 years were included. Patients who had tethered cord, had gross sacral agenesis, or had a redo-PSARP were excluded.

Results

Twenty boys were enrolled in our case series. We had a mean sacral ratio of 0.82 ± 0.19 . Our study included 11 patients with rectourethral bulbar fistula (RBF), seven with rectourethral prostatic fistula (RPF) one with

Fig. 2



Rectal pull-through and fixation to the skin. (a) 1.2-cm vertical incision is made over the previously mapped sphincter complex (central point is marked by stitches). (b) Pull through of the rectum after creation and dilatation of the pull-through canal. (c) Fixation of the rectum to the skin with a single row of interrupted absorbable sutures after resection of excess rectal tissue. (d) The final appearance after completion of the rectocutaneous anastomosis.

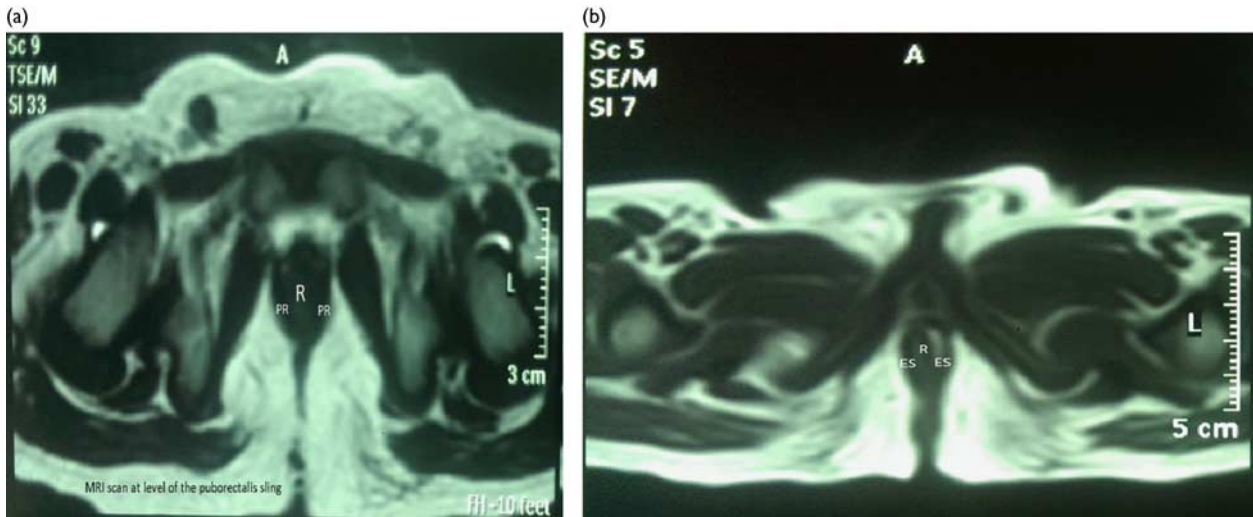
rectovesical fistula, and 1 with no fistula. Thirteen of our patients showed associated anomalies with two patients showing VACTREL association. The various associated anomalies are shown in Table 2.

The mean age at time of surgery was 236 ± 77 days. Our mean operative time was 152 ± 32 min. Fistula closure in all our patients was done using titanium clips, except in one baby who did not have a rectourethral fistula. Regarding intraoperative complications, four patients had a breach of the rectal wall with peritoneal contamination which was managed by suction irrigation and placement of a pelvic drain and postoperative parenteral antibiotics. One patient experienced a diathermy injury to the left ureter which required a resection anastomosis owing to

development of ureteric stricture. One patient had a thermal injury to his bowel from using a harmonic scalpel requiring inversion with interrupted seromuscular sutures extracorporeally. One patient experienced significant bleeding requiring a blood transfusion. No conversion to open surgery occurred.

Median hospital stay was 5 days (range: 3–18 days). All our patients were started on oral feeding with 24 h, except the one patient with thermal injury to his bowel where feeding was delayed for 3 days. A self-retaining urinary catheter was placed in all patients for 5 days postoperatively. Two patients experienced a neurogenic bladder which was discovered after catheter removal. The catheter was replaced in both patients, and they were discharged home.

Fig. 3



Pelvic MRI scan at the level of the puborectalis (a) and the external sphincter (b) showing symmetrical rectal placement (total score = 0). R, rectum; ES, external sphincter; PR, puborectalis.

Table 1 Fecal continence evaluation questionnaire [6]

Parameters	Score
Frequency of defecation (/day)	
1–2	2
3–5	1
6	0
Staining or soiling	
Nil	2
No staining > staining	1.5
Staining > no staining	1
Staining every motion	0.5
Soiling	0
Perineal erosion	
Nil	2
Occasionally	1
Often	0
Anal shape	
Normal looking	2
Scar or visible skin tag	1.5
Visible mucosa	1
Rectal prolapse	0
Medications	
Nil	2
Laxatives/enemas/suppositories	1
Antidiarrheals needed	0
Maximum score	10

Table 2 Total incidence of each type of congenital anomaly in our study

Type of associated anomaly	n (%)
Renal	5 (25)
Absent kidney	1 (5)
Renal atrophy	1 (5)
Bilateral hydronephrosis	1 (5)
Crossed fused ectopia	2 (10)
Genital	5 (25)
Hypospadias	3 (15)
Urethral duplication	1 (5)
Undescended testis	1 (5)
Cardiac	
PDA	1 (5)
Gastrointestinal	2 (10)
Esophageal atresia (pure)	1 (5)
Esophageal atresia with TEF	1 (5)
Limb	1 (5)
Vertebral (hemivertebrae)	2 (10)

PDA, patent ductus arteriosus; TEF, tracheo-esophageal fistula.

The catheter was removed 4 weeks later, and both boys voided normally. One patient developed severe port site infection and complete disruption of his rectocutaneous anastomosis. This patient had chronic kidney disease owing to obstructive uropathy from a neuropathic bladder. He had a vesicostomy created before his LAARP elsewhere. We concluded that infection spread from his bladder owing to the presence of Urinary tract infection causing this complication. This was documented with a urine analysis. This was compounded by his immune-compromised state secondary to his chronic kidney disease. He was managed with regular dressing, debridement and aggressive intravenous antibiotics till the infection cleared. He was discharged on the 18th postoperative day. None of our patients experienced postoperative peritonitis, evisceration at any port site, or ischemia of the pulled-through colon.

One of our enrolled patients died during follow-up (1 year after the procedure) owing to pneumonia and sepsis. None of our patients received regular anal dilatations postoperatively; only calibration was done during their visit to the outpatient clinic. Eight patients experienced variable degrees of mucosal prolapse (40%) that developed within 2 months of the initial LAARP. Seven of these were minor prolapses. All eight patients were readmitted 6–8 weeks later for mucosectomies. None of our patients experienced anal stenosis. The one patient who had an infection at the site of the rectocutaneous anastomosis experienced a complete disruption with retraction of the rectum that required a redo-PSARP. One had partial rectocutaneous anastomotic disruption and was readmitted for a redoanoplasty. One patient was judged to have a misplaced rectum and was also managed with a redo-PSARP. Patients who had redoanoplasties or redo-PSARPs were started on regular anal dilatations 2 weeks postoperatively for 5 months according to the schedule recommended by Keily and Pena [9]. This was done by the parents at home.

The mean obtained fecal continence evaluation questionnaire score obtained for 11 eligible patients was 7.09 ± 1.12 . Overall, 17/19 patients received a barium enema, revealing a RAA of $107 \pm 13^\circ$. All 19 available patients received an ACUG and VCUG. Moreover, 7/19 (37%) patients showed a posterior urethral diverticulum; six of these patients had RBF, representing 87% of all patients with RUD. Mean MRI scores obtained were 0.76 ± 0.51 .

Discussion

The 1980s is considered to be the starting of the golden era for surgical management of ARMs as it witnessed the birth of the PSARP [2]. However, the rate of postoperative motility disorders in the form of constipation and associated megarectum started to climb. Georgeson *et al.* [1] proposed LAARP as an alternative in the year 2000.

Using LAARP to manage rectovesical or high rectoprostatic fistulas is logical. However, implementing it to treat ARMs with RBFs or in absence of a fistula remains controversial. Koga *et al.* [12] performed a comparison between LAARP and PSARP in RBFs only and concluded that LAARP provided comparable results to PSARP in such babies with lower risk of wound infection but a higher risk for rectal mucosal prolapse. We wanted to investigate this further and decided to include patients with RBF in our study.

A major point of criticism in our study is that we did not perform regular anal dilatation after the initial LAARP. We only calibrated the anal opening with Hegar dilators during follow-up visits to our outpatient clinic. An anal dilatation regimen was reserved for patients who required a redoanoplasty only. This was because our first case experienced rectal prolapse requiring a mucosectomy developed anal stenosis during follow-up. He responded well to anal dilatation which was performed at home. We decided to employ a dilatation program there on for other patients who would require a redoanoplasty. This is not the standard practice reported by many authors who advocate anal dilatation postoperatively to avoid anal stenosis [2–4,11]. None of our patients who had LAARP only without a redo-operation experienced anal stenosis in spite the absence of regular anal dilatation.

The most recurring postoperative complication we observed was rectal mucosal prolapse. Overall, 40% of the patients in our study experienced this. This is one of the most frequently recurring complications following LAARP. A prolapse rate of up to 52% has been reported in publications [13]. In our study, this could be explained by the fact that we did not place anchoring sutures to fix the rectum to the presacral fascia as recommended by Georgeson [5]. However, this is a matter for debate. Jung *et al.* [13] and Ruggeri *et al.* [14] placed more emphasis on decreasing the length of the rectal dissection to reduce the risk of postoperative prolapse whereas authors such as Leung *et al.* [15] stressed on the value of the rectopexy stitches in prevention of prolapse. A combination of both of these may be successful in greatly reducing our prolapse rates in the future.

Our second most recurring problem was RUD. Overall, 37% of our patients developed varying degrees of this. This occurred much more frequently with patients with RBF than with the other types of ARM in our study. This could be explained by the long common wall between the rectum and the urethra and the upward angulation of the fistula as it terminates into the bulbous urethra, which obscures the view when using the laparoscope. This makes total resection of the fistula a challenge. Moreover, there is an inherent risk of damage to the urethra coupled with our early inexperience with deep pelvic dissections using laparoscopy which made us shy away from taking our dissection too far. This is what may explain our high incidence of post-LAARP RUD, which was the same explanation offered by Jung *et al.* [13].

To overcome this problem, several solutions were recommended by many authors. Some suggested completely abolishing the use of LAARP in patients with RBF and restricting it to ARM with RPFs or rectovesical fistulas [16]. Other authors proposed modifying the technique to deal with RBFs and avoid the development of a RUD [10,11,14,17,19]. Till now, none of our patients who developed a RUD showed any symptoms or were subjected to surgical resection.

The results obtained when calculating the RAA in our study group reflected our ability to attain good rectal placement within the levator ani and puborectalis sling. We coupled this with MRI studies of the pelvis. Our MRI scoring system was based on that reported by Ichijo *et al.* [6] and Koga *et al.* [10]. Scores obtained using both these methods reflected our ability to place the rectum within the confines of the muscle sphincter with a high degree of accuracy. We should state however that interpretation of the MRI may be subjective affecting the results obtained [6].

To evaluate the functional outcome, we adopted the fecal continence evaluation questionnaire (FEQ or CEQ) [6]. We chose this as it was most suited for our study. This is because we wanted to offer a functional evaluation of the technique, but most of our patients would not have passed the age of 4 years, which is required to implement scores such as the Kelly continence score [3,14], the Krinkenberg score [10], and the Rintala questionnaire [14,18]. Our results reflected a good outcome for LAARP regarding continence; however, annual measurements to assess progression are required. We are also thinking of applying other scores to evaluate functional outcome when our patients get older in the future.

Conclusion

LAARP offers a great alternative to manage intermediate and high ARMs in boys; however, this is not without its problems. Rectal mucosal prolapse and RUD remain the most frequently recurring complications following LAARP. Methods for prevention of these complications must be more objectively assessed in the future.

Conflicts of interest

There are no conflicts of interest.

References

- 1 Georgeson KE, Inge TH, Albanese CT. Laparoscopically assisted anorectal pull-through for high imperforate anus – a new technique. *J Pediatr Surg* 2000; **35**:927–931.
- 2 DeVries PA, Pena A. Posterior sagittal anorectoplasty. *J Pediatr Surg* 1982; **17**:638–643.
- 3 Kudou S, Iwanaka T, Kawashima H, Uchida H, Nishi A, Yotsumoto K, Kaneko M. Midterm follow-up study of high-type imperforate anus after laparoscopically assisted anorectoplasty. *J Pediatr Surg* 2005; **40**:1923–1926.
- 4 Lima M, Tursini S, Ruggeri G, Aquino A, Gargano T, De Biagi L, et al. Laparoscopically assisted anorectal pull-through for high imperforate anus: three years' experience. *J Laparoendosc Adv Surg Tech* 2006; **1**:63–66.
- 5 Georgeson K. Laparoscopic assisted anorectal pull-through. *Semin Pediatr Surg* 2007; **16**:266–269.
- 6 Ichijo C, Kaneyama K, Hayashi Y, Koga H, Okazaki T, Lane GJ, et al. Midterm postoperative clinicoradiological analysis of surgery for high/intermediate-type imperforate anus: prospective comparative study between laparoscopy-assisted and posterior sagittal anorectoplasty. *J Pediatr Surg* 2008; **43**:158–163.
- 7 Pena A, Bischoff A. Treatment of colorectal problems in children. In: Pena A, Bischoff A, editors. *Surgical treatment of colorectal problems in children*, 1st ed. Springer International Publishing Switzerland; 2015.
- 8 Holschneider A, Hutson J, Pena A, Beket E, Chatterjee S, Coran A, et al. Preliminary report on the international conference for the development of standards for the treatment of anorectal malformations. *J Pediatr Surg* 2005; **40**:1521–1526.
- 9 Kiely EM, Pena A. Anorectal malformations. In: O'Neill JA, Rowe MI, Grosfeld JL, Fonkalsrud EW, Coran AG, editors. *Pediatric surgery*, 5th ed. New York, NY: Mosby; 1998; **95**: pp. 1425–1448.
- 10 Koga H, Kato Y, Shimotakahara A, Miyano G, Lane GJ, Okazaki T, et al. Intraoperative measurement of rectourethral fistula: prevention of incomplete excision in male patients with high-/intermediate-type imperforate anus. *J Pediatr Surg* 2010; **45**:397–400.
- 11 Van der Zee DC, Dik P, Beek FJ. Laparoscopic assisted anorectal pull-through in anorectal malformations: a reappraisal. *World J Surg* 2013; **37**:1934–1939.
- 12 Koga H, Ochi T, Okawada M, Doi T, Lane GJ, Yamataka A. Comparison of outcomes between laparoscopy-assisted and posterior sagittal anorectoplasties for male imperforate anus with recto-bulbar fistula. *J Pediatr Surg* 2014; **49**:1815–1817.
- 13 Jung SM, Lee SK, Seo JM. Experience with laparoscopic-assisted anorectal pull-through in 25 males with anorectal malformation and rectourethral or rectovesical fistulae: postoperative complications and functional results. *J Pediatr Surg* 2013; **48**:591–596.
- 14 Ruggeri G, Destro F, Randi B, Lima M. Laparoscopic-assisted anorectal pull-through for high imperforate anus: 14 years' experience in a single center. *J Laparoendosc Adv Surg Tech* 2016; **26**:404–408.
- 15 Leung JL, Chung PH, Tam PK, Wong KK. Application of anchoring stitch prevents rectal prolapse in laparoscopic assisted anorectal pullthrough. *J Pediatr Surg* 2016; **51**:2113–2116.
- 16 Bischoff A, Levitt MA, Pena A. Laparoscopy and its use in the repair of anorectal malformations. *J Pediatr Surg* 2011; **46**:1609–1617.
- 17 Rollins MD, Downey EC, Meyers RL, Scaife ER. Division of the fistula in laparoscopic assisted repair of anorectal malformations – are clips or ties necessary? *J Pediatr Surg* 2009; **44**:298–301.
- 18 Rintala RJ, Lindahl H. Is normal bowel function possible after repair of intermediate and high anorectal malformations? *J Pediatr Surg* 1995; **30**:491–494.
- 19 Wang C, Diao M, Li L, Liu S, Chen Z, Li X, Cheng W. Laparoscopic dissection and division of distal fistula in boys with rectourethral fistula. *J Surg Res* 2017; **211**:147–153.