

Laparoscopic removal of autoamputated adnexa in infants and neonates

Mirko Bertozzi and Antonino Appignani

Objective The aim of this study was to describe a new case of autoamputated adnexa in a neonate treated with laparoscopy and to present a review of the literature as regards laparoscopic management of the autoamputated adnexa in neonates and infants.

Summary background data Laparoscopic surgery has become an accepted modality internationally in neonates and infants. We analyzed technical details of laparoscopic procedures adopted in the literature for this rare condition.

Materials and methods A literature review was performed to identify additional cases of autoamputated adnexa treated laparoscopically. Cases were limited to the English language and to those affecting girls under 1 year of age.

Results In addition to our presented case, 12 cases of autoamputated adnexa in patients less than 1 year of age treated laparoscopically were identified in the literature. Surgical intervention was planned for increasing size of cysts, for no signs of reduction, or for complex cysts, except in one case for suspicion of enteric duplication. The number of ports for the removal varies from one to three based on different authors. The operative port size ranged

from 3 to 5 mm. Camera size was 5 mm for all authors when reported but only five authors reported the size of the umbilical port.

Conclusion Although laparoscopic removal of autoamputated adnexa can be successfully accomplished in newborns and infants, 50% of autoamputated adnexa are still treated with laparotomy. Our review revealed the necessity of at least two ports for the identification and removal of the adnexa using the laparoscopic-assisted technique, whereas three trocars in the presence of tenacious adhesions. *Ann Pediatr Surg* 11:213–217 © 2015 Annals of Pediatric Surgery.

Annals of Pediatric Surgery 2015, 11:213–217

Keywords: adnexal torsion, autoamputated adnexa, laparoscopy, technique

S.C. di Clinica Chirurgica Pediatrica, University of Perugia, S. Maria della Misericordia Hospital 06100 S. Andrea delle Fratte, Perugia, Italy

Correspondence to Mirko Bertozzi, MD, S.C. di Clinica Chirurgica Pediatrica, University of Perugia, S. Maria della Misericordia Hospital Loc. S. Andrea delle Fratte 06100 Perugia, Italy
Tel: +39 075 578 6451; fax: +39 075 578 3376;
e-mail: mirkobertozzi@hotmail.com

Received 8 April 2015 accepted 27 August 2015

Introduction

Autoamputation of the ovary has been reported in both children and adults and it is thought to result from the torsion of a normal or cystic ovary, with subsequent infarction, necrosis, and detachment [1–3]. The autoamputated structure may adhere to another surface, or become a free-floating, possibly calcified intraperitoneal item. Autoamputated adnexa can probably be hypothesized in cases presenting with freely mobile or variable location abdominal masses at ultrasound scanning (US). The definitive diagnosis of this rare complication can be made mostly after surgical exploration. Although in the last 15 years minimally invasive surgery has become widespread in newborns as well, laparoscopic treatment of autoamputated adnexa is rarely reported in the literature. A new case of autoamputated adnexa in a neonate treated by means of laparoscopy is described and review of the literature about laparoscopic management of the autoamputated adnexa in neonates and infants has been performed to evaluate technical differences.

Case description

A 36-week-old female fetus presented with a left lower abdominal cystic mass measuring 4.0 × 3.2 cm on antenatal US. The baby was born at 40 weeks of gestation age with an uneventful vaginal delivery and a birth weight of 3650 g. Physical examination was normal, with no palpable abdominal mass. Hematologic and biochemical investigations were normal.

Postdelivery US revealed a cystic mass measuring 4.9 × 3.2 cm in the left pelvis with a significant echogenicity indicating a hemorrhagic content and no evidence of vascular perfusion on color-flow Doppler scanning. After 15 days, another US showed that the dimensions of the mass remained unvaried. Because of this finding an autoamputation or prenatal adnexal torsion was hypothesized by our radiologists; therefore, a surgery was planned and the newborn underwent elective laparoscopy. The procedure was performed under general anesthesia. Physical examination performed before surgery under anesthesia revealed a round palpable mass in the left lower abdomen.

A 10-mm port with pneumatic anchorage was inserted through the umbilical incision with Hasson's technique. The abdomen was insufflated to a pressure of 6 mmHg. A brown smooth cystic lesion measuring ~4.5 cm was found in the left iliac fossa.

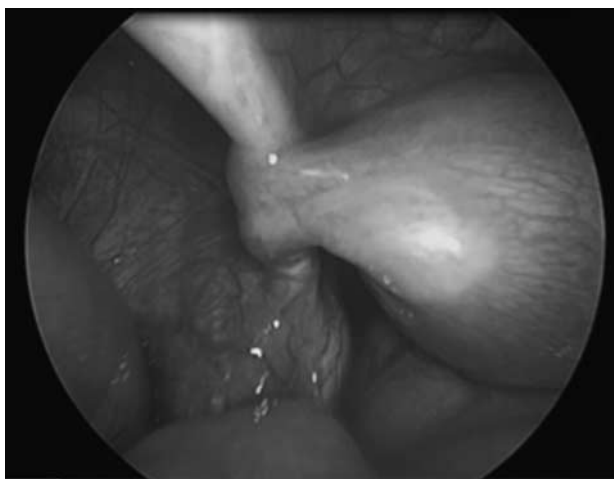A second operative 3-mm port was placed in the left flank. Inspection of genitalia revealed absence of the left ovary and the left fallopian tube ending in a blind short stump (Fig. 1). The right ovary was explored and found normal.

The cyst was then mobilized with an atraumatic grasper. An intravenous 14-G catheter was inserted through the abdominal wall just over the cyst and under direct laparoscopic vision through the wall of the cyst. Aspiration

of cyst content was performed avoiding spillage by suction of 30 ml of hemorrhagic fluid until the cyst was partially drained (Fig. 2). The needle was withdrawn and the cyst was moved with the grasper until it was situated just under the umbilical port and then completely delivered through the umbilical incision (Fig. 3). The exteriorized cyst appeared to have a fine and loose pedicle ending in the suspensory ligament of the ovary; this was resected extracorporeally by means of bipolar cauterization. After the complete excision of the cyst the umbilical incision was closed using skin and fascia sutures, and the left incision was repaired by application of strips.

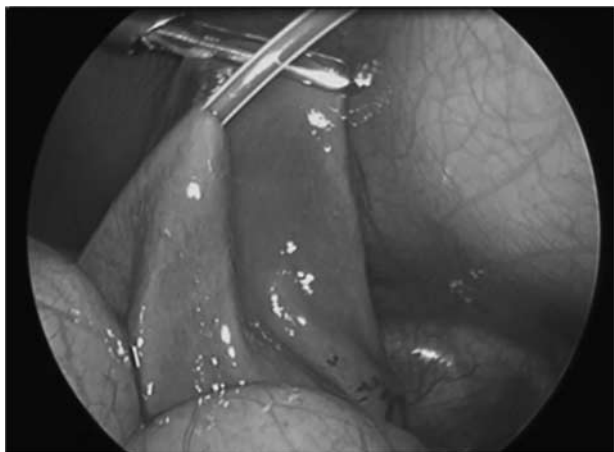Histological examination showed extensive hemorrhagic necrotic autolytic tissue with dystrophic calcification, containing ovarian tissue and congestion of the ovarian vessels with thrombosis. The postoperative course was uneventful, and the patient was discharged on postoperative day 2.

Fig. 1



Inspection of the genitalia showing the absence of the left ovary and a blind short stump of the left fallopian tube.

Fig. 2



The adnexa partially drained using a 14-G catheter inserted through the abdominal wall under direct laparoscopic vision.

Materials and methods

A literature review was performed to identify additional cases of autoamputated adnexa treated laparoscopically to provide a comprehensive review to analyze technical details.

Cases were limited to the English language and to those affecting girls under 1 year of age.

The following information was analyzed: (a) reasons for surgical intervention; (b) adnexa involved; (c) volume of established carboperitoneum; (d) number of utilized trocars; (e) umbilical port size; (f) camera size; (g) operative port size; (h) exteriorization method of the autoamputated adnexa; (i) presence of attachments; and (j) postoperative hospital stay.

The procedures were conducted according to ethical standards of the Helsinki Declaration of 1975.

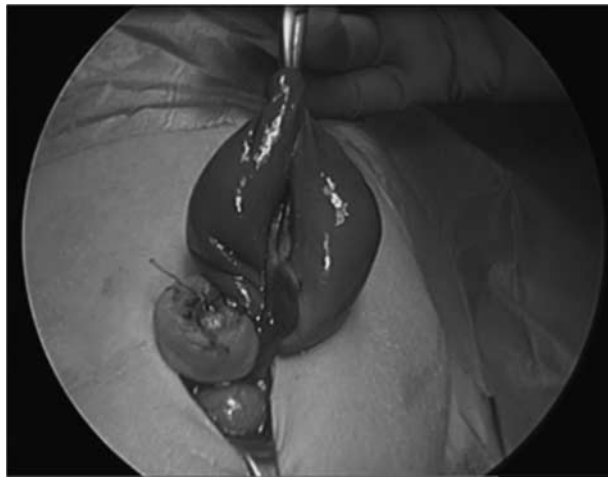
Results

Our review identified other 12 cases of autoamputated adnexa treated laparoscopically in infants and neonates. Six authors published case reports, one author reported two cases, and one author reported a case series of five patients. Five of 13 patients were treated when newborns, including our patient. The data on the five additional patients presented by an author were summarized in aggregates (age ranging from 9 days to 7.5 months). All patients except one (12/13) had a prenatal diagnosis of fetal cyst identified by means of ultrasound. Age at intervention ranged from 2 to 7.5 days.

Surgical intervention was planned for increasing size of cysts, for no signs of reduction, or for complex cysts, except in one case in which intervention was performed for suspicion of enteric duplication.

Only four patients had a mobile mass present in the peritoneal cavity, two of these masses were free-floating cysts, whereas the other two were side changing. Excluding the cumulative data, the left ovary was involved in most cases (7/8) (Table 1).

Fig. 3



The adnexa completely delivered through the 10 mm umbilical incision.

Laparoscopic intervention was performed using a carboperitoneum with a pressure of 8–10 mmHg in three cases and 6–10 mmHg in five cases. A carboperitoneum of 8 mmHg was recorded in two cases, in one case it was of 6 mmHg, and in two cases it was not reported.

The number of trocars utilized was as follows: one in one case, two in four cases, and three in three cases. Umbilical

port size was reported in nine cases ranging from 5 to 12 mm and camera size, if described, was 5 mm in all cases.

Operative port size and place, cyst exteriorization method, cyst attachments, and postoperative hospitalization that ranged from 1 to 5 days are described in Table 2.

Table 1 Review of the literature showing authors publishing paper about laparoscopic treatment of autoamputated adnexa in newborn and infants

References	Number of patients	Prenatal US diagnosis	Age at intervention	Preoperative diagnosis	Reasons for surgical intervention	Adnexa involved
Jawad <i>et al.</i> [4]	1	3.4 × 3.1 cm cystic mass	5 months	US: 4.2 × 3.7 cm pelvic cystic mass with echogenic findings	Increased size	Left tube/ovary
Decker <i>et al.</i> [5]	1	Pelvic cyst	6 weeks	US: 3.0 × 4.0 complex right ovarian cyst with echogenic findings	Increased size and complex cysts	Right tube/ovary
Tseng <i>et al.</i> [6]	5	Cystic masses; Range 3.7–6.5 cm	Range 9 days to 7.5 months	US: complex cystic masses; Range 3.9–7.6 cm	Increased size and complex cysts	–
Visnjic <i>et al.</i> [7]	1	4 cm diameter cyst left lower abdomen	4 weeks	US: 4.5 cm cystic mass with echogenic findings on the right side of the abdomen	No signs of reduction and complex cyst	Left tube/ovary
Zampieri <i>et al.</i> [8]	2	3.5 × 3 cm abdominal cyst 3.5 × 4.5 Pelvic cyst	2 days	US: 5.2 × 6 cm free-floating abdominal cyst without blood support and fluid/debris levels US: 4.5 × 5 cm free-floating abdominal cyst	Increased size and complex cysts Increased size	Left tube/ovary
Kuwata <i>et al.</i> [9]	1	4.3 × 3.6 cm abdominal cyst with echogenic content	4 days	MRI confirming prenatal US with 'side-changing' cyst	Increased size and complex cysts	Left tube/ovary
Castellani <i>et al.</i> [10]	1	–	2.5 months	US: Abdominal complex cyst	Suspected enteric duplication	Left tube/ovary
This study	1	4.0 × 3.2 cm left lower abdominal cyst	15 days	US: 4.9 × 3.2 cm cystic mass with echogenic findings without blood support on the left pelvis	Increased size and complex cysts	Left tube/ovary

Details about description of prenatal ultrasonographic findings, age at the intervention, postnatal US or MRI description, reasons for surgical intervention and adnexa involved are reported.
US, ultrasound scanning.

Table 2 Technical details of different laparoscopic procedures for autoamputated adnexa in newborns and infants reported in the literature

References	Number of patients	Carboperitoneum (mmHg)	Number of trocars	Umbilical port size (mm)	Camera size (mm)	Operative port size (mm) and place	Exteriorization cyst's method	Cyst's attachments	Postoperative hospital stay (days)
Jawad <i>et al.</i> [4]	1	8	2	10	5	1 (5 mm port) Right iliac fossa	Opened and suctioned through the umbilical port	–	2
Decker <i>et al.</i> [5]	1	8–10	3	–	5	2 (5 mm ports) Left and right upper quadrants	Delivered entirely by enlarging the umbilical port	Cyst hilum attached to the omentum	1
Tseng <i>et al.</i> [6]	5	6–10	2	5	1 (3/5 mm port) Left midabdomen	Intracorporeally aspirated through the umbilical port	4 cases: tethered by a fine vascular pedicle from the suspensory ligament of the ovary	–	1
Visnjic <i>et al.</i> [7]	1	8	2	12	1 (5 mm port) Left lower abdominal quadrant	Percutaneously aspirated using a needle	Loose adhesions	–	–
Zampieri <i>et al.</i> [8]	2	8–10	3 1	5	–5	2 (5 mm ports)	Percutaneously aspirated using a needle	–	–
Kuwata <i>et al.</i> [9]	1	–	–	–	–	–	–	–	–
Castellani <i>et al.</i> [10]	1	–	3	–	5	2 (3 mm ports) Left and right midabdomen	–	2 pedicles: one ending at the antimesenteric border of the midsigmoid colon and the other in the greater omentum	5
This study	1	5	2	10	5	1 (3 mm port) Left midabdomen	Percutaneously aspirated using a needle	Fine pedicle ending in the suspensory ligament of the ovary	2

It shows details of the removed adnex and postoperative hospital stay.

Discussion

Fetal ovaries are subject to the development of cysts because of the surrounding hormonal environment. Most of these are small simple cysts. Infants with simple cysts less than 4 cm in diameter should be initially approached conservatively with a postnatal US follow-up, as the majority of these cysts will resolve spontaneously. Larger cysts may require surgical intervention, especially if the lesions convert from simple to complex on ultrasound imaging suggesting hemorrhage or torsion, or if the neonate is symptomatic [11]. Although there have been reports of some rare cases of benign cystic teratomas, ovarian cysts in infants are generally benign [12,13].

Prenatal or postnatal ovarian cyst complications are rather frequent, including intracystic bleeding, torsion of the cyst or of its corresponding adnexa. The incidence of fetal ovarian torsion as a complication of ovarian cysts was reported to be as high as 50–78% [4,14].

Torsion of cysts can cause complications such as intestinal obstruction or perforation or rupture of the cyst, whereas consequences of adnexal torsion may be catastrophic [15].

Although rarely seen, an autoamputation could be the final sequel of ischemia and infarction of adnexa torsion. The autoamputated adnexa can cause complications such as acute abdomen [16] and amputated-tumor reimplantation in the omentum [17]. Considering these possibilities, some authors suggest that early surgical removal of autoamputated adnexa is preferable to a wait-and-see approach [18].

Although autoamputated adnexa is a rare but well-known result of adnexal torsion, preoperative diagnosis remains a challenge. Indeed some authors consider a freely mobile mass, so-called ‘wandering tumor’ or ‘free-floating’ abdominal cyst, as a sign of an autoamputated adnexa; however, it is sometimes difficult to determine this finding in a neonate, whereas a ‘side change’, as reported by Kuwata *et al.* [9], may be quite easy to notice. We believe that a cystic mass with a significantly echoic content indicating a hemorrhagic cyst and no evidence of vascular perfusion at color-flow Doppler scanning associated with the signs described above can suggest the diagnosis of autoamputated adnexa.

Historically, in the case of surgical intervention, autoamputated adnexa have been treated by means of laparotomy; however, modern laparoscopic equipment provides a much less invasive alternative. The use of minimally invasive surgery in newborns is becoming well accepted, and, in the last 15 years, the increasing experience has led to an increase in the spectrum of such procedures. Nevertheless, since the first reported case of autoamputated adnexa laparoscopically removed in an infant [4], about 50% of the reported cases are still treated by means of laparotomy [19].

To date, in the English medical literature, only seven papers report a laparoscopic treatment of autoamputated adnexa in newborns and infants, with a total of 12 cases that underwent removal [4–10].

To analyze different laparoscopic techniques for all cases, we also collected a description of carboperitoneum pressure, number of trocars utilized, umbilical port size, camera size, place and size of operative ports, exteriorization cyst method, and cyst’s attachments.

Carboperitoneum was established with a pressure ranging from 6 to 10 mmHg. We believe that, because carboperitoneum pressure and its duration can cause possible complications in newborns [20], low pressures are preferable. In our case, we adopted a trocar with pneumatic anchorage and because of which the assistant surgeon could perform slight abdominal wall traction, allowing a good working space at low pressure [21].

The number of ports for the removal varies from one to three according to different authors. For autoamputated adnexa with loose adhesions or fine pedicles, the use of two trocars, as well as three trocars, appears to be a safe technique. In case of more tenacious adhesions, the use of three trocars is necessary. The use of only one trocar with a 5 mm-sized camera described by Zampieri and colleagues in one of their cases seems to be only diagnostic because the entire drainage and removal of the autoamputated adnexa was accomplished through the umbilical incision without the need for laparoscopy. The operative port size ranged from 3 to 5 mm. Camera size was 5 mm for all authors when reported, but only five authors reported the size of the umbilical port, which can range from 5 to 12 mm. Only Decker *et al.* [5] described the delivery of the entire autoamputated adnexa without its drainage by enlarging the umbilical port incision. The remaining authors adopted intra-abdominal drainage of the adnexa and then its delivery through the umbilical incision. Adnexa delivery through a 5 mm port after intracorporeal suction has been reported by two authors [6,8], but it is reasonable to believe that this maneuver is not simple to perform and can become dangerous. The increasing manipulation during adnexa delivery through a 5 mm incision may in fact lead to a possible risk of perforation and peritoneal spillage. In our experience, a 10 mm umbilical incision is a good choice for laparoscopic-assisted excision of abdominal cystic masses [22]; in the case described above, it seems to be effective for adnexa delivery after its intracorporeal suction. When the autoamputated adnexa is delivered from the umbilical incision, loose adhesions can be easily resected extracorporeally.

Our choice to use a 10 mm umbilical and an operative 3 mm trocar appeared safe and effective, with minimal abdominal traumatism and postoperative scars. The 10 mm umbilical incision was a good choice to exteriorize easily the drained cyst without a possible perforation and/or spillage. As regards cosmetic results, the 10 mm incision was hidden by the umbilical scar, whereas the 3 mm incision left an almost invisible scar.

Conclusion

Although laparoscopic removal of autoamputated adnexa can be successfully accomplished in newborns and infants, 50% of autoamputated adnexa are still treated by means of laparotomy. During neonatal laparoscopic

procedures, low pressures of carboperitoneum are preferable to avoid related complications. There are many differences among authors as regards trocar size and umbilical port size. This review revealed the necessity of at least two ports for the identification and removal of the adnexa using the laparoscopic-assisted technique, whereas three trocars proved useful in the presence of tenacious adhesions between the adnexa and other tissues.

Although the articles published on this subject are not numerous, the authors apply similar techniques but with differences in the number and size of trocars and in the autoamputated adnexa delivery technique.

Acknowledgements

Conflicts of interest

There are no conflicts of interest.

References

- Nixon GW, Condon VR. Amputated ovary: a cause of migratory abdominal calcification. *Am J Roentgenol* 1977; **128**:1053–1055.
- Kennedy LA, Pinckney LE, Currarino G, Votteler TP. Amputated calcified ovaries in children. *Radiology* 1981; **141**:83–86.
- Keshtgar AS, Turnock RR, Keshtgar AS, Turnock RR, Keshtgar AS, Turnock RR. Wandering calcified ovary in children. *Pediatr Surg Int* 1997; **12** (2/3): 215–216.
- Jawad AJ, Zaghmout O, al-Muzrakchi AD, al-Hammadi T. Laparoscopic removal of an autoamputated ovarian cyst in an infant. *Pediatr Surg Int* 1998; **13** (2–3):195–196.
- Decker PA, Chammas J, Sato TT. Laparoscopic diagnosis and management of ovarian torsion in the newborn. *JLS* 1999; **3**:141–143.
- Tseng D, Curran TJ, Silen ML. Minimally invasive management of the prenatally torted ovarian cyst. *J Pediatr Surg* 2002; **37**:1467–1469.
- Visnjic S, Domljan M, Zupancic B. Two-port laparoscopic management of an autoamputated ovarian cyst in a newborn. *J Minim Invasive Gynecol* 2008; **15**:366–369.
- Zampieri N, Sciri G, Zambon C, Ottolenghi A, Camoglio FS. Unusual presentation of antenatal ovarian torsion: free-floating abdominal cysts. Our experience and surgical management. *J Laparoendosc Adv Surg Tech A* 2009; **19** (Suppl 1):S149–S149S152.
- Kuwata T, Matsubara S, Maeda K. Autoamputation of fetal/neonatal ovarian tumor suspected by a 'side change' of the tumor. *J Reprod Med* 2011; **56** (1–2):91–92.
- Castellani C, Petnehazy T, Gtnehazyiner B, Saxena AK. A rare cause for a neonatal cystic abdominal mass. *J Minim Invasive Gynecol* 2013; **20**: 714–716.
- Luzzatto C, Midrio P, Toffolutti T, Suma V. Neonatal ovarian cysts: management and follow-up. *Pediatr Surg Int* 2000; **16** (1–2):56–59.
- Ikeda K, Suita S, Nakano H. Management of ovarian cyst detected antenatally. *J Pediatr Surg* 1988; **23**:432–435.
- Shalev E, Mann S, Romano S, Rahav D. Laparoscopic detorsion of adnexa in childhood: a case report. *J Pediatr Surg* 1991; **26**:1193–1194.
- Bagolan P, Giorlandino C, Nahom A, Bilancioni E, Trucchi A, Gatti C, et al. The management of fetal ovarian cysts. *J Pediatr Surg* 2002; **37**:25–30.
- Fitzhugh VA, Shaikh JR, Heller DS. Adnexal torsion leading to death of an infant. *J Pediatr Adolesc Gynecol* 2008; **21**:295–297.
- Uygun I, Aydogdu B, Okur MH, Otcu S. The first report of an intraperitoneal free-floating mass (an autoamputated ovary) causing an acute abdomen in a child. *Case Rep Surg* 2012; **2012**:2012. 615734.
- Ushakov FB, Meirov D, Prus D, Libson E, BenShushan A, Rojansky N. Parasitic ovarian dermoid tumor of the omentum – a review of the literature and report of two new cases. *Eur J Obstet Gynecol Reprod Biol* 1998; **81**:77–82.
- Koike Y, Inoue M, Uchida K, Kawamoto A, Yasuda H, Okugawa Y, et al. Ovarian autoamputation in a neonate: a case report with literature review. *Pediatr Surg Int* 2009; **25**:655–658.
- Focseneanu MA, Omurtag K, Ratts VS, Merritt DF. The auto-amputated adnexa: a review of findings in a pediatric population. *J Pediatr Adolesc Gynecol* 2013; **26**:305–313.
- Olsen M, Avery N, Khurana S, Laing R. Pneumoperitoneum for neonatal laparoscopy: how safe is it? *Paediatr Anaesth* 2013; **23**:457–459.
- Bertozzi M, Prestipino M, Nardi N, Appignani A. Preliminary experience with a new approach for infantile hypertrophic pyloric stenosis: the single-port, laparoscopic-assisted pyloromyotomy. *Surg Endosc* 2011; **25**:2039–2043.
- Bertozzi M, Nardi N, Prestipino M, Magrini E, Appignani A. Minimally invasive removal of urachal remnants in childhood. *Pediatr Med Chir* 2009; **31**: 265–268.