

Urethral stripping for delicate excision of dorsal accessory urethra

Amr A. Abou-Zeid

Duplication of the urethra is a rare anomaly. The accessory urethra may be dorsal or ventral, relative to the orthotopic urethra. Dorsal urethral duplication describes a normally located meatus and another accessory epispadiac meatus. Excision of the dorsal accessory urethra is usually curative, on the condition that the ventral orthotopic urethra is normal. However, most reports recommend surgery only when there are significant functional or cosmetic problems, for fear of possible damage to the neurovascular bundle, or the continence mechanism during surgical excision. In this report, we describe a modification for excising the dorsal accessory channel by stripping with minimal disturbance to the glans. With continuous refinement of the surgical technique together with more reports confirming its safety,

we believe that total excision of the dorsal accessory urethra can be offered to more patients as being the standard level of care. *Ann Pediatr Surg* 11:40–41 © 2015 *Annals of Pediatric Surgery*.

Annals of Pediatric Surgery 2015, 11:40–41

Keywords: accessory urethra, epispadias, urethral duplication

Department of Pediatric Surgery, Faculty of Medicine, Ain Shams University, Cairo, Egypt

Correspondence to Amr A. Abou-Zeid, MD, Faculty of Medicine, Ain Shams University, 11331 Cairo, Egypt

Tel: +2 01116560566; fax: +2 0224830833;
e-mail: amrabdelhamid@hotmail.com

Received 18 August 2013 accepted 14 June 2014

Introduction

Duplication of the urethra is a rare anomaly with about 300 cases reported in the literature. The accessory urethra may be dorsal or ventral, relative to the orthotopic urethra [1]. Several classifications have been proposed [2,3]; however, most authors would agree that each case should be managed on an individual basis [4].

Dorsal urethral duplication describes a normally located meatus and another accessory epispadiac meatus. The accessory meatus can be located in the midline on the dorsum of the penis, anywhere from the pubis to the tip of the glans [5]. Excision of the dorsal accessory urethra is usually curative, on the condition that the ventral orthotopic urethra is normal. In this report, we describe a modification for excising the dorsal accessory channel by stripping with minimal disturbance to the glans.

Case report

A 5-year-old boy presented with an accessory dorsal urethral meatus. There was no history of urine flow from this accessory meatus, and all the urine passed through the ventral orthotopic one. There was neither any history of urinary incontinence nor obstructive symptoms.

On examination, the patient was circumcised, and there was a degree of dorsal penile chordee. The accessory meatus was located on the dorsum of the glans, nearly midway between the normal orthotopic meatus and the coronal sulcus. A renal sonography was ordered to exclude possible associating anomalies, and the patient was listed for operative excision of the dorsal accessory urethra.

The parents were informed about the procedure and a written consent for excision of the accessory urethra was signed before surgery.

Surgical procedure

With the patient in the supine position, a catheter (8 Fr) was easily introduced into the urinary bladder through

the ventral orthotopic urethral meatus. Another catheter (6 Fr) was advanced through the dorsal accessory meatus till it stopped after some distance, indicating a blind-ending channel (type I urethral duplication [2]). We started by degloving of the penile skin. A midline longitudinal incision was made dorsally in the tunica albuginea to expose the underlying accessory urethral channel, while the catheter still inside to help in its identification (Fig. 1a). The accessory channel was dissected out from the dorsum of the penile shaft and was followed up proximally, till it tapered where it was transfixed and cut (Fig. 1b). Instead of incising through the vascular glans to excise the distal end of the accessory channel, we thought we can remove it by stripping. The dissected proximal end of the accessory channel was tied to the inside catheter by a silk stitch (Fig. 1b). The catheter was then gradually withdrawn out, stripping the accessory channel with it through the glans (Fig. 1c and d).

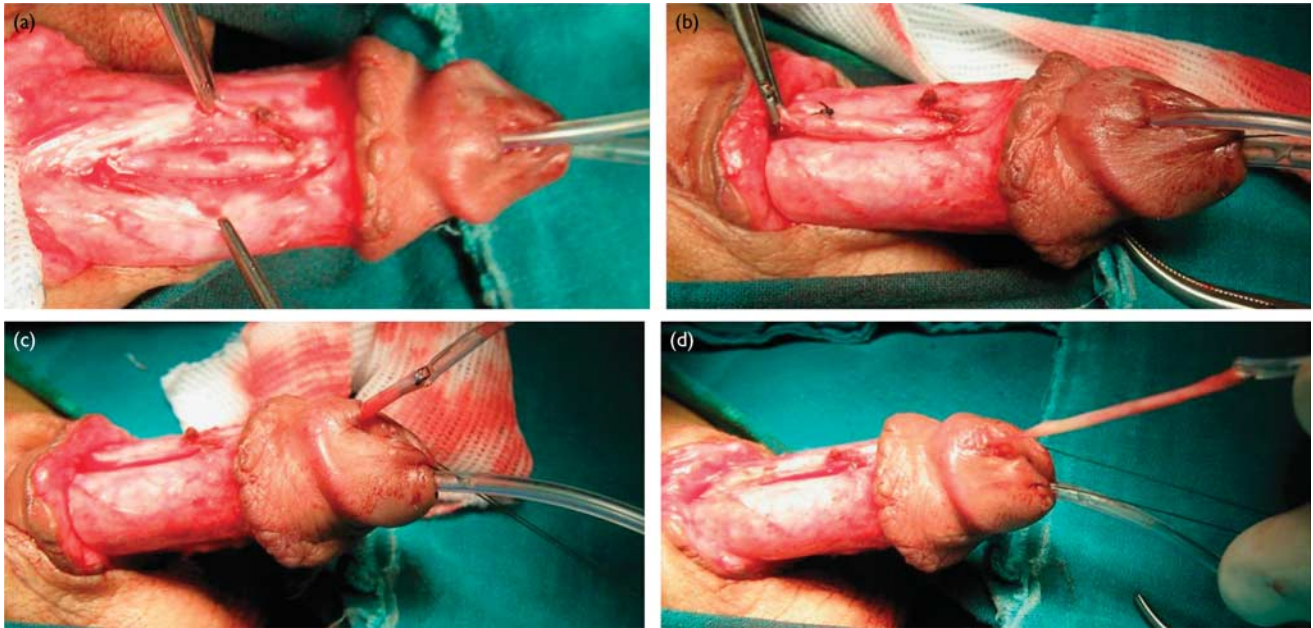
The site of the dorsal accessory meatus in the dorsum of the glans was closed by 6-0 polyglactin stitches. This was followed by covering the penile shaft with its skin and removal of the urinary catheter. The patient had an uneventful recovery and was discharged on analgesics.

Discussion

Urethral duplications are rare anomalies that a pediatric urologist may face sporadically in his career. In the literature, there are several classifications that grouped these anomalies in different ways: sagittal and collateral duplications; dorsal and ventral [3]; and complete, incomplete, or limited to a blind sinus [2].

Most urethral duplications occur in the sagittal plane. The ventral urethra is usually the functional one, whereas the dorsal urethra is often hypoplastic and of poor function. Excision of the dorsal accessory urethra is usually curative, on the condition that the ventral urethra

Fig. 1



Steps of stripping of the dorsal accessory urethra: (a) a midline longitudinal incision is made dorsally in the tunica albuginea to expose the underlying accessory urethral channel, while the catheter still inside to help in its identification; (b) the proximal end of the accessory channel is transfixed and cut; a silk stitch is used to tie the dissected proximal end of the accessory channel to the inside catheter; (c, d) the catheter is gradually withdrawn out, stripping the accessory channel with it through the glans.

is normal [4]. However, most reports recommend surgery only when there are significant functional or cosmetic problems, for fear of possible damage to the neurovascular bundle or the continence mechanism during surgical excision [4,5].

Other alternatives to surgery have been proposed as well. These included ablative interventions, fulguration, or sclerosis by injection of the accessory channel. However, these alternatives have been widely abandoned as they may result in unpredictable complications such as corporeal thrombosis or chordee because of fibrosis [1,4].

Another surgical alternative to excision can be applied when both the urethral orifices are close to each other at the tip of the glans. Cosmetic correction is achieved by joining both urethral openings into one orthotopic meatus. The common septum is divided, and some sort of glanuloplasty similar to that of distal epispadias repair is performed [6]. Although this technique eliminates the risk of damaging the sphincter mechanism during dissection near the proximal urethra, there is a potential risk for meatal stenosis and obliteration of the dorsal meatus [6]. Moreover, this technique cannot cure incontinence that may associate complete urethral duplication when urine is continuously dripping through the accessory channel.

Although there is no consensus regarding the best surgical approach in cases of urethral duplication, total surgical excision of the dorsal accessory urethra appears to offer the best solution. This has been reported by Salle *et al.* [4] in their series that showed successful excision in eight cases without complications, using the penile

approach and sometimes combined with retropubic approach.

Here, we report a slight modification regarding the total excision of the dorsal accessory urethra. After performing the standard penile approach in dealing with the proximal part of the accessory channel, the distal intraglandular part is stripped out with minimal disturbance to the glans. We believe that this modification can help to achieve the desired delicate surgical technique. This is recommended to decrease the risk of damage that may result during excision of such a benign pathology. With continuous refinement of the surgical technique together with more reports confirming its safety, we believe that total surgical excision of the dorsal accessory urethra can be offered to more patients as being the standard level of care.

Acknowledgements

Conflicts of interest

There are no conflicts of interest.

References

- Podesta ML, Medel R, Castera R, Ruarte AC. Urethral duplication in children: surgical treatment and results. *J Urol* 1998; **160**:1830–1833.
- Effmann EL, Lebowitz RL, Colodny AH. Duplication of the urethra. *Radiology* 1976; **119**:179–185.
- Williams DI, Kenawi MM. Urethral duplications in the male. *Eur Urol* 1975; **1**:209–215.
- Salle JL, Sibai H, Rosenstein D, Brzezinski AE, Corcos J. Urethral duplication in the male: review of 16 cases. *J Urol* 2000; **163**:1936–1940.
- RA Coleman, Winkle DC, Borzi PA. Urethral duplication: cases of ventral and dorsal complete duplication and review of the literature. *J Pediatr Urol* 2010; **6**:188–191.
- Alanee S, Gupta P, Gleich P, Shukla AR. Complete urethral duplication: description of surgical approach mimicking distal epispadias repair. *J Pediatr Urol* 2012; **8**:343–347.