

# Disseminated mucormycosis and necrotizing fasciitis in immune-compromised patients: two case reports

Machoki S. Mugambi<sup>a</sup>, Andre Theron<sup>a</sup>, Sharon Cox<sup>a</sup>, Komala Pillay<sup>b</sup>, Alastair J.W. Millar<sup>a</sup> and Alp Numanoglu<sup>a</sup>

We present two case reports of disseminated mucormycosis and necrotizing fasciitis in an immune-compromised patient. First, a 3-month-old with untreated HIV infection presented in septic shock with abdominal wall-necrotizing fasciitis. Laparotomy revealed extensive abdominal wall necrosis, bowel, liver, kidney and subsequent retroperitoneal, posterior diaphragm and inferior vena cava involvement. Second, a 3-year-old on chemotherapy for Burkitt's lymphoma presented with pancytopenia, sepsis, abdominal wall-necrotizing fasciitis and left lower limb ischaemia. At surgery, there was necrosis of the abdominal wall, the large bowel and the ureter and thrombosis of the iliac vessels. Histology in both cases showed necrosis with fungal invasion consistent with mucormycosis. Both patients suffered mortality. We discuss mucormycosis and review the literature regarding

mucormycosis in immune-compromised paediatric patients. *Ann Pediatr Surg* 11:35–39 © 2015 Annals of Pediatric Surgery.

*Annals of Pediatric Surgery* 2015, 11:35–39

**Keywords:** child, immune-compromised, mucormycosis, necrotizing fasciitis, paediatric

<sup>a</sup>Department of Paediatric Surgery and <sup>b</sup>National Health Laboratory Service, Red Cross War Memorial Children's Hospital and University of Cape Town, Cape Town, South Africa

Correspondence to Andre Theron, MBChB, Department of Paediatric Surgery, 6th Floor ICH Building, Red Cross War Memorial Children's Hospital, Klipfontein Road, Rondebosch, 7700 Western Cape, Cape Town, 7700 South Africa  
Tel: +27 21 658 5432; fax: +27 21 685 6632;  
e-mail: andre.theron@gmail.com

Received 25 August 2014 accepted 19 December 2014

## Background

Mucormycosis is an infection caused by a fungus of the order Mucorales. These fungi are found commonly in organic matter and soil and have clinical relevance in affecting mostly immune-compromised hosts. The infection can present in multiple ways, and if disseminated, is fatal in most cases. Disseminated mucormycosis is also rare in paediatric HIV/AIDS patients. Early recognition, urgent histological confirmation and aggressive debridement combined with amphotericin B therapy could perhaps prevent the usual fatal outcome.

## Case reports

### Patient 1

A 3-month-old, 4 kg female patient was transferred from an outside institution to our ICU, intubated and ventilated for respiratory failure secondary to *Pneumocystis jirovecii* pneumonia. She was being treated with sulfamethoxazole/trimethoprim. The patient had also been on hydrocortisone for 5 days, which was later changed to oral prednisolone. She was confirmed to have HIV/AIDS infection on PCR assay with a CD4 count of 4 cells/mm<sup>3</sup>. Cytomegalovirus was isolated on nasopharyngeal aspirate and later in the blood with a viral load of 53 780 counts/ml. While on treatment for *P. jirovecii* pneumonia, ganciclovir for cytomegalovirus and abacavir, zalcitabine and lamivudine for HIV, she developed thrombocytopenia. At the referring institution, the abdominal wall had become indurated, discolored and firm. Suspecting necrotizing fasciitis, the indurated area was incised and a serous effluent without features of necrosis was noted. Culture of the fluid had no yield.

Increasing respiratory dysfunction required high flow oscillatory ventilation. Empirical treatment with broad-

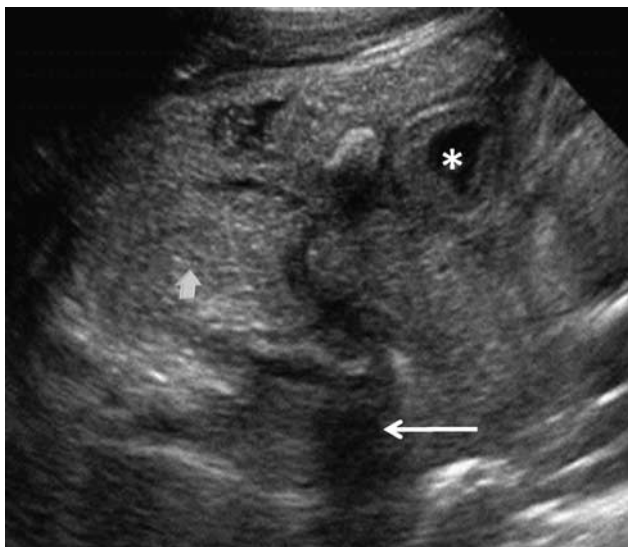
spectrum antibiotics and fluconazole was started. Subsequent bronchoalveolar lavage and urine samples grew candida on culture.

Abdominal distension, hepatomegaly associated with a right-flank mass, persistence of the erythema and induration and bloody stool developed over the following 72 h. A radiograph of the abdomen showed a paucity of bowel gas and an ultrasound scan of the abdomen showed significant ascites, a large hyperechoic liver and thickened bowel loops (Fig. 1).

The patient was in septic shock with multiorgan dysfunction, requiring inotropic support. On correction of the coagulopathy and anaemia with blood product administration, the patient underwent an exploratory laparotomy while on high flow oscillatory ventilation in the ICU. At surgery, the entire right abdominal wall was found to have full-thickness dry necrosis, and there was disintegration of the terminal ileum, the caecum and the ascending colon, forming an inflammatory mass around a central cavity filled with bowel effluent. The right kidney and the ureter were necrotic, with a grey-black and velvety appearance. The lateral duodenal wall serosa was greyish, but not perforated. The inferior surface of the right lobe of the liver was dusky, with a greyish discoloration of the capsule. The abdominal wall was excised to bleeding edges, the necrotic bowel was resected and the ends tied off, a right nephrectomy was performed and the undersurface of the liver was debrided (Fig. 2). A modified Bogota bag was applied to the abdominal wall fascia and low negative-pressure wound closure was applied.

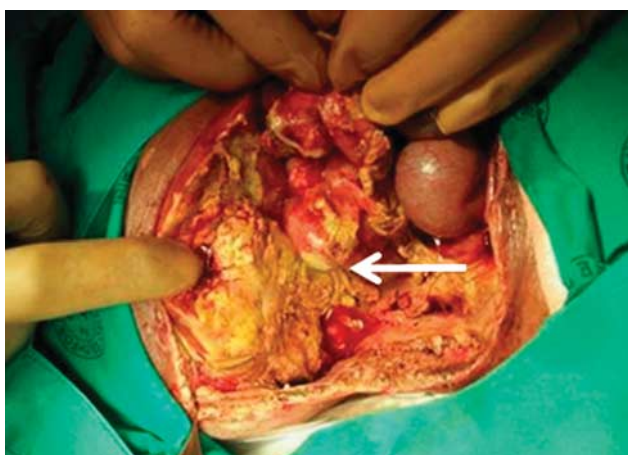
Subsequent to the aggressive damage control surgery, the patient's condition improved. Daily planned relook

Fig. 1



An ultrasound image of patient 1 showing the thickened bowel loop (asterisk), hyperechoic liver and free fluid (arrow head and arrow respectively).

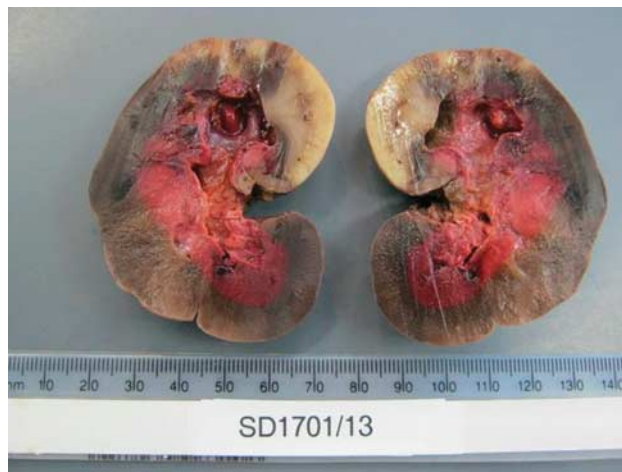Fig. 2



An intraoperative picture of patient 1. Note the empty renal bed inferiorly, necrotic patch on the duodenum (arrow) and the necrotic liver. The anterior abdominal wall has been excised.

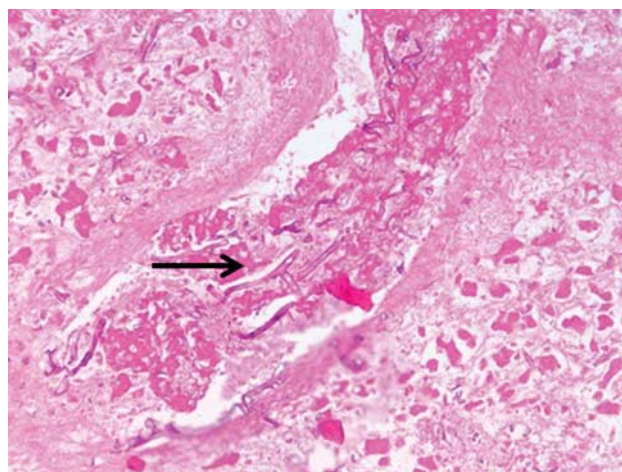
laparotomies revealed rapid progression of necrosis. At the third operation, the destructive process had spread to the psoas muscle, the iliac crest fascia and segments VI and VIII of the liver. The sigmoid colon was also noted to have an area of full-thickness necrosis. Histology of all the resected specimens showed extensive necrosis, with abundant fungal organisms consistent with mucormycosis (Figs 3 and 4). The patient was commenced on liposomal amphotericin B. At the fourth laparotomy, the necrosis had progressed to involve the retroperitoneal paraspinal muscles, the posterior right hemidiaphragm, the inferior vena cava and the duodenum. The disease had advanced further within the liver. At this stage, the patient was in multiorgan failure and deemed unsalvageable. After discussions with the parents, it was agreed to offer palliative treatment only and the patient died within 24h.

Fig. 3



Patient 1: Right nephrectomy specimen showing extensive haemorrhagic infarction.

Fig. 4



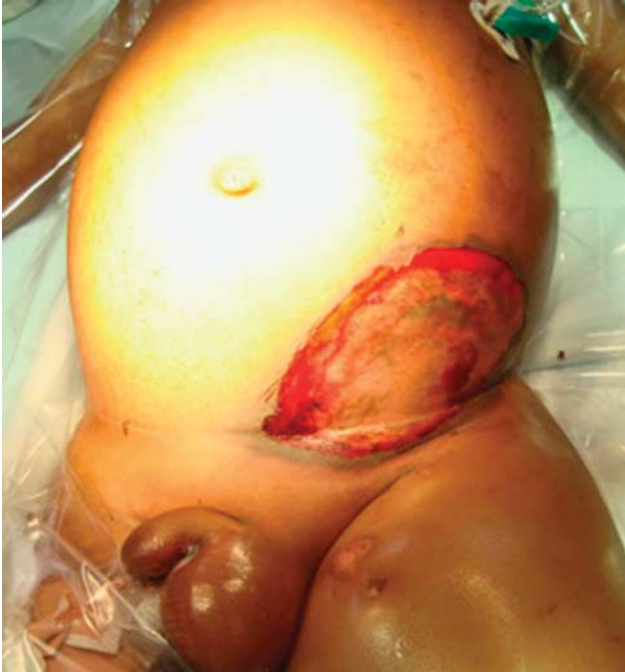Patient 1: Haematoxylin and eosin stain showing broad nonseptate fungal hyphae with 90° branching (arrow) consistent with that seen in mucormycosis plugging vessels and infiltrating through the surrounding necrotic tissue (high power).

**Patient 2**

A 3-year-old male patient, who had completed the second course of chemotherapy [COPDAM: C = cyclophosphamide, O = vincristine (oncovin), P = prednisolone, A = doxorubicin (adriamycin), M = methotrexate] for Burkitt's lymphoma 2 weeks before, was admitted to ICU with febrile neutropenia (white cells of  $0.03 \times 10^9/l$ ), severe mucositis, intestinal obstruction and a small bullous lesion on the left lower abdomen. He also had a swollen left leg with confirmed deep venous thrombosis on Doppler ultrasonography.

The bullous lesion evolved rapidly within hours into a necrotic patch signaling possible necrotizing fasciitis of the abdominal wall (Fig. 5). The left lower limb became ischaemic, swollen, cold and pulseless.

Fig. 5



Patient 2: Anterior abdominal wall lesion.

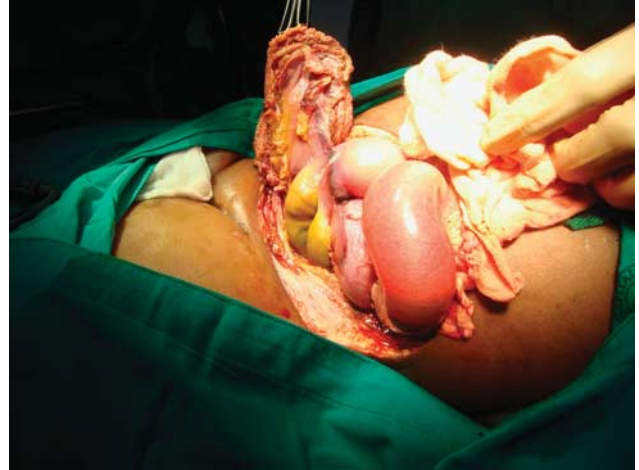The patient was pancytopenic, with a deranged liver and normal renal function. Blood culture had previously grown a vancomycin-resistant *Enterococcus faecalis* and a sensitive *Streptococcus oralis* for which he was receiving linezolid and meropenem. He was also managed on empirical fluconazole and was receiving granulocyte colony-stimulating factor and interferon.

At laparotomy, he was found to have extensive full-thickness necrosis of the left lower abdominal wall and necrotic segments of the small and the large bowel with extensive greyish discoloration of the surrounding tissue including the left ureter (Fig. 6). The left iliac vein and artery were thrombosed with extension into the femoral vessels. Extensive necrosectomy of the anterior abdominal wall, necrotic bowel resection and arterial and venous thrombectomy were performed with a negative-pressure dressing for the abdominal wall closure, and planned relook in 24–48 h after further resuscitation. On clinical suspicion of mucormycosis, the patient was commenced on liposomal amphotericin B pending tissue cultures and histology.

Postoperatively, the patient remained ventilated, suffered rapid progressive multiorgan failure and died within 48 h.

Histology sections of both cases showed extensive infarction as a result of mycotic thrombosis with a variable inflammatory response. Broad nonseptate fungal hyphae with 90° branching consistent with that seen in mucormycosis were observed plugging vessels and infiltrating through to the surrounding necrotic tissue (Fig. 4). The fungal organisms were eventually confirmed as *Rhizopus* spp. on one of the culture specimens from patient 1, but no fungal organisms were cultured from any

Fig. 6



Patient 2: Clinical appearance of the bowel and the abdominal wall at laparotomy.

of the tissue specimens submitted to microbiology for patient 2.

## Discussion

Mucormycosis is a fungal infection caused by moulds of the class *Zygomycetes*, order *Mucorales*, with *Rhizopus* being the most common pathogenic species. The other species known to cause infections include *Rhizomucor* spp., *Absidia corymbifera*, *Apophysomyces elegans*, *Cunninghamella bertholletiae*, *Mucor* spp. and *Saksenaea vasiformis* [1,2]. *Zygomycetes* are found commonly in organic matter and soil [3,4].

The fungus may gain entry through the nasopharynx by inhalation of spores, can be swallowed in contaminated food, fruits or vegetables, or invade through broken skin or mucosa [1,3]. Host susceptibility is dependent on the status of the immune defense. The exact mechanisms that play in the process of host colonization, fungal growth, virulence, invasion and dissemination are unclear. However, it is evident from histopathological assessment of affected tissues that the mucor invades vessels leading to thrombosis and tissue necrosis. Both of the reported cases had small-vessel and large-vessel involvement. The resulting anaerobic, high-CO<sub>2</sub> environment seems to stimulate further fungal growth, virulence and spread, while impairing phagocytic function [1,4]. The infarcted, necrotic tissue in patient 1 had a greyish hue with a dry velvety texture (Fig. 3).

Cases of mucor on wounds as well as other hospital-acquired sources of infection have been reported [5,6]. The infection can present as rhinocerebral, central nervous system, pulmonary, cutaneous and gastrointestinal, or can be disseminated. Cases of mucormycosis infection in healthy, immune-competent individuals are rare and tend to be focal [7]. The disease affects mostly immune-compromised hosts, and in this situation, is invasive in most cases [8–11].

Diagnosis is often difficult and delayed. Tissue and blood cultures take time and can be unrevealing, whereas results from swabs of the nasopharynx and tracheal

aspirates are difficult to interpret due to the ubiquitous nature of this fungus. In both cases, tissue fungal cultures at 45 days had no yield. The diagnosis was made on histology of the resected necrotic tissue. Urgent processing of histological specimens is therefore critical in suspected cases.

Disseminated mucormycosis is fatal in most cases [12]. Although it tends to occur in immune-compromised patients on chemotherapy or steroids, patients with diabetic ketoacidosis, transplant patients and patients in renal failure, only a few cases have been reported in paediatric and in paediatric HIV/AIDS patients. The underlying predisposition seems to be the loss of phagocytic function as demonstrated in neutropaenic patients after chemotherapy or immunosuppressive treatment after transplantation. It is relatively rare in HIV/AIDS patients, in whom the primary disorder is the loss of T-cell function [1]. In neonates, intestinal mucormycosis can mimic necrotizing enterocolitis [13].

Cases of paediatric patients with disseminated mucormycosis presenting with necrotizing fasciitis are uncommon [14,15]. This is possibly due to the failure to recognize it in a patient with a comorbidity, multiorgan dysfunction and what seems to be unabated necrotizing fasciitis.

Chen *et al.* [16] reported a case of fatal disseminated mucor coinfection with bacteria causing necrotizing fasciitis in a 71-year-old patient. A case of limb salvage in the setting of regional mucormycosis with necrotizing fasciitis has been reported in an adult patient after renal transplant with underlying diabetes [17]. Our second patient had associated limb ischaemia and subsequent infarction of the left lower limb secondary to thrombosis of the involved iliac vessels.

The key to treatment is early recognition, urgent histological confirmation and aggressive debridement combined with effective antifungal therapy and reversal of the underlying immunosuppression [12]. Radiological imaging as an adjunct to diagnosis is important in assessing regions that are not readily available to surgical exploration or clinical assessment [18,19].

These fungi are resistant to the azole group of antifungals, but sensitive to amphotericin B. However, empirical or prophylactic use of amphotericin B is precluded by its toxicity and, in some situations, cost. Liposomal amphotericin B is potentially less toxic and has better tissue penetration. There are reports of mucormycosis treatment with posaconazole and other newer agents [20,21]. Some recommend the use of posaconazole in empirical therapy or prophylaxis in select patients [22].

Experience with such cases raises a pertinent question: When does the hope for benefit from empiric but potentially toxic antifungal therapy and/or explorative surgery outweigh the potential risks? Particularly in a patient who is already in multiorgan dysfunction with high perioperative risk of morbidity and further deterioration of renal function from amphotericin B.

Empirical therapy in cases with a high clinical suggestion of mucormycosis is as valid as that for early biopsy of affected tissues and aggressive debridement. The patients presented here had rapid progression of disease and early mortality. Immunoglobulins and granulocyte colony-stimulating factor have also been used [23]. Mortality is high in noncontiguous organ/systemic involvement, particularly in the setting of extreme immunological failure. There are case reports of successful treatment of regional mucormycosis with a combination of posaconazole, antifungal wound packs and hyperbaric oxygen [24,25].

## Conclusion

The two cases reported illustrate the challenges in the early diagnosis and the poor outcome in paediatric patients with profound immunological failure and multi-organ mucormycosis.

Empiric therapy in suspected mucormycosis must be guided by clinical suspicion. Unfortunately, identifying early mucormycosis in a patient with multiple other problems that can explain the presentation is a clinical challenge. Cultures will take time and may not be reliable. Frozen section for histological confirmation is possible. Further studies on new, less toxic antifungal agents is essential.

The utility of a disease-reporting system including new modes of presentation in specific populations is essential in raising awareness among clinicians and researchers.

Consent for inclusion of clinical and photographic material in this manuscript was obtained from the legal guardians of both patients.

## Acknowledgements

### Conflicts of interest

There are no conflicts of interest.

## References

- 1 Ibrahim AS, Spellberg B, Walsh TJ, Kontoyiannis DP. Pathogenesis of mucormycosis. *Clin Infect Dis* 2012; **54** (Suppl 1):S16–S22.
- 2 Kwon-Chung KJ. Taxonomy of fungi causing mucormycosis and entomophthoromycosis (zygomycosis) and nomenclature of the disease: molecular mycologic perspectives. *Clin Infect Dis* 2012; **54** (Suppl 1): S8–S15.
- 3 Lewis RE, Kontoyiannis DP. Epidemiology and treatment of mucormycosis. *Future Microbiol* 2013; **8**:1163–1175.
- 4 Heitman J. Microbial pathogens in the fungal kingdom. *Fungal Biol Rev* 2011; **25**:48–60.
- 5 Shakoor S, Jabeen K, Idrees R, Jamil B, Irfan S, Zafar A. Necrotising fasciitis due to *Absidia corymbifera* in wounds dressed with non sterile bandages. *Int Wound J* 2011; **8**:651–655.
- 6 Lalayanni C, Baliakas P, Xochelli A, Apostolou C, Arabatzi M, Velegraki A, *et al.* Outbreak of cutaneous zygomycosis associated with the use of adhesive tape in haematology patients. *J Hosp Infect* 2012; **81**:213–215.
- 7 Jain D, Kumar Y, Vasishta RK, Rajesh L, Pattari SK, Chakrabarti A. Zygomycotic necrotizing fasciitis in immunocompetent patients: a series of 18 cases. *Mod Pathol* 2006; **19**:1221–1226.
- 8 Rüping MJGT, Heinz WJ, Kindo AJ, Rickerts V, Lass-Flörl C, Beisel C, *et al.* Forty-one recent cases of invasive zygomycosis from a global clinical registry. *J Antimicrob Chemother* 2010; **65**:296–302.
- 9 Wang S-M, Yang Y-J, Chen J-S, Lin H-C, Chi C-Y, Liu C-C. Invasive fungal infections in pediatric patients with leukemia: emphasis on pulmonary and dermatological manifestations. *Acta Paediatr Taiwan* 2005; **46**:149–155.
- 10 Pan AS, Srinath L. Mucormycosis in a patient with AIDS receiving systemic steroids. *J Am Osteopath Assoc* 2013; **113**:708–711.
- 11 Nagy-Agren SE, Chu P, Smith GJ, Waskin HA, Altice FL. Zygomycosis (mucormycosis) and HIV infection: report of three cases and review. *J Acquir Immune Defic Syndr Hum Retroviral* 1995; **10**:441–449.

- 12 Jouvot P, Hubert P, Blanche S, Nezelof C, Cloup M. Disseminated mucormycosis in pediatrics. *Arch Fr Pédiatr* 1991; **48**:29–30.
- 13 Diven SC, Angel CA, Hawkins HK, Rowen JL, Shattuck KE. Intestinal zygomycosis due to *Absidia corymbifera* mimicking necrotizing enterocolitis in a preterm neonate. *J Perinatol* 2004; **24**:794–796.
- 14 Telich-Tarriba JE, Pérez-Ortiz AC, Telich-Vidal J. Necrotizing fasciitis caused by cutaneous mucormycosis. A case report. *Cir Cir* 2012; **80**:462–465.
- 15 Koklu E, Akcakus M, Torun YA, Tulpar S, Tasdemir A. Primary gangrenous cutaneous mucormycosis of the scalp in a child: a case report. *Pediatr Emerg Care* 2008; **24**:102–104.
- 16 Chen CK, Wan SH, Kou SK. A rare cutaneous fungal infection complicating bacterial necrotising fasciitis. *Hong Kong Med J* 2008; **14**:314–316.
- 17 Harada AS, Lau W. Successful treatment and limb salvage of mucor necrotizing fasciitis after kidney transplantation with posaconazole. *Hawaii Med J* 2007; **66**:68–71.
- 18 Spellberg B, Ibrahim AS. Recent advances in the treatment of mucormycosis. *Curr Infect Dis Rep* 2010; **12**:423–429.
- 19 Pilmis B, Lanternier F, Lortholary O. Mucormycosis: therapeutic news. *Med Sci (Paris)* 2013; **29**:25–30.
- 20 Walsh TJ, Bloom BE, Kontoyiannis DP. Meeting the challenges of an emerging pathogen: the Henry Schueler 41&9 Foundation International Forum on Mucormycosis. *Clin Infect Dis* 2012; **54** (Suppl 1):S1–S4.
- 21 De Decker K, Van Poucke S, Wojciechowski M, Ieven M, Colpaert C, Vogelaers D, *et al.* Successful use of posaconazole in a pediatric case of fungal necrotizing fasciitis. *Pediatr Crit Care Med* 2006; **7**:482–485.
- 22 Ullmann AJ, Lipton JH, Vesole DH, Chandrasekar P, Langston A, Tarantolo SR, *et al.* Posaconazole or fluconazole for prophylaxis in severe graft-versus-host disease. *New Engl J Med* 2007; **356**:335–347.
- 23 Saoulidis S, Simitsopoulou M, Dalakiouridou M, Walsh TJ, Wheat LJ, Papaioannidou P, *et al.* Antifungal activity of posaconazole and granulocyte colony-stimulating factor in the treatment of disseminated zygomycosis (mucormycosis) in a neutropaenic murine model. *Mycoses* 2011; **54**:e486–e492.
- 24 Almannai M, Imran H, Estrada B, Siddiqui AH. Successful treatment of rhino-orbital mucormycosis with posaconazole and hyperbaric oxygen therapy. *Pediatr Hematol Oncol* 2013; **30**:184–186.
- 25 Serna JH, Wanger A, Dosekun AK. Successful treatment of mucormycosis peritonitis with liposomal amphotericin B in a patient on long-term peritoneal dialysis. *Am J Kidney Dis* 2003; **42**:E14–E17.