

# Trans-scrotal single-incision orchidopexy compared with conventional orchidopexy in palpable undescended testis in a Nigerian Tertiary Hospital

Ademola O. Talabi<sup>a</sup>, Oludayo A. Sowande<sup>a</sup>, Lofty-John C. Anyanwu<sup>b</sup> and Olusanya A. Adejuyigbe<sup>a</sup>

**Background** The standard method of treatment of palpable undescended testes is through inguinal mobilization and a scrotal sub-dartos pouch. Trans-scrotal single-incision orchidopexy may be a suitable alternative.

**Aim** The aim of this study was to assess as to how trans-scrotal orchidopexy compares with conventional orchidopexy in terms of the suitable placement of the testis in a dependent position in the scrotum and the surgical outcome.

**Patients and methods** Forty children with 42 palpable undescended testes were randomly allotted into the conventional and the trans-scrotal orchidopexy groups over an 18-month period. The age, the testicular position, the side involved, the length of the vas gained after isolation and the division of the processus vaginalis, as well as the placement of the testes in the sub-dartos pouch without tension, were recorded. Postoperative complications and the subjective score of the cosmetic appearance of the scars during follow-up for at least 6 months. Success was defined as suitable placement of the testes in the sub-dartos pouch during operation, no conversion of patients in the single-orchidopexy group to the conventional inguinal approach, no complications and excellent cosmetic appearance of scars.

**Results** The two study groups were well matched for age and testicular positions. About 22 (55%) patients had right-sided undescended testes and 16 (40%) had left-sided

undescended testes, and in two (5%) patients, it was bilateral. All testes were satisfactorily placed in the sub-dartos pouch at surgery. Testicular retraction was observed in one patient in the conventional group, but in two patients in the trans-scrotal group. All wounds healed satisfactorily without infection. The overall wound complication rate in the trans-scrotal and the conventional groups were 2/21 and 3/21, respectively. In terms of the cosmetic appearance of the scar, patients in the trans-scrotal group had excellent cosmetic appearance as the scars were less visible and hidden in the rugal fold compared with the conventional method.

**Conclusion** Trans-scrotal orchidopexy for palpable undescended testis is simple, safe and has a better cosmetic scar compared with the conventional approach. *Ann Pediatr Surg* 11:25–29 © 2015 Annals of Pediatric Surgery.

*Annals of Pediatric Surgery* 2015, 11:25–29

**Keywords:** conventional, orchidopexy, testis, trans-scrotal

<sup>a</sup>Department of Surgery, Obafemi Awolowo University Teaching Hospitals Complex, ILE-IFE, Osun State and <sup>b</sup>Department of Surgery, Ahmadu Bello University, Zaria, Nigeria

Correspondence to Ademola O. Talabi, MD, Department of Surgery, Obafemi Awolowo University Teaching Hospitals Complex, ILE-IFE, Osun State, Nigeria Tel: +234 0803 346 9206; e-mail: ademolatalabi1608@gmail.com

Received 17 June 2013 accepted 9 December 2014

## Introduction

Testicular maldescent is one of the most common urologic disorders affecting boys. The incidence ranges from 2 to 4% at birth in full-term boys to 30% in preterm birth, decreasing to 1% by 1 year of age [1–3].

The main modality of treatment is surgery, although some workers have tried hormonal manipulation with varying degrees of success [4,5].

The basic principles of orchidopexy were established in the later part of the 19th century. This consists of surgical mobilization of the testis on its vas and vessels without tension. Currently, there are at least 40 operative techniques and modifications in use [6–8], which may suggest that there is no agreed surgical approach to managing undescended testis. Traditionally, undescended testes have been managed using a technique that involves making two incisions: a groin incision with a varying degree of disruption of the inguinal canal and the retroperitoneum and a second scrotal incision to relocate the testis in a dependent scrotal position [9]. In 1989,

Bianchi and Squire [10] developed a trans-scrotal single-incision orchidopexy after the observation that the vascular pedicle of most undescended testes are long enough to reach the scrotum contradictory to earlier belief. They observed that the technique is simple and adequate for palpable testes, especially those distal to the inguinal canal with excellent cosmesis. Trans-scrotal orchidopexy has shown excellent anatomical and cosmetic results at 6 months of follow-up [9,11,12]. Up till now, there are few prospective studies comparing trans-scrotal orchidopexy with conventional orchidopexy for palpable undescended testis. The objective of this study was to compare the surgical outcome of successful placement of the testis in the scrotum, postoperative complications, cosmetic appearance of the scar and testicular location at follow-up using conventional and trans-scrotal orchidopexy.

## Patient and methods

This prospective study was carried out at the Paediatric Surgical Unit of Obafemi Awolowo University Teaching Hospitals Complex ILE-IFE over a period of 18 months

between October 2006 and March 2008. This study was approved by the ethical and research committee of the institution. Consecutive patients from 1 to 9 years of age with palpable undescended testes in the inguinal canal, the external ring and the suprascrotal region were included in the study. A total of 40 patients with a palpable undescended testis were recruited in the study.

Patients were screened for suitability by detailed history and clinical examination to confirm cases with palpable undescended testes. Patients suspected to have disorders of sexual differentiation, those whose parents were not willing, those with retractile testes and those with previous groin surgeries were excluded from the study.

After this, parents were informed adequately about the study and their consent was obtained. The possibility of conversion of a patient in the trans-scrotal group to the conventional method if necessary during operation was thoroughly explained to parents. Patients were simply randomized into two equal groups, the trans-scrotal and the conventional orchidopexy groups, by the closed-envelope ballot method (Lucky dip). The age, the testicular position, the side involved, the length of the vas gained after isolation and the division of the processus vaginalis, as well as suitable placement of the testes in the sub-dartos pouch without tension, were recorded.

#### Postoperative follow-up visit

Patients were followed up successfully for at least 6 months after surgery. Each patient was seen on the fourth and the seventh postoperative days, and subsequently, on the fourth, the eighth and the 12th weeks and 6 months after operation. During this period, each wound was reviewed for the presence of wound haematoma, scrotal oedema and wound infection. The scrotum was palpated on the seventh postoperative day and on the fourth, the eighth, the 12th and the 26th postoperative weeks to ascertain whether the testis was in place or had retracted, and its position was recorded in the clinical information sheet. The subjective cosmetic appearance of scars was assessed by the same surgeon, who was not blinded to the study, using a visual analogue scale to avoid interobserver error.

#### The modified visual analogue scale:

Invisible scar	Excellent (good)
Fairly visible scar	Fair
Grossly visible scar	Unacceptable

Data were analysed using Microsoft Excel and the Statistical Package for Social Sciences version 13 Chicago, Illinois, USA. Continuous variables were compared using the Student *t*-test, whereas categorical variables were compared using the  $\chi^2$ -test. A *P* value of less than 0.05 was considered as significant.

Success was defined as suitable placement of the testes in the sub-dartos pouch during operation, no conversion of patients in the single-orchidopexy group to the

conventional inguinal approach, no complications and excellent cosmetic appearance of scars.

#### The technique of trans-scrotal orchidopexy

The resting position of the testis and the degree to which it could be brought into the scrotum was confirmed under general anaesthesia to further confirm that they were undescended testes. During this manoeuvre, the most caudal position of the testis was noted and recorded. The position of the pubic tubercle was marked on the skin before commencement of the operation (Fig. 1).

The testis was then exposed through a curved high skin-crease scrotal incision and delivered through the wound (Fig. 2). The distance between the transverse plane through the pubic tubercle and a marked point on the testis (mid-point) as it laid free outside the scrotal incision was measured with a vernier caliper in centimetres. Fibres of the cremasteric muscle were incised, whereas the vas deferens and vessels were identified and preserved intact. The processus vaginalis was isolated and dissected free to the level of the preperitoneal fat, ligated and divided high as was conventional for routine herniotomy. With the testis lying free and without tension, a further measurement was taken between the mid-point of the testis and the pubic tubercle (Fig. 3). The extra length gained was measured in centimetres. An ipsilateral sub-dartos pouch was developed through the same incision and the testes was placed within it. To prevent reascent of the testis, the neck of the dartos pouch was pliated with one or two interrupted absorbable 3/0 vicryl sutures. The scrotal wound was closed with subcuticular 3/0 vicryl sutures (Fig. 4). The children were then mobilized after recovery from anaesthesia and allowed home as day cases without prophylactic antibiotic.

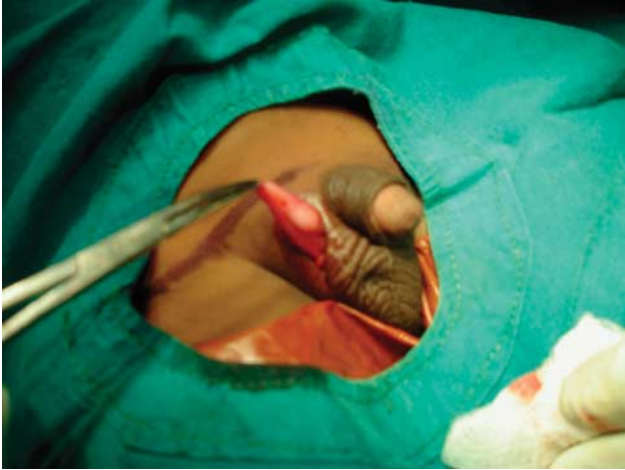
Conventional orchidopexy was performed by the existing method. After groin skin crease incision, the spermatic cord was delivered into the wound, and the cremasteric fibres were incised to reveal the vas deference, testicular vessels and the testis. The processus vaginalis was identified, dissected high up, ligated and divided. The

Fig. 1



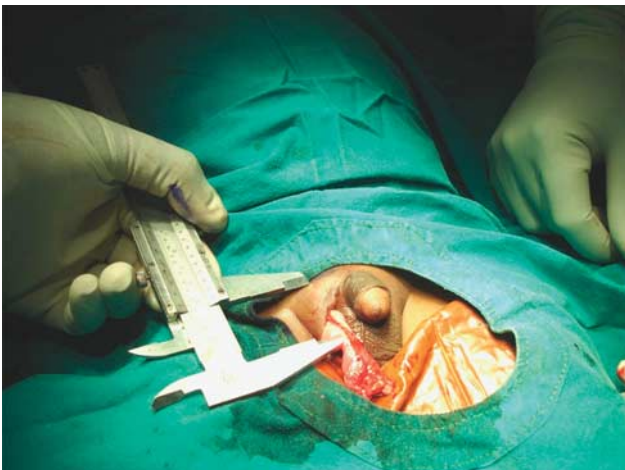High scrotal incision and testicular positions in relation to the transverse plane through the pubic tubercle.

Fig. 2



Delivery of the testis and the spermatic cord into the wound.

Fig. 3



Measuring the length of the vas deferens gained after dissection of the spermatic cord and high ligation of the processus vaginalis.

surgeon then made a scrotal incision along the scrotal crease and subsequently placed the testis in the sub-dartos pouch. During these procedures, all measurements were similar to that of the single-incision orchidopexy. To eliminate interobserver variability, all operations were carried out by a single surgeon (Talabi A.O.).

## Results

A total of 42 orchidopexies were performed in 40 patients. Patients' preoperative characteristics were well matched (Table 1).

About 38 (95%) patients had unilateral undescended testes: 22 (55%) patients had right-sided undescended testes and 16 (40%) had left-sided undescended testes; in 5% of the patients, it was bilateral.

All the palpable testes in the trans-scrotal group were placed successfully in the sub-dartos pouch without tension. There was no need for conversion to the

Fig. 4



Wound closure after fixation of the testis in the sub-dartos pouch through the same incision.

Table 1 Preoperative characteristics between both groups

Patients characteristics	Trans-scrotal	Traditional	<i>P</i> value
Age [mean (SD)] (years)	5.6 (2.4)	4.9 (2.4)	0.33
Age group [ <i>n</i> (%)] (years)			0.75
1–3	6 (30)	6 (30)	
4–6	6 (30)	8 (40)	
7–9	8 (40)	6 (30)	
Most caudal position [ <i>n</i> (%)]			0.75
Inguinal canal	1 (4.8)	2 (9.5)	
External inguinal ring	7 (33.3)	8 (38.1)	
Suprascrotal region	13 (61.9)	11 (52.4)	

conventional approach. Similarly, all testes in the conventional group were also placed successfully in the sub-dartos pouch. The testicular vessels were found to be long enough after isolation and division of the observed shortened processus vaginalis in all patients. There was no statistically significant difference in the length of the vas gained (Table 2).

All wounds healed well without infection. In the conventional orchidopexy group, transient wound haematoma and scrotal oedema were observed in two and one patients, respectively, on the fourth postoperative day visit, whereas in the trans-scrotal group, wound haematoma and scrotal oedema were found in one patient each.

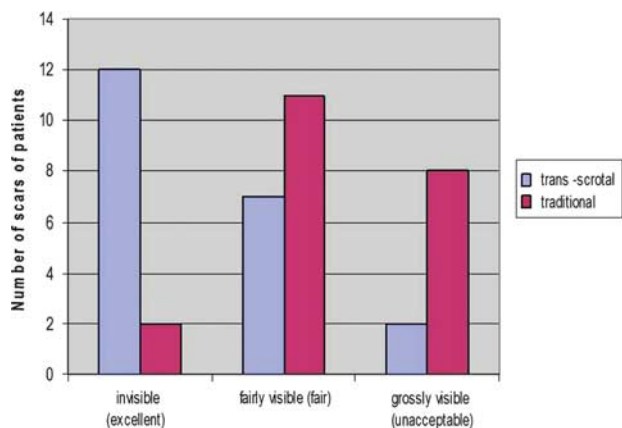
The overall wound complication rates in the trans-scrotal and the conventional orchidopexy groups were 2/21 and 3/21, respectively.

During the first 4 weeks of follow-up, all the testes maintained satisfactory scrotal positions. However, on the eighth week of visit, 19 (90.4%) testes in the trans-scrotal group maintained a satisfactory scrotal position, whereas two (9.6%) testes had retracted into the inguinal and suprascrotal position. In the conventional group, 20 (95.2%) testes maintained a satisfactory sub-dartos position, whereas only one (4.8%) testis retracted into the inguinal canal (Table 2). There was no statistically

Table 2 The postoperative outcome

	Trans-scrotal	Traditional	P value
Length of vas gained [mean (SD)] (cm)	2.63 (0.74) (1.8–4.0)	2.56 (0.47) (1.9–3.5)	0.71
Position of testes at eight week [n (%)]			
Sub-dartos pouch	19 (90.4)	20 (95.2)	0.549
Suprascrotal position	1 (4.8)	0 (0)	
Inguinal canal	1 (4.8)	1 (4.8)	

Fig. 5



Cosmetic appearance of the scar.

significant difference in the retraction rate between both groups ( $\chi^2 = 0.359$ ,  $P < 0.549$ ).

Similarly, during the third and the sixth months of follow-up, all testes had findings identical to their initial 8-week visit.

The scars at the surgical sites were less visible in most of the patients who had undergone trans-scrotal orchidopexy as the scars were hidden within the rugal folds with excellent cosmesis compared with the conventional group (Fig. 5) ( $\chi^2 = 11.6$ ,  $P = 0.003$ ).

## Discussion

The conventional method of managing an undescended testis has not changed much for all varieties of undescended testes including palpable testes lying distal to the inguinal canal [10]. The basic principles of this method involve making a groin incision to access the spermatic cord structures and protecting them in the early part of the operation before separation and high ligation of the processus vaginalis, and a second scrotal incision to place the testis in a dependent sub-dartos pouch without undue tension [9]. This approach is still being practiced with varying degrees of modifications including retroperitoneal mobilization of the testicular vessels such that a new and straighter course towards the scrotum allows additional testicular descent [6,13].

The approach is still very popular because of the general belief that undescended testes have a short vascular pedicle that prevents it from reaching the scrotum. However, the majority of the undescended testes are palpable distal to the inguinal canal. Furthermore, in the

paediatric age group, the inguinal canal is short, with the internal and the external rings almost superimposed on one another. This couple with the relative mobility of the skin in the inguinal region allows retraction of the skin incision, thereby enabling dissection through the scrotum without opening the inguinal canal. These facts led other workers to believe that single scrotal orchidopexy rather than two incisions may be adequate for orchidopexy in patients with a palpable, low-lying testis [8,10,11,14]. In 1989, Bianchi and Squire developed single-incision high scrotal orchidopexy (trans-scrotal) after observing that most palpable undescended testes were held by a shortened processus vaginalis. The technique has the advantage of less dissection and disruption of tissues and greater comfort for day-case children.

The most caudal position of a palpable undescended testis was noticed to be distal to the inguinal canal in this series, and it occurred in 92.9% of the patients. This observation is similar to that of Jawad [7] as well as Bianchi and Squire [10]. The mean length of vas gained after dissection of the spermatic cord and high ligation of the processus vaginalis was not significantly different between both study groups ( $P = 0.711$ ). In the trans-scrotal group, the range of vasal length gained was 1.8–4.0 cm, which compared favourably with the observation of Bianchi and Squire [10] (1.5–3.5 cm).

In a study of 120 orchidopexies for palpable undescended testes, Bianchi and Squire observed that the vascular pedicle of most palpable undescended testes were long enough, and that dissection and division of the shortened processus vaginalis and or hernia sac allowed tension-free placement of the testis in the sub-dartos pouch. In our study, we established similar findings. This finding is similar to that of Jawad [7], Bianchi and Squire [10] and Dayanc *et al.* [14]. This view-point confirmed the observation of most investigators on single-incision orchidopexy that the majority of the palpable undescended testes are held by shorter than normal processus vaginalis and that the vas and or vessels are long enough to allow adequate placement of the testis in the scrotum without undue tension [7,10,11].

Gökçora and colleagues [9,15] in a comparative study using conventional and single-incision orchidopexy were able to place most testes in a dependent position in the scrotum. The fewer conversions observed in their series were in individuals in the single-incision orchidopexy group whose testes were high up in the inguinal canal. In the present study, all testes in both study groups were placed successfully in the sub-dartos pouch, and there-

fore, there was no need for conversion. We attribute this success to the small sample size in our study as most of the testes were distal to the inguinal canal. A concern regarding this scrotal approach technique is the possibility of damaging the genitofemoral and the ilioinguinal nerves during dissection. Several workers have alluded to the fact that most palpable testes can be approached safely through a high scrotal incision with minimal tissue dissection and disruption of the inguinal canal. In addition, the relative mobility of the groin skin in the paediatric population allows direct visualization of the spermatic cord structures and nerves. However, there is a minimal chance of injuring the cuticular branches of the genitofemoral and the ilioinguinal nerves. Also, there is a controversy that the approach may not be feasible in older children as sufficient lengthening of the vas and testicular vessels may be difficult. Although other workers believe that the single-incision technique becomes less useful with increasing age of the patients at surgery, it consumes much time and as such is fraught with more complications. A literature review suggests that achieving adequate lengthening of the vas deference was dependent more on releasing the hernia sac and or processus vaginalis from the cord than on dissection around the spermatic vessels [9,10,15–17].

The available literature reports that wound complications after orchidopexy are rare. All wounds healed satisfactory without infection in our study. This was similar to the observation of Bianchi and Squire [10]. However, Gökçora *et al.* [18] observed a significantly higher wound infection rate with the traditional approach compared with the trans-scrotal approach ( $P < 0.05$ ). They attributed this difference to differences in the blood supply to the subcuticular tissues of the inguinoscrotal region. We observed a few cases of transient scrotal oedema, wound haematoma and less testicular reascent, which were comparable using both approaches, and there were no significant difference. This finding concurs with other reports [9,12]. The main advantage of single incision is its shortened operation time, lower postoperative pain, avoidance of an extra incision, and the fact that it is simple, safe and has excellent cosmesis [19]. The cosmetic appearance of scars was found to be much better using the trans-scrotal approach compared with the conventional method in our series. This was because most of the scars were invisible as they were hidden within the rugal folds. This finding was similar to that of Bianchi and Squire and many other workers [7–10,19].

This study had some limitations such as the small number of participants enrolled in the study. In addition, important variables such as pain assessment, duration of the operation and testicular atrophy during the long follow-up were not considered.

## Conclusion

Because of our observation in this study, we propose that orchidopexy for palpable testes, especially those distal to the inguinal canal, should commence with the single-incision scrotal approach, and that an additional groin incision and retroperitoneal vascular pedicle mobilization should be reserved for a few high testes that will not otherwise reach the scrotum. The technique is simple, safe and has a better cosmetic scar compared with the conventional approach.

## Acknowledgements

### Conflicts of interest

There are no conflicts of interest.

## References

- 1 Virtanen HE, Bjerknes R, Cortes D, Jørgensen N, Rajpert De Meyts E, Thorsson AV, *et al.* Cryptorchidism: classification, prevalence and long-term consequences. *Acta Paediatrica* 2007; **96**:611–616.
- 2 Berkowitz GS, Lapinski RH, Dolgin SE, Gazella JG, Bodian CA, Holzman IR. Prevalence and natural history of cryptorchidism. *Pediatrics* 1993; **92**: 44–49.
- 3 D'Cruz AJ, Das K. Undescended testes. *Indian J Pediatr* 2004; **71**: 1111–1115.
- 4 Henna MR, Del Nero RGM, Sampaio CZS, Atallah AN, Schettini ST, Castro AA, Garcia de Oliveira Soares B. Hormonal cryptorchidism therapy: systematic review with meta-analysis of randomized clinical trials. *Pediatr Surg Int* 2004; **20**:357–359.
- 5 Ong C, Hasthorpe S, Hutson JM. Germ cell development in the descended and cryptorchid testis and the effects of hormonal manipulation. *Pediatr Surg Int* 2005; **21**:240–254.
- 6 Saha SK. Cordopexy: a new approach to the undescended testis. *Br J Urol* 1978; **50**:39–42.
- 7 Jawad AJ. High scrotal orchidopexy for palpable maldescended testes. *Br J Urol* 1997; **80**:331–333.
- 8 Rajimwale A, Brant WO, Koyle MA. High scrotal (Bianchi) single-incision orchidopexy: a 'tailored' approach to the palpable undescended testis. *Pediatr Surg Int* 2004; **20**:618–622.
- 9 Na SW, Kim SO, Hwang EC, Oh KJ, Jeong IIS, Kang TW, *et al.* Single scrotal incision orchiopexy for children with palpable low-lying undescended testis: early outcome of a prospective randomized controlled study. *Korean J Urol* 2011; **52**:637–641.
- 10 Bianchi A, Squire BR. Transscrotal orchidopexy: orchidopexy revised. *Pediatr Surg Int* 1989; **4**:189–192.
- 11 Handa R, Kale R, Harjai M, Minocha A. Single scrotal incision orchiopexy for palpable undescended testis. *Asian J Surg* 2006; **29**:25–27.
- 12 Ramzan M, Sheikh AH, Qureshi MA, Zubair M, Majid F. Single incision trans scrotal versus standard inguino-scrotal orchidopexy in children with palpable undescended testis: our experience from April 2007 to April 2010. *Pak J Med Sci* 2012; **28**:827–829.
- 13 Omodare P, da Rocha-Afodu JT, Aina AO, Adeoba F. Surgery of the undescended testis. *West African J Med* 1976; **6**:20–29.
- 14 Dayanc M, Kibar Y, Irkilata HC, Demir E, Tahmaz L, Peker AF. Long-term outcome of scrotal incision orchiopexy for undescended testis. *Urology* 2007; **70**:786–788.
- 15 Gökçora IH, Yagmurlu A. A longitudinal follow-up using the high trans-scrotal approach for inguinal and scrotal abnormalities in boys. *Hernia* 2003; **7**:181–184.
- 16 Docimo SG. The results of surgical therapy for cryptorchidism: a literature review and analysis. *J Urol* 1995; **154**:1148–1152.
- 17 Lais A, Ferro F. Trans-scrotal approach for surgical correction of cryptorchidism and congenital anomalies of the processus vaginalis. *Eur Urol* 1996; **29**:235–239.
- 18 Gökçora IH, Yagmurlu A. A novel incision for groin pathologies in children: the low inguinal groove approach. *Hernia* 2003; **7**:146–149.
- 19 Gutiérrez Dueñas JM, Lorenzo G, Ardela Diaz E, Martín Pinto F, Domínguez Vallejo FJ. First results of the orchiopexy via scrotal approach. *Cir Pediatr* 2011; **24**:79–83.