

Giant juvenile xanthogranuloma of the tongue presenting from birth in a 1-month-old infant: a case report

Juju J. Kurian, Ahmed Kabeer, Deepak Samson Singh and John Mathai

Juvenile xanthogranuloma is a rare benign proliferative lesion of the non-Langerhans cell histiocytic group. Extracutaneous involvement is extremely rare. We present a case of a giant juvenile xanthogranuloma involving the tongue from birth. *Ann Pediatr Surg* 11:140–142 © 2015 Annals of Pediatric Surgery.

Annals of Pediatric Surgery 2015, 11:140–142

Keywords: extracutaneous involvement, giant, juvenile xanthogranuloma

Introduction

Juvenile xanthogranuloma is a rare benign proliferative lesion of the non-Langerhans cell histiocytic group. It usually presents as solitary or multiple cutaneous papulonodular lesions in the head and neck of an infant. Extracutaneous involvement is uncommon with involvement of the tongue being extremely rare. Lesions that are 20 mm or more in diameter are considered as giant.

We report a case of giant juvenile xanthogranuloma of the tongue in an infant, which was present from birth. To our knowledge, this is the first reported case in the English literature of a giant juvenile xanthogranuloma involving the tongue from birth.

A 1-month-old thriving boy was brought with complaints of a swelling involving the anterior tongue. The swelling was present from birth and had no much increase in size over the 1-month period. Examination revealed an $\sim 2 \times 2$ cm sessile lesion involving the anterior tongue, which had a smooth surface and was firm in consistency (Fig. 1). The rest of the head and neck examination was unremarkable.

The differentials considered were pyogenic granuloma, foreign body granuloma, eosinophilic granuloma, ectopic thyroid tissue and haemangioma. Thyroid function tests were normal, and an ultrasound of the neck revealed a normal thyroid. Doppler ultrasound ruled out a haemangioma.

A complete excision of the lesion was performed under general anaesthesia. Biopsy of the lesion showed a 2×2 cm well-circumscribed lesion composed predominantly of histiocytes interspersed with lymphocytes, eosinophils, Touton giant cells and proliferating capillaries. There were areas of extravasated red blood cells suggestive of haemorrhage. Immunohistochemistry showed the histiocytes to be positive for CD68 and CD31 and negative for CD34 and CD1a (Figs 2–5). On the basis of the above findings, a diagnosis of juvenile xanthogranuloma was made.

The postoperative period was uneventful with no dyspnoea or dysphagia. At 6-month follow-up, the child is well without any evidence of recurrent disease.

Department of Paediatric Surgery, Christian Medical College and Hospital, Vellore, Tamil Nadu, India

Correspondence to Juju J. Kurian, MBBS, MS, MRCS, MCh, Department of Paediatric Surgery, Christian Medical College and Hospital, 632004 Vellore, Tamil Nadu, India

Tel: +91 416 2283369; e-mail: jujujacobkurian@gmail.com

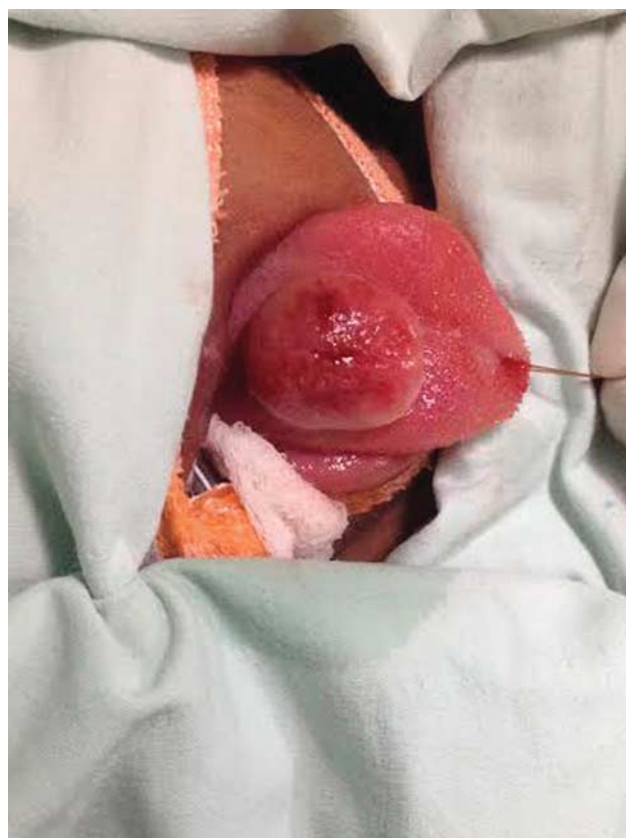Received 16 September 2014 accepted 19 December 2014

Discussion

Juvenile xanthogranuloma is a rare benign histiocytic disorder of the non-Langerhans cell group. It was first reported by Adamson [1] who named it as congenital xanthoma multiplex. The term juvenile xanthogranuloma was coined by Senear in 1936.

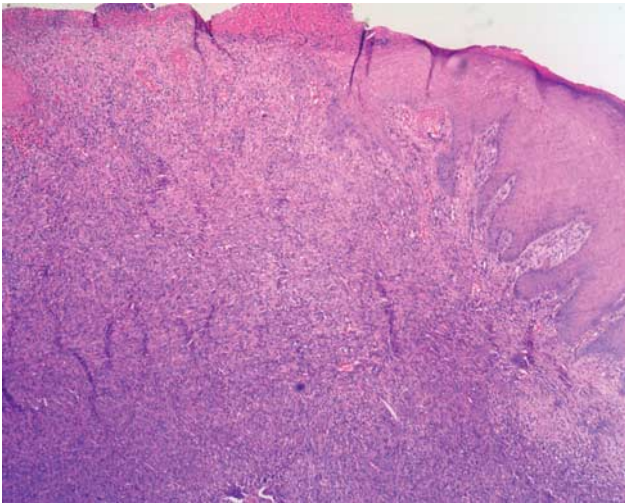
Juvenile xanthogranuloma has bimodal peaks in infancy and in the second to third decade of life. It has a slight

Fig. 1



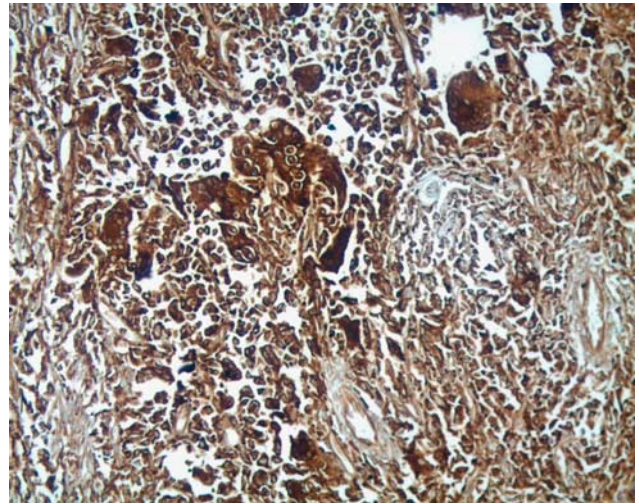
Pre operative picture of the tongue lesion.

Fig. 2



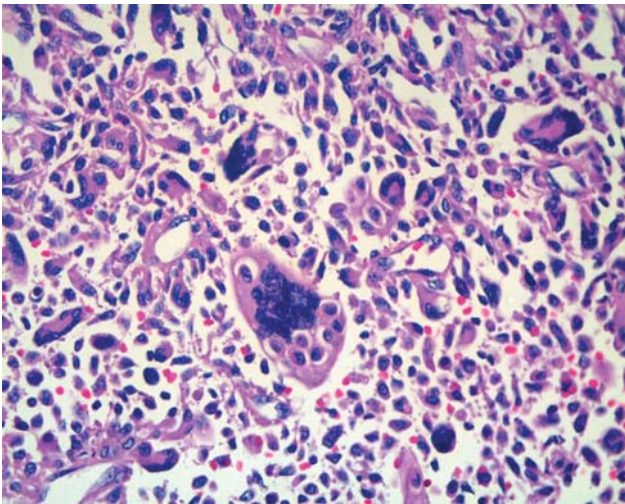
HPE examination of the tongue lesion showing sheets of histiocytes and inflammatory cells.

Fig. 4



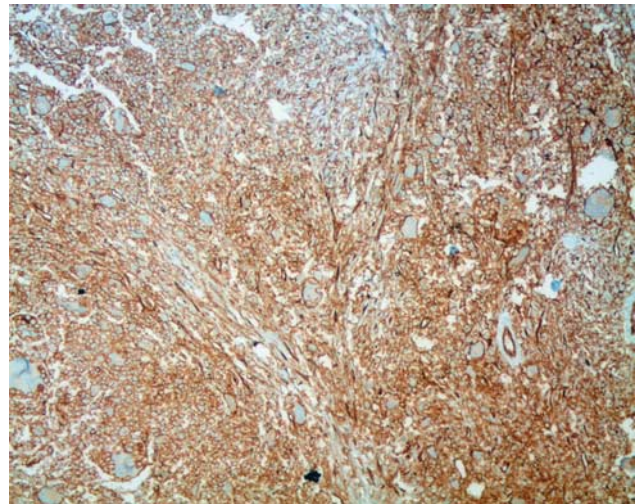
Immunohistochemistry showing CD68 positive histiocytes.

Fig. 3



HPE examination showing Touton like giant cells.

Fig. 5



Immunohistochemistry showing CD31 positive histiocytes.

male preponderance with a male-to-female ratio of 1–4:1.

Cutaneous juvenile xanthogranuloma starts as firm yellow brown to red papular or nodular lesions involving the head, neck or trunk. It progressively increases in size over a period of time and later undergoes spontaneous regression.

Extracutaneous lesions are rare with eye being the most common site. Other extracutaneous sites are the lung, pericardium, bone, gastrointestinal tract, genitourinary tract, paranasal sinuses, salivary glands, pharynx, larynx and the oral cavity [2]. Spontaneous regression is not seen in the extracutaneous variant.

Clinically, lesions are classified into papular, nodular and macronodular or giant depending on the diameter of the lesion. Lesions that are 20 mm or more in diameter as in our case are referred to as giant lesions [3].

In our case, the differentials included were pyogenic granuloma, foreign body granuloma, eosinophilic granuloma, ectopic thyroid tissue and haemangioma. Ectopic thyroid and haemangioma were ruled out with the help of ultrasound, whereas differentiating between the others required histological input. The differential diagnosis of the cutaneous variant includes Langerhans cell histiocytosis, fibrous histiocytoma, xanthoma and reticulohistiocytoma.

Treatment in the form of surgery, radiotherapy, chemotherapy or pharmacotherapy is required in extracutaneous juvenile xanthogranuloma, as spontaneous regression does not occur [4].

Microscopically, juvenile xanthogranuloma is characterized by a dense dermal infiltrate of lymphocytes, histiocytes, giant

cells, eosinophils and neutrophils, which may extend into subcutis. The histiocytes are well differentiated and usually contain lipid. Touton giant cells, which are formed by a wreath-like arrangement of histiocytes, are the hallmark of juvenile xanthogranuloma. Immunohistochemical stains are positive for CD45, a marker for haematopoietic cells, and CD68, a macrophage-associated antigen [5].

Conclusion

Extracutaneous juvenile xanthogranuloma is highly uncommon, with juvenile xanthogranuloma of the tongue being extremely rare. This is the first reported case in the English literature of a giant juvenile xanthogranuloma of the tongue that has been present from birth.

Acknowledgements

Conflicts of interest

There are no conflicts of interest.

References

- 1 James WD. A case of congenital xanthoma multiplex. *Br Med J* 1894; **2**:805.
- 2 Satow SJ, Zee S, Dawson KH, Gown AM, Oda D, Worthington P. Juvenile xanthogranuloma of the tongue. *J Am Acad Dermatol* 1995; **33** (Pt 2): 376–379.
- 3 Shapiro NL, Malis DJ, Charon CC, Billman GF, Kearns DB. Giant juvenile xanthogranuloma of the tongue. *Am J Otolaryngol* 1999; **20**:241–244.
- 4 Baik FM, Andeen NK, Schmechel SC, Futran ND. A large juvenile xanthogranuloma within the tongue. *Otolaryngol Head Neck Surg* 2014; **150**:332–333.
- 5 Tanyeri H, Weisenberg E, Friedman M. Juvenile xanthogranuloma of the tongue. *Otolaryngol Head Neck Surg* 2000; **123**:641–642.