

Giant omental lipoma: report of a case with review of the literature

Saurabh Garge, Prema Menon and Katragadda Laxmi Narasimha Rao

Omental lipoma is an extremely rare abdominal tumor that, despite its large size, often remains asymptomatic. A giant lipoma arising from the greater omentum in a 21-month-old girl is reported. The mass was excised completely and the patient is doing well at the 12-month follow-up, with no recurrence. Nontender lobulated mobile mass, location, and uniformly low attenuation on computed tomography were diagnostic. *Ann Pediatr Surg* 10:22–24 © 2014 Annals of Pediatric Surgery.

Annals of Pediatric Surgery 2014, 10:22–24

Keywords: abdominal tumor, giant lipoma, omentum

Department of Pediatric Surgery, PGIMER, Chandigarh, India

Correspondence to Saurabh Garge, MS, MCh, Department of Pediatric Surgery, APC-3A, PGIMER, 160012 Chandigarh, India
Tel: +91 987 869 1012; fax: +91 1722755642;
e-mail: saurabhgarge8@gmail.com

Received 15 November 2012 accepted 26 October 2013

Introduction

Lipoma of the greater omentum is an extremely rare benign abdominal childhood tumor, with only nine previous reports in the literature [1–9]. We report a giant omental lipoma in a 21-month-old girl that was completely excised. This also involved resection of a part of the spleen.

Case report

A 21-month-old girl weighing 12 kg presented with a history of progressive, painless abdominal distension for the past 2 months. A nontender, firm, lobulated mass occupying most of the left half of the abdomen and also crossing the midline was palpable. The fingers could not be insinuated between the left costal margin and the mass. The mass had side-to-side mobility and was bimanually palpable. There was a 3 × 2 cm café au lait patch over the swelling. A plain radiograph of the abdomen showed a homogenous ground-glass appearance on the left side of the abdomen with no calcification. Ultrasonograph (USG) suggested a large retroperitoneal noncystic mass displacing the left kidney posteroinferiorly. Serum α fetoprotein level was 1.9 ng/ml (< 5 ng/ml normal value). Contrast-enhanced computed tomography (CT) scan of the abdomen indicated a large well-defined intraperitoneal lesion with a predominant fat component (–80 to 100 HU) with multiple septa within (Fig. 1). Laterally, it abutted the abdominal wall and posterosuperiorly it was related to the pancreas. The splenic vein was compressed by the mass and it had displaced the superior mesenteric vessels to the right. There was no retroperitoneal lymphadenopathy or ascites. The absence of calcification on CT, normal α fetoprotein, and presence of a normal kidney and adrenals negated the diagnosis of teratoma, hepatoblastoma, nephroblastoma, and a cystic neuroblastoma. Thus, other tumor markers were not measured. A provisional diagnosis of omental lipoma was made on the basis of the characteristic fat attenuation on CT. Biopsy was not performed because the mobile, well-defined nature of the mass indicated a benign resectable lesion. At laparotomy, a lobulated, yellowish tumor measuring 20 × 14 × 9 cm arising from the greater omentum and occupying the intraperitoneal compartment as

well as the lesser sac was found (Fig. 2). It was also attached to the tip of the lower pole of the spleen, which had to be excised. The tumor weighing 2 kg was removed *in toto*. Histopathological examination showed a well-encapsulated tumor composed of mature adipocytes. There were no atypical lipoblasts, increased vascularity, or myxoid changes.

The patient had an uneventful recovery and was discharged from the hospital on the fifth postoperative day. She remains asymptomatic at the 12-month follow-up, with no evidence of recurrence on follow-up USG.

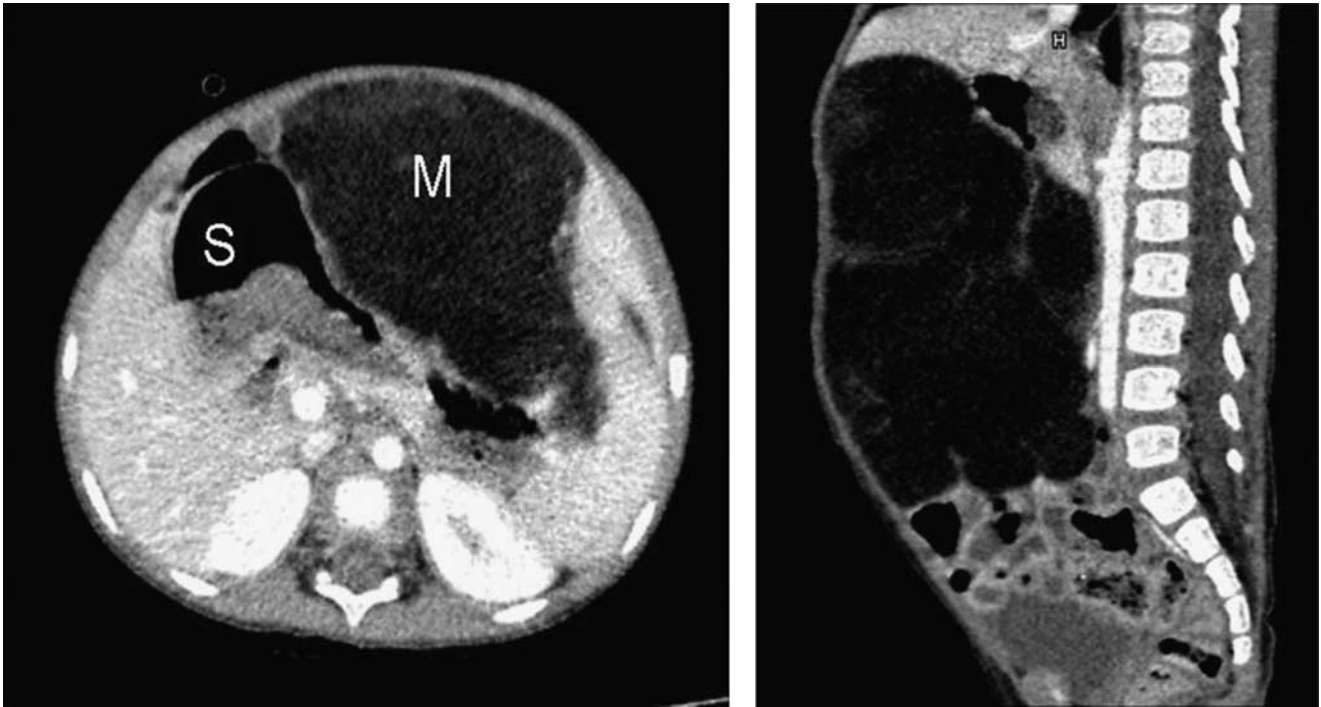
Discussion

Intraperitoneal lipomas are rare in childhood. Only seven cases have been reported so far arising from the greater omentum [1–7]. When cases of lipoblastomas are added, the tally comes to about nine cases [7–9]. These presented from the age of 9 months to 13 years [1–9] (Table 1). No sex predilection has been noted so far. There is gradual abdominal distension or a palpable lump [1,4–9]. Early satiety, vomiting, and abdominal pain owing to pressure effects on surrounding structures or an emergent presentation because of torsion or partial intestinal obstruction have been reported [2,3,9,12].

The differential diagnosis includes teratoma, lymphangioma, lymphoma, alimentary tract duplications, and neuroblastoma. Lipomas are homogeneous, highly echogenic, and encapsulated on USG. A lymphoma is usually hypoechoic and a neuroblastoma is often highly echogenic. Another close differential is lipoblastoma, which appears as a well-defined hypoechoic myxoid mass embedded within highly echogenic fat [13]. Identification of fat with CT is on the basis of an attenuation of less than ~20 HU. Other lesions with predominant macroscopic fat include teratoma, myelolipoma, angiolipoma, liposarcoma, lipoma, epiploic appendagitis, and omental infarction [11].

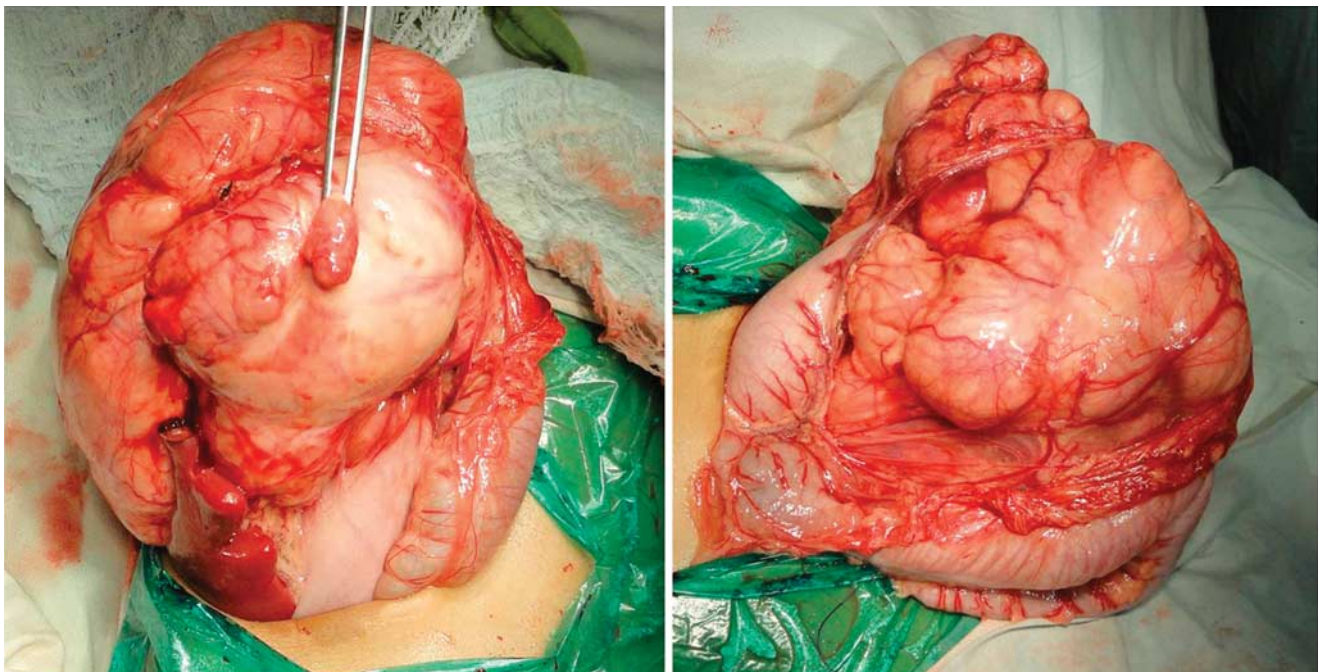
The histology in lipoma will show lobules of mature adipocytes, whereas in lipoblastoma, the cells will range from immature lipoblasts to mature adipocytes and the cells may be separated by fibrous septa [10]. The absence of calcification on CT, normal α fetoprotein, and presence

Fig. 1



Contrast-enhanced computed tomography scan: axial and left parasagittal images show a fat attenuation mass (M) anterior to the stomach (S).

Fig. 2



Intraoperative image taken from the head end showing attachment of mass to spleen, greater curvature of the stomach, and transverse colon from left to right.

of a normal kidney and adrenals negated the diagnosis of teratoma, hepatoblastoma, nephroblastoma, and a cystic neuroblastoma [1–9].

The recurrence rate for any lipoma after local excision is less than 5% [9]. Incomplete excision and lipoblastomatosis are associated with increased chances of recurrence,

Table 1 Review of literature

References	Age/sex	Weight of tumor	Size of tumor	Pathology	Duration	Symptoms	Follow-up
Cascini V <i>et al.</i> [9]	19 months/M	1185 g (12% of body weight)	–	Lipoblastoma	Since birth	Abdominal distension, failure to thrive	4 years
Abubakar <i>et al.</i> [7]	13 years/F	12.3 kg (30% of body weight)	34 × 24 × 22 cm	Lipoma	9 years	Asymptomatic abdominal lump, early satiety	4 months
Srinivasan <i>et al.</i> [6]	9 months/not mentioned	1.5 kg	Not mentioned	Lipoma	3 months	Abdominal lump, diarrhea	Not mentioned
Méndez-Gallart R <i>et al.</i> [8]	10 months/F	1480 g (20% of body weight)	17 × 12 × 16 cm	Lipoblastoma	6 months	Asymptomatic abdominal lump	2 years
Luo <i>et al.</i> [1]	11 months/M	1.82 kg	12 × 15 × 21 cm	Lipoma	6 months	Abdominal lump	1 year
Barauskas <i>et al.</i> [3]	8 years/F	Not mentioned	10 × 11 × 8 cm	Lipoma	Acute	Abdominal pain, fever, torsion of lipoma	Not mentioned
Joulak <i>et al.</i> [5]	3 years/F	Not mentioned	12 × 7 × 7 cm	Lipoma	Not mentioned	Abdominal lump	Not mentioned
Prando <i>et al.</i> [13]	1 year/F	Not mentioned	13 × 10 × 8 cm	Lipoblastoma	Not mentioned	Abdominal lump	Not mentioned
Haller JO [4]	3 years/F	Not mentioned	8 × 4 × 5 cm	Lipoma	Not mentioned	Abdominal lump	Not mentioned
This study	1 year/F	2.0 kg	11 × 11 × 13 cm	Lipoma	2 months	Abdominal lump, early satiety	1 year

about 14–20% [8]. Despite its rarity, the diagnosis of omental lipoma can be made preoperatively by a careful clinical examination and appraisal of the contrast-enhanced CT scan.

Acknowledgements

Conflicts of interest

There are no conflicts of interest.

References

- Luo X, Gao W, Zhan J. Giant omental lipoma in children. *J Pediatr Surg* 2005; **40**:734–736.
- Giubilei D, Cicia S, Nardis P. Lipoma of the omentum in a child. *Radiology* 1980; **137**:357–358.
- Barauskas V, Malcius D, Jazdauskiene V. Lipoma of the greater omentum in a child. *Medicina (Kaunas)* 2004; **40**:860–863.
- Haller JO, Schneider M, Kasner EG. Sonographic evaluation of mesenteric and omental masses in children. *Am J Roentgenol* 1978; **130**:269–274.
- Joulak M, Houas F, Bellagha I, Ben Salah S, Ben Becher S. Radiologic case of the month. Lipoma of the omentum. *Arch Pediatr* 1998; **5**:669–670.
- Srinivasan KG, Gaikwad A, Ritesh K. Giant omental and mesenteric lipoma in an infant. *Afr J Paediatr Surg* 2009; **6**:68–69.
- Abubakar AM, Mayun AA, Pindiga UH, Chinda JY, Adamu SA. Giant omental lipoma in a 13-year-old adolescent girl. *J Pediatr Surg* 2009; **44**:2230–2232.
- Mendez-Gallart R, Estevez-Martinez A, Baustista-Cassasnovas J. Giant omental lipoblastoma in a 10 month old infant composing 20% of total body weight. *J Pediatr Surg* 2007; **42**:1149–1152.
- Cascini V, Lisi G, Lauriti G. Giant abdomino-pelvic adipose tumors of childhood. *Pediatr Surg Int* 2012; **28**:89–93.
- Tang XB, Zhang T, Bai YZ, Wang WL. Giant mesenteric lipoblastoma in a 4-year old child. *J Pediatr Surg* 2009; **44**:859–861.
- Pereira JM, Sirlin CB, Pinto PS, Casola G. CT and MR imaging of extrahepatic fatty masses of the abdomen and pelvis: techniques, diagnosis, differential diagnosis, and pitfalls. *Radiographics* 2005; **25**:69–85.
- Beattie GC, Irwin ST. Torsion of an omental lipoma presenting as an emergency. *Int J Clin Pract Suppl* 2005; **147**:130–131.
- Prando A, Wallace S, Marins JL, Pereira RM, de Oliveira ER, Alvarenga M. Sonographic features of benign intraperitoneal lipomatous tumors in children – report of 4 cases. *Pediatr Radiol* 1990; **20**:571–574.