

# Haemorrhagic pseudocyst of the pancreatic tail causing acute abdominal pain in a 12-year-old girl

Rolf P. Dahmen<sup>a,c</sup>, Gerhard Stuhldreier<sup>b</sup>, Hartmut Bindewald<sup>c</sup> and Malte Weinrich<sup>a,c</sup>

Pancreatic disorders are a relatively uncommon event in children, particularly the development of pancreatic pseudocysts. The most common cause for the development of such pseudocysts is blunt abdominal trauma with injury of the pancreatic parenchyma. Further aetiologies include congenital anomalies of the pancreatic duct such as pancreatic divisum, hereditary or idiopathic pancreatitis. Various treatment options for pancreatic pseudocysts including internal or external drainage have been described. We describe the case of a 12-year-old girl with acute abdominal pain and a left-sided retroperitoneal tumour. She underwent laparotomy to identify the aetiology of her severe abdominal pain. A haemorrhagic pancreatic pseudocyst was identified as the underlying pathology. Internal drainage by pseudocyst jejunostomy was performed. The postoperative course was uneventful.

## Introduction

The acute abdomen in childhood has various aetiologies and represents a leading cause of hospitalization of children [1]. Most relevant in the differential diagnosis are gastroenteritis, acute appendicitis, mesenterial lymphangitis, intussusception, Crohn's disease, ovarian cysts and urogenital disorders.

Childhood tumours are rare, with an incidence of 14 of 1 000 000 children under the age of 15 years [2]. When a retroperitoneal mass is found, neuroblastomas, nephroblastomas, soft tissue sarcomas and pancreatic tumours have to be considered [3].

## Case report

A 12-year-old girl presented to the emergency department with progressive abdominal pain since the previous day. She denied nausea, vomiting and diarrhoea. She complained of intermittent fever up to 38.5°C and denied any previous episodes of significant abdominal pain. Physical examination indicated tenderness in the left mid-abdomen without evidence of peritonitis. Laboratory results showed elevated inflammatory markers (C-reactive protein 135 mg/l) and normal pancreatic enzymes. Ultrasound showed a heterogeneous round mass ventral of the left kidney ~5 cm in diameter (Fig. 1a and b). The decision was made to manage the patient surgically because of her progressive symptoms as well as the retroperitoneal mass of unknown aetiology. No advanced preoperative diagnostics using MRI or computed tomography were performed in order to save time and avoid radiation.

Under general anaesthesia, an upper midline laparotomy was performed. Dorsal to the left colonic flexure and ventral to the left kidney, a fluctuant mass ~8 cm in diameter was palpable. The colon was displaced ventromedially by this mass. Further exploration of the peritoneal cavity did not

The underlying aetiology of the pseudocyst remains unclear. As there was no previous history of pancreatitis, unrecognized blunt trauma was the most likely cause. *Ann Pediatr Surg* 10:17–19 © 2014 Annals of Pediatric Surgery.

*Annals of Pediatric Surgery* 2014, 10:17–19

**Keywords:** childhood, haemorrhage, pancreatic pseudocyst, retroperitoneal tumour

Departments of <sup>a</sup>General, Thoracic, Vascular and Transplantation Surgery, <sup>b</sup>Pediatric Surgery, University Hospital Rostock, Rostock and <sup>c</sup>Department of General, Visceral and Vascular Surgery, Hospital Worms, Worms, Germany

Correspondence to Rolf P. Dahmen, MD, Department of General, Thoracic, Vascular and Transplantation Surgery, University Hospital Rostock, Schillingallee 35, D-18057 Rostock, Germany  
Tel: +49 381 494 6001; fax: +49 381 494 6002;  
e-mail: rolf.dahmen@med.uni-rostock.de

Received 13 February 2013 accepted 24 August 2013

indicate any other abnormalities. The left colonic flexure was mobilized in the mediocaudal direction. The cystic mass was identified as originating from the pancreatic tail. The rest of the pancreas was soft without any abnormal findings.

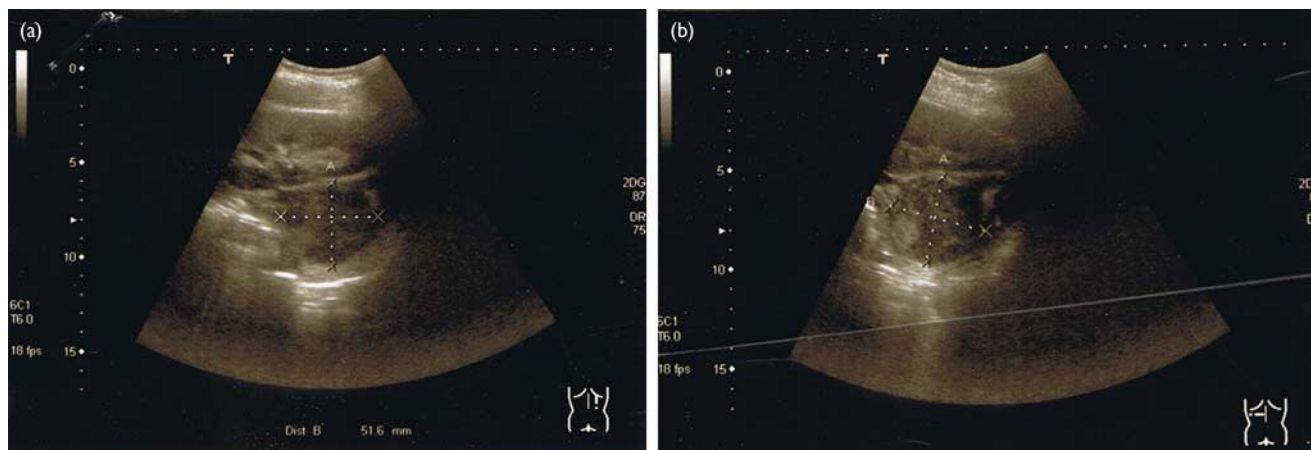
Because of its location at the lower edge of the pancreatic tail, the suspected pseudocyst was drained internally by cystojejunostomy with Roux-en-Y reconstruction. To achieve this, a loop of jejunum was moved in a transmesocolic manner into the vicinity of the pseudocyst (terminolateral jejunojejunostomy and laterolateral pseudocyst jejunostomy). Inspection of the interior of the mass showed cloudy haemorrhagic fluid. A part of the excised wall of the cystic mass was sent for histopathologic analysis. Pathology showed a pancreatic pseudocyst with haemorrhagic residues and marginal chronic inflammation (Figs 2 and 3). Microbiological analysis excluded infection. The postoperative course was uneventful.

At her 6-month postoperative follow-up, the patient was well, with no further pain. An ultrasound of the pancreas was normal and pancreatic enzymes as well as inflammatory markers were within the normal range. A hereditary pancreatitis was excluded by genetic analysis.

## Discussion

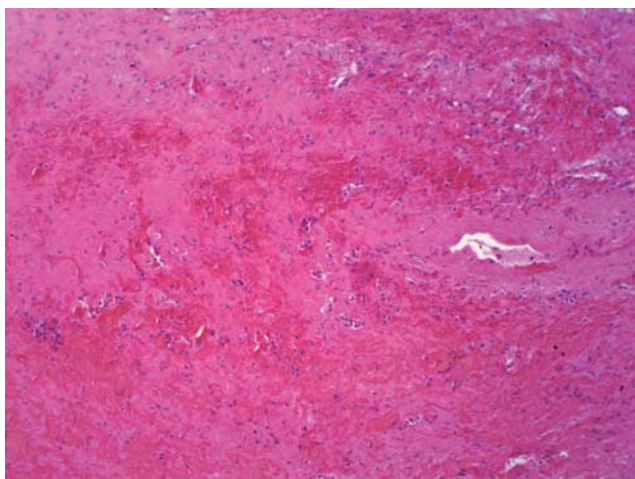
Pancreatic disease is relatively uncommon in childhood. The most frequent aetiologies are trauma, acute pancreatitis, multisystem disease, drugs, infections and congenital anomalies of the pancreaticobiliary system [4]. In 60–70% of paediatric pancreatic pseudocysts, there is an associated previous blunt abdominal trauma leading to direct injury to the pancreatic parenchyma, followed by pancreatitis with the development of a (pseudo)cyst [3].

Fig. 1



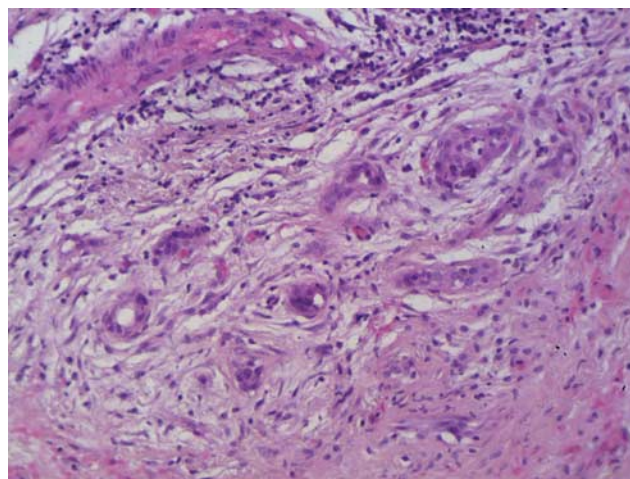
(a and b) Ultrasound images showing a heterogeneous mass ventral of the left kidney ~5 cm in diameter.

Fig. 2



HE photomicrograph with a magnification  $\times 100$  indicating haemorrhagic residues within connective tissue of the pancreatic pseudocyst. HE, haematoxylin and eosin.

Fig. 3



HE photomicrograph with a magnification  $\times 200$  showing surrounding residual pancreatic glands and periductal fibrosis within the capsule of the pseudocyst. HE, haematoxylin and eosin.

Our patient never had symptoms typical of pancreatitis before admission to our hospital. Pancreatic enzymes on admission were within the normal range. Furthermore, upon surgical exploration, the girl's pancreas had no additional pathological findings. Thus, it appears that acute or chronic pancreatitis can be excluded as the aetiology of the pseudocyst. In addition, the existence of hereditary pancreatitis was excluded by genetic essays [5]. Because no abdominal trauma was recalled by the patient or family, the aetiology of the pancreatic pseudocyst in this case remains unclear but is suspected to be post-traumatic.

The haemorrhagic content of the pancreatic pseudocyst was noteworthy. We assume that the pseudocyst emerged post-traumatically in the past but the patient's progressive abdominal pain resulted from acute bleeding into the cyst and the resulting dilatation of its capsule. In adrenal pseudocysts, the occurrence of pain does not seem to be related to the size of the cyst itself because of its chronic and slow growth [6].

A pancreatic pseudocyst is unlikely to resolve spontaneously if it persists for more than 6 weeks, chronic pancreatitis is evident, there is a pancreatic duct anomaly (except for a communication with the pseudocyst) or the pseudocyst is surrounded by a thick wall [7]. Appropriate treatment can include both medical and surgical interventions [8]. Pancreatic pseudocysts less than 5 cm in diameter that arise after acute pancreatitis can often be managed conservatively by reducing pancreatic stimulation and providing an opportunity for spontaneous resolution. This necessitates nasogastric decompression, total bowel rest and parenteral nutrition [9]. Pancreatic pseudocysts larger than 5 cm in diameter or thicker-walled pseudocysts in chronic pancreatitis require treatment by external or internal drainage because of the lack of resolution and an increased risk for spontaneous rupture [10].

External drainage is recommended for infected immature cysts and for ruptured cysts [8], and is generally performed percutaneously, avoiding the wait for pseudocyst

wall maturation necessary for an operation [11]. Internal drainage is achieved either endoscopically by transmural (cystogastrostomy, cystoduodenostomy) or transpapillary drainage [12] or by open (cystogastrostomy, cystoduodenostomy, cystojejunostomy) or laparoscopic (cystogastrostomy, cystojejunostomy) drainage [13]. The surgical approach chosen is determined by the anatomic location of the pseudocyst, previous abdominal surgery and the patient's comorbidities. Long-term outcomes of laparoscopic versus open surgery are not yet available but laparoscopic treatment seems to be associated with a lower complication rate and a good primary outcome [14]. Successful laparoscopic drainage of a pancreatic pseudocyst in a child was described recently [15]. Long-term recurrence rates and the risk of missed malignancy after endoscopic/laparoscopic procedures remain unclear [16].

In the present case, we decided to operate on the basis of the patient's clinical symptoms and an identifiable mass on ultrasound. Preoperatively, there was no evidence of pancreatic disease. The decision for immediate internal drainage by a pseudocyst jejunostomy was made intraoperatively. Intracystic bleeding rather than the size of the pseudocyst led to the progressive pain in our patient. Complicated retroperitoneal masses such as pancreatic pseudocysts make up part of the differential diagnosis in acute abdominal pain in childhood.

## Acknowledgements

### Conflicts of interest

There are no conflicts of interest.

## References

- Guthery SL, Hutchings C, Dean JM, Hoff C. National estimates of hospital utilization by children with gastrointestinal disorders: analysis of the 1997 kids' inpatient database. *J Pediatr* 2004; **144**:589–594.
- Mulrooney DA, Neglia JP, Hudson MM. Caring for adult survivors of childhood cancer. *Curr Treat Options Oncol* 2008; **9**:51–66.
- Cooney DR, Crosfeld JL. Operative management of pancreatic pseudocysts in infants and children: a review of 75 cases. *Ann Surg* 1975; **182**:590–596.
- Nydegger A, Couper RT, Oliver MR. Childhood pancreatitis. *J Gastroenterol Hepatol* 2006; **21**:499–509.
- Ellis I, Lerch MM, Whitcomb DC. Genetic testing for hereditary pancreatitis: guidelines for indications, counselling, consent and privacy issues. *Pancreatol* 2001; **1**:405–415.
- Medeiros LJ, Lewandrowski KB, Vickery AL Jr. Adrenal pseudocyst: a clinical and pathologic study of eight cases. *Hum Pathol* 1989; **20**:660–665.
- Warshaw AL, Rattner DW. Timing of surgical drainage for pancreatic pseudocyst. Clinical and chemical criteria. *Ann Surg* 1985; **202**:720–724.
- Aghdassi A, Mayerle J, Kraft M, Sielenkämper AW, Heidecke C, Lerch MM. Diagnosis and treatment of pancreatic pseudocysts in chronic pancreatitis. *Pancreas* 2008; **36**:105–112.
- Grant JP, James S, Grabowski V, Trexler KM. Total parenteral nutrition in pancreatic disease. *Ann Surg* 1984; **200**:627–631.
- Ford EG, Hardin WD Jr, Mahour GH, Woolley MM. Pseudocysts of the pancreas in children. *Am Surg* 1990; **56**:384–387.
- Bass J, DiLorenzo M, Desjardins JG, Grignon A, Ouimet A. Blunt pancreatic injuries in children: the role of percutaneous external drainage in the treatment of pancreatic pseudocysts. *J Pediatr Surg* 1988; **23**:721–724.
- Beckingham IJ, Krige JE, Bornman PC, Terblanche J. Endoscopic management of pancreatic pseudocysts. *Br J Surg* 1997; **84**:1638–1645.
- Aljarabah M, Ammori BJ. Laparoscopic and endoscopic approaches for drainage of pancreatic pseudocysts: a systematic review of published series. *Surg Endosc* 2007; **21**:1936–1944.
- Palanivelu C, Senthilkumar K, Madhankumar MV, Rajan PS, Shetty AR, Jani K, *et al.* Management of pancreatic pseudocyst in the era of laparoscopic surgery – experience from a tertiary centre. *Surg Endosc* 2007; **21**:2262–2267.
- Seitz G, Warmann SW, Kirschner HJ, Haber HP, Schaefer JW, Fuchs J, *et al.* Laparoscopic cystojejunostomy as a treatment option for pancreatic pseudocysts in children – a case report. *J Pediatr Surg* 2006; **41**:e33–e35.
- Bhattacharya D, Ammori BJ. Minimally invasive approaches to the management of pancreatic pseudocysts: review of the literature. *Surg Laparosc Endosc Percutan Tech* 2003; **13**:141–148.