

Letter to the Editor

Annals of Pediatric Surgery 2013, 9:157–158

Direct inguinal hernia containing a prolapsed bladder in an infant

Jasneet S. Bhullar^a, Michael Martin^b and Bassam Dahman^c, ^aDepartment of Surgery, Providence Hospital & Medical Centers, Southfield, Departments of ^bSurgery and ^cPediatric Surgery, St John's Hospital & Medical Centers, Detroit, Michigan, USA

Correspondence to Jasneet S. Bhullar, MD, MS, 16001 W 9 Mile Road, Department of Surgery, Providence Hospital & Medical Centers, Southfield, MI 48075, USA
Tel: +1 248 849 7638; fax: +1 248 849 5380; e-mail: drjsbhullar@gmail.com

Received 5 May 2013 accepted 6 August 2013

Case report

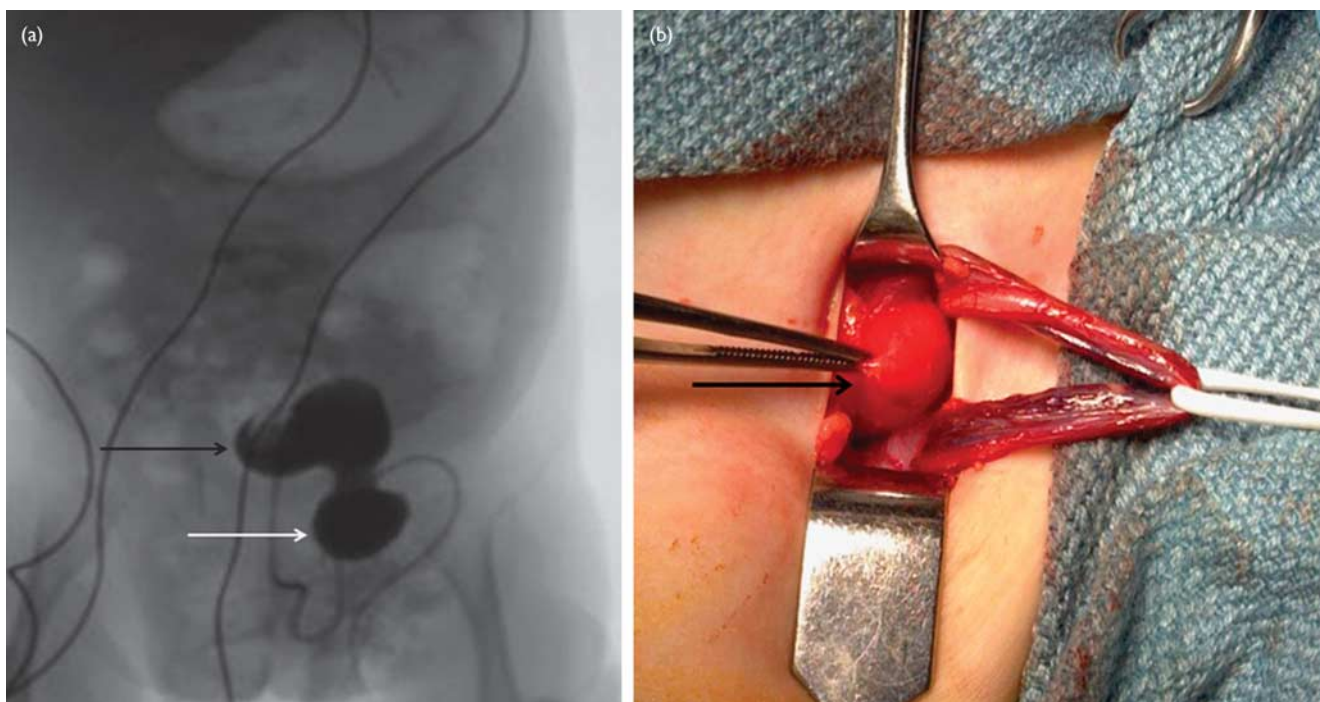
Direct inguinal hernias in children have been reported as 'extremely rare', with the reported incidence ranging between 0.2 and 0.9% of all inguinal hernia repairs [1–3]. Because of their rarity, they are often misdiagnosed and even missed during hernia repair [1]. There have been very few reports of visceral prolapse in a direct hernia in infants.

A 24-week preterm male infant was born through cesarean section with hyaline membrane disease requiring ventilatory support in the neonatal intensive care and was noted to have bilateral reducible inguinal hernias. He developed two episodes of UTI and gross hematuria. Abdominal ultrasound revealed bilateral mild hydronephrosis. Voiding cystourethrogram was performed to rule out vesicoureteric reflux but revealed partial herniation of the bladder into the large left inguinal hernia (Fig. 1a).

Intraoperatively, the right side showed the usual indirect inguinal hernia. Moreover, on the left side, an obvious large direct herniation of the bladder was noted through a thin attenuated transversalis fascia of the inguinal floor (Fig. 1b). The repair was done by approximating the well-defined medial edge of the transversalis to the inguinal ligament. Postoperatively, the patient recovered uneventfully.

Thus, if an infant presents with hematuria and has an inguinal hernia on physical examination, the possibility of bladder prolapse in the hernial sac should be kept

Fig. 1



(a) Cystogram showing the contrast-filled bladder (black arrow) prolapsing into the left-sided inguinal hernia (white arrow). (b) Intraoperative image showing the direct inguinal hernia sac containing the part of the urinary bladder (black arrow). The cord structures have been retracted with the white vessel loop.

in mind. This is a report of a rare direct inguinal hernia with a prolapsed bladder in an infant.

Acknowledgements

Conflicts of interest

There are no conflicts of interest.

References

- 1 Fonkalsrud EW, de Iorimier AA, Clatworthy HW. Femoral and direct hernias in infants and children. *JAMA* 1965; **192**:101–103.
- 2 Wright JE. Direct inguinal hernia in infancy and childhood. *Pediatr Surg Int* 1994; **9**:161–163.
- 3 Schier F. Direct inguinal hernias in children: laparoscopic aspects. *Pediatr Surg Int* 2000; **16**:562–564.