

# Pelvic ventral hernia repair in a pygopagus conjoint twin

Jasneet S. Bhullar<sup>a</sup>, Halah Abdulameer<sup>a</sup> and Michael T. White<sup>b</sup>

**Pelvic ventral hernia repair in a surviving conjoint twin with multiple congenital anomalies that make surgery a challenge. Conjoint twins are a rare. The incidence is reported to be in the range of 1/50 000 to 1/100 000 live births. Of the conjoint twins, 40% are stillborn and an additional one-third die within 24 h of birth. Those who survive through birth and surgical separation may present later in life with a wide range of complex congenital malformations. There are no reports on hernia incidence or hernia repair in surviving conjoint twins. *Ann Pediatr Surg* 9:152–154 © 2013 Annals of Pediatric Surgery.**

*Annals of Pediatric Surgery* 2013, 9:152–154

**Keywords:** conjoint twin, incisional hernia, pelvic hernia, ventral hernia

<sup>a</sup>Department of Surgery, Providence Hospital and Medical Centers, Southfield and <sup>b</sup>Department of Surgery, Detroit Receiving Hospital, Wayne State University, Detroit, Michigan, USA

Correspondence to Jasneet S. Bhullar, MD, Department of Surgery, Providence Hospital and Medical Centers, 16001 West Nine Mile Road, Southfield, MI 48075, USA  
Tel: +1 248 849 7638; fax: +1 248 849 5380;  
e-mail: drjsbhullar@gmail.com

Received 20 December 2012 accepted 27 August 2013

We report a case of a conjoint twin with pelvic ventral hernia who also had multiple congenital malformations that made the surgical management challenging. He underwent a mesh repair for the hernia; the mesh was customized to his abnormal anatomy. Preoperative imaging helped assess the multiple congenital anomalies and formulate a surgical management plan. On follow-up one and a half years later, he continues to do well. To manage surviving conjoint twins, it is important to image the whole body to identify anatomical anomalies for diagnosis and planning of appropriate operative procedures.

## Case report

An 18-year-old boy presented to the emergency department with extensive second-degree burns to his bilateral lower extremities secondary to his trousers catching fire. He had been born as a conjoint twin (pygopagus, omphalopagus) and had been surgically separated at birth; the other twin had not survived. The operative and follow-up details of the prior surgery could not be obtained despite persistent efforts. Physical examination revealed a ventral hernia in the lower abdomen and a large hernial pouch in the perineum. He was resuscitated and underwent lower extremity debridement with xenograft grafting. Postoperatively, he observed to have strangulation of the incisional hernia. Diagnostic workup was carried out and abdominal radiography revealed anomalous pelvic anatomy consistent with an abnormally short abdominal cavity, colon in the pelvic hernia pouch (Fig. 1a and b, black arrow), diastasis of the symphysis pubis (Fig. 1a and b, white arrow), and an anomalous bone connecting the anterior sacrum to the pubic symphysis (Fig. 1a and b, interrupted-line arrow). The chest radiograph revealed two accessory cervical ribs on the left side (Fig. 2). The diagnosis of a strangulated ventral hernia was made clinically and an urgent surgery was planned for the same. Therefore, more detailed imaging using computed tomography (CT) or MRI was not feasible at that time, even though it would have

been helpful keeping in mind the patient's previous surgery and other anomalies.

He underwent lower abdominal and pelvic exploration and reduction of the colon. Pubic symphysis diastasis and weak musculature was noted. The fascia was found to be retracted laterally on both sides. After mobilization of the fascia, a 10 × 15 cm nonabsorbable mesh was sutured to the fascia laterally to cover the hernial defect. After removing the excess subcutaneous fat and skin, the incision was closed in layers and the skin was closed in a Y-shape using staples. A follow-up abdominal radiograph showed the colon to be in the abdominal cavity (Fig. 1b). Postoperatively, the incisions healed well. He subsequently underwent split thickness skin grafting of his bilateral lower extremities. He recovered well and was discharged 1 month later after the wounds on his lower extremities healed. On follow-up one and a half years later, he continues to do well.

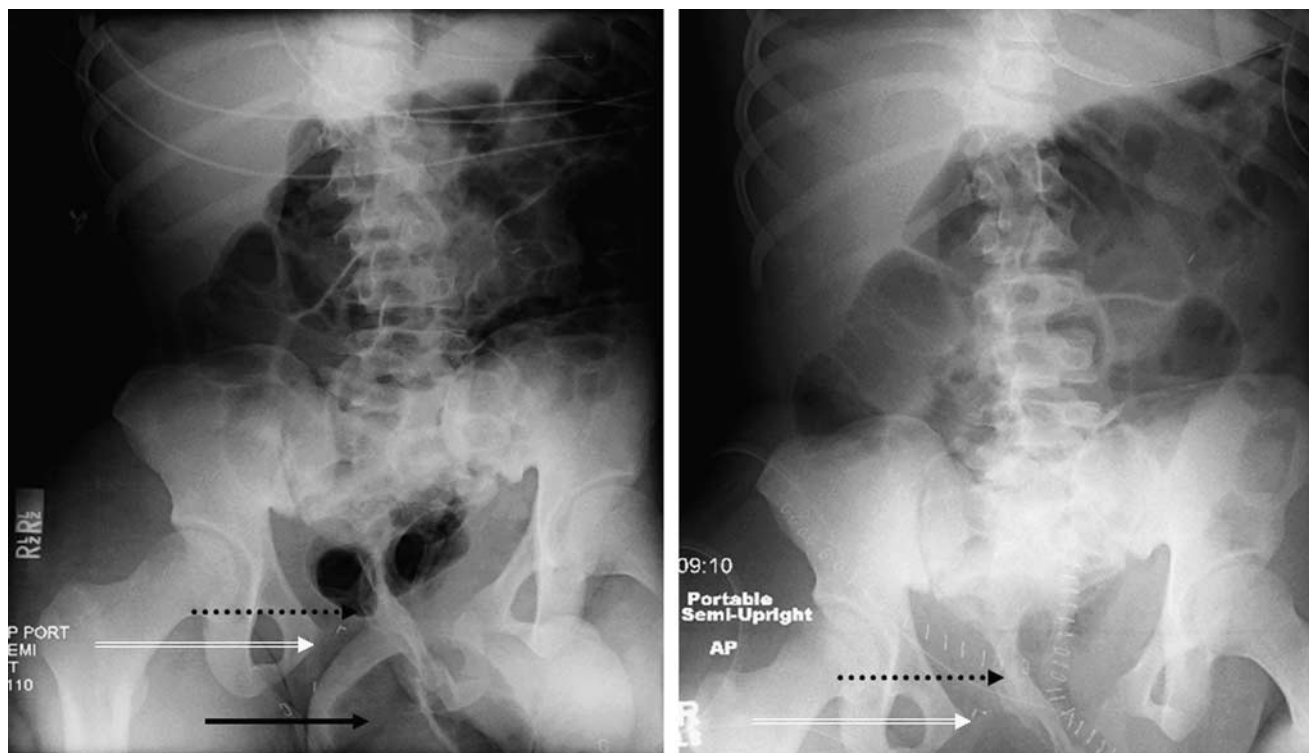
## Discussion

The incidence conjoint twins is reported to be in the range of 1/50 000 to 1/100 000 live births [1]. Of the conjoint twins, 40% are stillborn and an additional one-third die within 24 h of birth [2]. Of the mono chorionic monoamniotic pregnancies, ~1.3% are conjoint [3]. It is hypothesized that conjoint twins develop secondary to the incomplete fission of the germinal disc after the 12th day of embryogenesis [4].

Conjoint twins are classified according to their major site of union, to which the ending 'pagus' is added, meaning 'fixed' [5,6], for example, thoracopagus refers to twins joint at the thoracic level; this is the most common type accounting for 40% of cases. Omphalopagus refers to twins who joint at the abdomen, often including the lower thorax as well. Craniopagus refers to twins joint at the head, and pyopagus refers to those with sacral fusion.

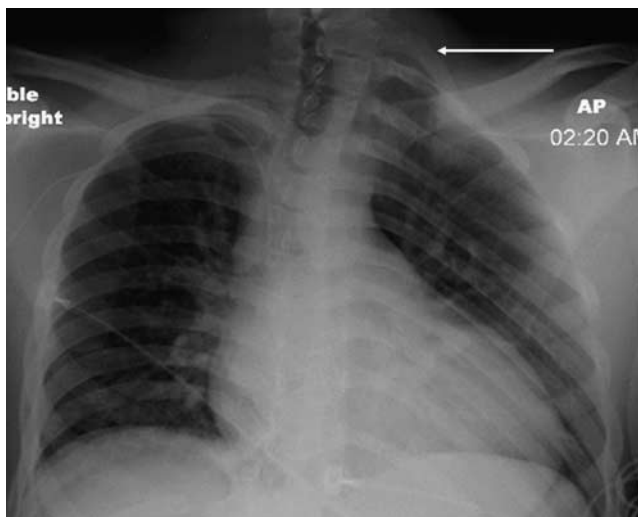
Recently, three-dimensional ultrasound imaging has been advocated as a new tool to demonstrate the extent of fusion in conjoint twins prenatally and to provide detailed

Fig. 1



(a) Preoperative abdominal radiograph showing a gas-filled colon in the hernial sac protruding through the diastasis (black arrow). It shows a small abdominal cavity and diastasis of the pubic symphysis (white arrow) with an anomalous bone from the anterior sacrum to the pubic symphysis (black interrupted-line arrow). (b) Postoperative abdominal radiograph showing the replaced colon in the abdominal cavity along with the previously described anatomical bony malformations and stapes at the incision site.

Fig. 2



Chest radiograph showing cervical ribs on the left side (arrow).

information for improved counseling as regards postnatal surgical interventions [3]. The congenital malformations are caused by a large spectrum of possibilities. Some of the more complex malformations may include shared organ systems, which may affect the survival of one or both twins during separation. There has been only a single reported case of

successful separation of a conjoint heart in thoracopagus twins who had a conjoint atria [7].

Incisional hernias develop in 3.8–11.5% of patients after abdominal surgery, with 90% occurring within 3 years of operation [8–10]. There have been no reports on the incidence of hernias in surviving conjoint twins or on hernia repairs in this small group of patients who survive and present at a later point in life. Numerous methods of repair have been described, namely, primary repair in one or two layers or the Mayo-type overlap, use of fascia (local or flaps) with suture darns, and use of fascia with synthetic mesh (polypropylene or Marlex mesh, stainless steel, mersilene or expanded polytetrafluoroethylene) [11].

In our patient we opted to repair the ventral hernia in a manner customized to his unique anatomy. A nonabsorbable mesh was essential for the repair as congenital weakness of the abdominal wall musculature along with chronic presentation of the hernia had further weakened the fascia and muscles despite the young age of the patient. Meticulous dissection with a high degree of suspicion for unfavorable and different anatomy was the essence.

The importance of radiological imaging, such as ultrasound, radiography, CT, and MRI, as a part of the preoperative workup of such unique patients cannot be emphasized more. They have proven to be valuable not only for assessing the feasibility of separation at birth, but also in providing

a better definition of the morphology in these patients [3]. In our patient the diagnosis was made clinically and an urgent surgery was performed for the strangulated ventral hernia. As time was of the essence, a more detailed imaging technique like CT or MRI was not feasible at that time, even though it would have been helpful. Imaging should be performed for any diagnostic or surgical procedure planned on such patients either early or later in life.

Radiological imaging proved to be an essential aid in diagnosing the anatomical anomalies that existed in our patient and helped us to be prepared for the abnormal surgical anatomy that we encountered intraoperatively. This is the first reported case on the repair of pelvic ventral hernia in a surviving conjoint twin.

### Acknowledgements

#### Conflicts of interest

There are no conflicts of interest.

### References

- 1 Ambar SS, Halkati PC, Patted SV, Yavagal SV. Twin heart with a fused atria and separate ventricles in conjoined twins. *Ann Pediatr Cardiol* 2010; **3**:196–198.
- 2 Aparna C, Renuka I, Sailabala G. Dicephalus dipus tribrachius: a case report of unusual conjoined twins. *Indian J Pathol Microbiol* 2010; **53**:814–816.
- 3 Salmaso R, Manara R, Fassan M. Radiological–pathological comparison in a case of conjoined gnatho-thoracopagus twins. *Fetal Diagn Ther* 2009; **26**:223–226.
- 4 DeStephano CC, Meena M, Brown DL, Davis NP, Brost BC. Sonographic diagnosis of conjoined diamniotic monochorionic twins. *Am J Obstet Gynecol* 2010; **203**:e4–e6.
- 5 Spitz L, Kiely EM. Conjoined twins. *JAMA* 2003; **289**:1307–1310.
- 6 Spitz L, Kiely EM. Experience in the management of conjoined twins. *Br J Surg* 2002; **89**:1188–1192.
- 7 O'Neill JA Jr, Holcomb GW III, Schnauer L, Templeton JM, Bishop HC. Surgical experience with thirteen conjoined twins. *Ann Surg* 1988; **208**:299–312.
- 8 Kingsnorth A, Leblanc K. Hernias: inguinal and incisional. *Lancet* 2003; **362**:1561.
- 9 Bucknell TE, Cox PJ, Ellis H. Burst abdomen and incisional hernia: a prospective study of 1129 major laparotomies. *BMJ* 1982; **284**:931–933.
- 10 Mudge M, Hughes LE. Incisional hernia: a 10-year prospective study of incidence and attitudes. *Br J Surg* 1985; **72**:70–71.
- 11 Jenkins TPN. Incisional hernia repair: a mechanical approach. *Br J Surg* 1980; **67**:335–336.