

Epidemiologic and clinical aspects of varicocele among adolescent schoolboys at Cotonou

Michel A. Fiogbe^a, Antoine S. Gbenou^b, Jules Alao^c, Serge Mitchihoungbe^b, Dina Gbenou^d and Roumanatou Bankole-Sanni^e

Objectives The consequences of varicocele can be dramatic, with reproduction difficulties. This survey aimed to determine the prevalence of varicocele among schoolboys at Cotonou and describe its clinical aspects.

Patients and methods This prospective and analytical study, complying with all ethical requirements, was conducted from 1 February to 31 August 2012 on schoolboys of secondary schools in Cotonou who were aged between 10 and 19 years. The data collected included information on sociodemographic characteristics such as age and ethnicity and clinical aspect symptoms such as history, physical signs, level of sexual maturity, grade of varicocele, testicular volume, and associated anomalies.

Results The prevalence of varicocele was 5.47% (149/2724). The ages of boys with varicocele ranged between 12 and 19 years (mean age 16.50 ± 2.03 years). The peak prevalence of varicocele was 18 years and it varied significantly with age, ethnicity, and level of sexual development. Varicocele was symptomatic in only 28.86% of cases. The associated symptoms were scrotal weight (17.44%) and scrotal pain (14.77%), and these occurred mainly during football or intense physical effort (36.91%). Family history was remarkable in some cases.

Introduction

Genitourinary malformations such as an obvious varicocele are often ignored by adolescents and their parents. The specific problem of varicocele in adolescents arises from its impact on testis growth and spermatogenesis [1]. Its real pathological mechanism remains unknown [2]. It may be primary, due to a vascular malformation including valvular insufficiency of spermatic veins, or secondary to renal or adrenal tumor or renal vein thrombosis [3]. Despite its prevalence in adolescents and its adverse consequences, few data are available on it among adolescents in Africa, particularly in Benin. The authors of this survey aimed to establish the prevalence of varicocele among schoolboys in Cotonou and describe its clinical aspects.

Patients and methods

This descriptive, cross-sectional, and analytical survey was conducted from 1 February to 31 August 2012. It involved schoolboys of secondary schools of Cotonou. Schoolboys aged 10–19 years who agreed to participate (after parental and school authorities' consent) were included in this study. The boys were examined by three pediatric surgeons well experienced in the diagnosis of urogenital pathologies in children. The sample size was calculated to be 2701 using the Schwartz formula ($n = \alpha^2 pqc/i^2$). Sampling was carried out by a random selection of 30 clusters of schoolboys in each involved secondary school. Data were collected on

This pathology was mainly located at the left (76.51%). On the basis of the Amelar and Dublin classification, varicoceles were of grades 1, 2, and 3, respectively, in 2.25, 2.56, and 0.97% of cases. Left testicular hypotrophy was clinically noticed in 34.90% of boys affected by varicocele but with respect to severity.

Conclusion More attention should be given to this issue by establishing a nationwide program of detection and treatment of varicocele in schools. *Ann Pediatr Surg* 9:136–139 © 2013 Annals of Pediatric Surgery.

Annals of Pediatric Surgery 2013, 9:136–139

Keywords: adolescents, epidemiologic clinical aspects, varicocele

^aPediatric Surgery Service of National Teaching Hospital (CNHU), ^bPediatric Surgery Service of Mother and Child Hospital of Lagune (HOMEL), ^cPediatric Medical and Genetic Service of Mother and Child Hospital of Lagune (HOMEL), ^dWHO Representative Office, Cotonou and ^ePediatric Surgery Service of Teaching Hospital (CHU) of Treichville, Abidjan

Correspondence to Michel A. Fiogbe, Pediatric Surgery Service of National Teaching Hospital (CNHU), 02 BP8229 Cotonou, Benin
Tel: +229 90 90 15 19/ +229 94 05 41 49; fax: +229 21 30 40 96;
e-mail: michfiogbe@yahoo.fr

Received 21 February 2013 accepted 22 August 2013

varicocele characteristics, sociodemographic conditions (age and ethnicity), and clinical aspects (symptoms, history, physical signs, level of sexual maturity, grade of varicocele, testicular volume, and associated abnormalities). According to the classification of Tanner, stage 1 patients are presexually mature and those at stages 2–5 are mature [4]. Varicocele gradation was based on the Dubin and Amelar [5] classification in which grade 1 indicates varicocele detected only by the Valsalva maneuver, grade 2 indicates a palpable varicocele, and grade 3 indicates a visible varicocele. Testicular volume (ml) was estimated using the Takiara formula $TV = (0.71 \times \text{width} \times \text{length} \times \text{height})/1000$ [6]. The dimensions of the testes were measured manually with the patient lying on his back with a flexible tape meter as we had no orchidometer. Testicular hypotrophy (TH) was defined by a difference of at least 2 ml compared with the contralateral testis or a decrease in volume below normal values for age [1,4]. Data were analyzed with Epi info 3.5.1 (USA) software and proportions were compared with the χ^2 -test with *P* value less than or equal to 0.05 for statically acceptable significance. This preliminary study allowed us to have a cohort of adolescents who would be followed up regularly to adulthood to measure the impact on fertility.

Results

Among 2724 schoolboys investigated, 149 showed varicocele with a prevalence of 5.47% (95% confidence interval:

Table 1 Varicocele and schoolboys' ages

| Age (years) | Boys | Boys with varicocele [n (%)] | OR (95% CI) | P |
|-------------|------|------------------------------|-------------------|------|
| 10–12 | 478 | 7 (1.46) | 1 | 0.00 |
| 12–19 | 2246 | 142 (6.32) | 4.45 (2.04–10.64) | |
| Total | 2724 | 149 | | |

CI, confidence interval; OR, odds ratio.

4.66–6.41%). The mean age of the schoolboys with varicocele was 16.50 ± 2.03 years, ranging from 12 to 19, and prevalence varied across the ages with a higher prevalence (8.65%) around 18 years. Tables 1 and 2 show varicocele distribution across the ages. Varicocele prevalence was statistically higher (9.09%) among Yoruba and related groups ($P=0.02$), as shown in Table 3. Symptoms were observed in 43 boys (28.86%). These included scrotal heaviness ($n=26$; 17.45%), scrotal pain ($n=22$; 14.77%), scrotal swelling ($n=11$; 7.38%), abdominal pain ($n=11$; 7.38%), back pain ($n=11$; 7.38%), and pelvic pain ($n=1$; 0.67%). Symptoms appeared mainly at 13–19 years ($n=30$; 71.4%) and were experienced during intensive physical effort including regular football practice ($n=55$; 37%), prolonged standing ($n=14$; 9.4%), and at night ($n=1$; 0.7%). Five schoolboys with varicocele and suffering from inguinal hernia were treated at the same time. The patient with contralateral cryptorchidism was surgically treated separately. Among the 10 parents who agreed to be investigated, three had varicocele, three had inguinal hernia, two had vaginal hydrocele, one had an epididymal cyst, and one suffered from cryptorchidism. Schoolboys with varicocele who were sexually mature ($n=142$) represented 95.30% of the patients. Varicoceles were predominantly on the left side compared with the right side – 76.51 versus 2.68% ($P=0.00$) – and most often unilateral – 79.19 versus 20.81% ($P=0.00$). Four schoolboys with varicocele on the right side showed no clinically suggestive signs. In the age group of 10–12 years, four schoolboys had grade 1 and three had grade 3 varicocele, whereas in the 13–19-year group 54 schoolboys had grade 1, 63 had grade 2, and 25 had grade 3, with no differences between them ($P=0.29$).

Varicocele was associated with inguinal hernia in five patients (33.3%), with spermatic cord cyst in four patients (26.67%), with vaginal hydrocele in three patients (20%), with epididymis cyst in two (13.33%), and with undescended testis in one (6.67%).

Testicular volume was clinically normal on the right side and decreased on the left in 52 schoolboys (34.90%). TH was statistically in relation to varicocele, as shown in Table 4. TH frequency increased significantly ($P=0.06$) according to varicocele grade [grade 1, 17/58 (29.31%), grade 2, 21/66 (31.82%), and grade 3, 14/25 (56%)]. The mean testicular volumes on the left in boys with varicocele were lower than those of healthy individuals, as shown in Fig. 1. Average testicular volume on the right side showed no differences between healthy and affected schoolboys, as reported in Fig. 2.

Discussion

The overall prevalence of varicocele in this study was 5.47%, which is similar to the 5.6% reported by Prabakaran *et al.* [7]

Table 2 Varicocele prevalence and ages

| Age (years) | Boys | Boys with varicocele [n (%)] |
|-------------|------|------------------------------|
| 10 | 59 | 0 (0) |
| 11 | 129 | 0 (0) |
| 12 | 290 | 7 (2.41) |
| 13 | 369 | 15 (4.07) |
| 14 | 344 | 25 (7.27) |
| 15 | 410 | 24 (5.85) |
| 16 | 354 | 21 (5.93) |
| 17 | 263 | 22 (8.37) |
| 18 | 208 | 18 (8.65) |
| 19 | 298 | 17 (5.70) |
| Total | 2724 | 149 (5.47) |

$\chi^2=15.55$.
 $P=0.03$.

Table 3 Varicocele prevalence and ethnicity

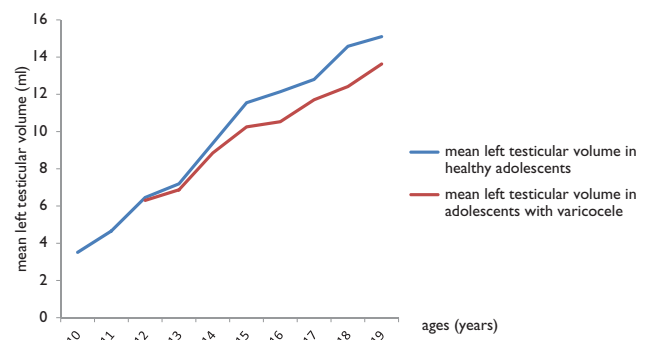
| Age (years) | Boys | Boys with varicocele [n (%)] |
|---------------------------|------|------------------------------|
| Fon and related groups | 1911 | 103 (5.39) |
| Adja and related groups | 445 | 22 (4.94) |
| Yoruba and related groups | 242 | 22 (9.09) |
| Others | 126 | 2 (1.59) |
| Total | 2724 | 149 (5.47) |

$\chi^2=10.07$.
 $P=0.02$.

Table 4 Testicular hypotrophy and apparent varicocele

| | TH | No TH | OR (95% CI) | P |
|---------------|----|-------|-------------------|---------|
| No varicocele | 20 | 2555 | 1 | 0.00000 |
| Varicocele | 52 | 97 | 68.48 (38.13–124) | |
| Total | 72 | 2652 | | |

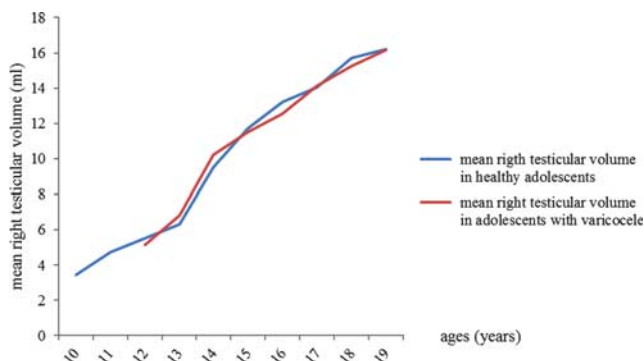
CI, confidence interval; OR, odds ratio; TH, testicular hypotrophy.

Fig. 1

Mean left testicular volume according to age in adolescents with varicocele (red line) and in healthy boys (blue line).

in Bulgaria in 2006 and the 5.96% reported by Yigitler *et al.* [8]. It is slightly higher than the 4.1% found by Stavropoulos *et al.* [4] in Greek schoolboys and very low compared with the 7.2, 15, and 35% reported by other authors [9–11]. The mean age of schoolboys with varicocele was 16.50 ± 2.03 years. Vanderbrink *et al.* [12] found similar results (15 ± 2.7 years), whereas the mean age in the study by Nyrazy *et al.* [13] was 12.30 years. Varicocele appeared most often between 13 and 19 years of age according to

Fig. 2



Mean right testicular volume according to age in adolescents with varicocele (red line) and in healthy boys (blue line).

several reports [7,14]. Varicocele prevalence varies significantly with age and reaches a peak prevalence (8.65%) at 18 years. We had no schoolboy with varicocele under 12 years. Stavropoulos *et al.* [4] reported on the scarcity of the phenomenon before teenage with no varicocele before 9 and a peak at 14 years. A double peak was possible, as reported by Prabakaran *et al.* [7] (12 and 19 years). D'Agostino and Belloli [15] showed that varicocele prevalence increased with age up to 18 years. Varicocele prevalence was significantly higher among the Yoruba and related groups, and this finding supported the fact that varicocele could be a full or partially genetic disorder, as some ethnic groups are affected more [16–18]. Asymptomatic varicocele was seen in 71.14% of schoolboys. This rate is low compared with the 92.9% obtained by Greenfield *et al.* [19]. It should be kept in mind that in the study by some authors like Bong and Koo [20] varicocele was typically asymptomatic. Symptomatic cases found in this survey could be explained by the association with additional genitourinary disorders in some schoolboys. Scrotal heaviness and pain were symptoms common among boys with varicocele, and these symptoms were previously reported by Kattan [21] with higher rates. Symptoms appeared in 69.05% of boys between 12 and 19 years of age, which is the age of varicocele onset. We believe that these symptoms mentioned above are mostly due to varicocele. However, symptoms before 12 years of age could be explained by the association with additional genitourinary malformations. Discomfort during intense physical effort was frequently the referral reason for varicocele, as reported by Reinberg and Meyrat [22] and Scaramuzza *et al.* [23]. Moreover, 30–40% of adults with primary infertility and 69–81% with secondary infertility suffer from varicocele [24,25]. In contrast, 20–30% of patients with varicocele experience infertility [26]. However, young reproductive capacity can be preserved with routine screening and appropriate management. Varicocele was discovered in some parents. These family histories evoke the inheritance of varicocele as mentioned above, which can be associated with ethnic distribution; this should encourage systematic detection among male relatives. An overall 95.30% of varicoceles were found in sexually mature patients. This is consistent with the observations made by other authors [4,14]. The hormonal inflation at puberty could be a favorable factor for varicocele with valvular insufficiency of pampiniform

veins. We postulate that the sudden increase in the weight and size of the testes at puberty induces a reduction in the superior aorto-mesenteric angle and leads to more varicoceles [7]. Varicocele affected the left side more than it did the right (76.51 vs. 2.68%). It was more often unilateral than bilateral (79.19 vs. 20.81%). This left predominance was noticed by several authors [4,5,11,12,14,27–31]. This could be explained by anatomical and hemodynamic factors such as the long path of the left spermatic vein, the straightness of the junction with the renal vein, and the frequent absence of valves. Grade 2 varicocele was the most frequent in this study, as seen by Esposito *et al.* [32]. However, in the literature, grade 1 is seen as having the greatest predominance [33]. Inguinal hernia was the disease frequently found to be associated with varicocele, followed by spermatic cord cyst and vaginal hydrocele. Some of these abnormalities were previously reported by Yigithler *et al.* [8]. Left TH was found in 52 (34.90%) of the 149 schoolboys with varicocele. The rate of TH varies largely through reports ranging from 8.6 to 81.5% [11,14,29,34]. As assumed by some authors, testes on the right side were unremarkable in the presence or absence of varicocele [4,14]. TH in our study was statistically associated with clinical varicocele as it seems to expose boys to varicocele [35,36]. The fact that varicocele treatment could lead to reversal in testicular growth and improved semen parameters confirms the pathogenic mechanism [1,34,37]. The frequency and risk for TH increased with the severity of varicocele, as reported by Okuyama *et al.* [34].

Conclusion

This survey confirmed what is known elsewhere regarding varicocele, especially in schoolboys. More attention should be given to this issue by establishing a nationwide program of detection and treatment of varicocele in schools.

Acknowledgements

The authors thank the students, parents, and Heads of schools for their help.

Conflicts of interest

There are no conflicts of interest.

References

- Fontaine E, Benoit G, Jardin A, Fontaine E, Benoit G, Jardin A, Beurton D. Varicocele in the adolescent. *Prog Urol* 2000; **10**:1099–1107.
- Noske HD, Weidner W. Varicocele: a historical perspective. *World J Urol* 1999; **17**:151–157.
- Dunnick NR, Illescas FF, Mitchell S, Cohan RH, Saeed M. Interventional urology. *Invest Radiol* 1989; **24**:831–841.
- Stavropoulos NE, Mihailidis I, Hastazeris K, Moissidou R, Louka G, Filiadis I, *et al.* Varicocele in schoolboys. *Arch Androl* 2002; **48**:187–192.
- Dubin L, Amelar RD. Varicocelectomy: 986 cases in a 12 years study. *Urology* 1977; **10**:446–449.
- Paltiel H, Diamond D, Di Canzio J. Testicular volume: comparison of orchidometer and US measurements in dogs. *Radiology* 2002; **222**:114–119.
- Prabakaran S, Kumanov P, Tomova A, Hubaveshki S, Agarwal A. Adolescent varicocele: association with somatometric parameters. *Urol Int* 2006; **77**:114–117.
- Yigitler C, Yanardag H, Silit E, Alpay AS. Evaluation of inguinoscrotal pathologies among adolescents with special emphasis on association between varicocele and body mass index. *J Urol* 2012; **9**:592–599.
- Cayan S, Akbay E, Bozlu M, Doruk E, Erdem E, Acar D, Ulusoy E. The effect of varicocele repair on testicular volume in children and adolescents with varicocele. *J Urol* 2002; **168**:731–734.

- 10 Niedzielski D, Paduch D, Raczynski P. Assessment of adolescent varicocele. *Pediatr Surg Int* 1997; **12**:410–413.
- 11 Akbay E, Cayan S, Doruk E, Duce MN, Bozlu M. The prevalence of varicocele and varicocele-related testicular atrophy in Turkish children and adolescents. *BJU Int* 2000; **86**:490–493.
- 12 Vanderbrink BA, Palmer LS, Gitlin J, Levitt SB, Franco I. Lymphatic-sparing laparoscopic varicoectomy versus microscopic varicoectomy: is there a difference? *Urology* 2007; **70**:1207–1210.
- 13 Nyirády P, Kiss A, Pirót L, Sárközy S, Bognár Z, Csontai A, Merksz M. Evaluation of 100 laparoscopic varicocele operations with preservation of testicular artery and ligation of collateral vein in children and adolescents. *Eur Urol* 2002; **42**:594–597.
- 14 Kumanov P, Robeva RN, Tomova A. Adolescent varicocele: who is at risk? *Pediatrics* 2008; **121**:53–57.
- 15 D'Agostino S, Belloli GP. An under estimated pathology in childhood and adolescence. *Pediatr Med Chir* 1992; **14**:7–12.
- 16 Gökçe A, Davarci M, Yalçinkaya FR, Güven EO, Kaya YS, Helvacı MR, Balbay MD. Hereditary behavior of varicocele. *J Androl* 2010; **31**:288–290.
- 17 Raman JD, Walmsley K, Goldstein M. Inheritance of varicoceles. *Urology* 2005; **65**:1186–1189.
- 18 Mokhtari G, Pourreza F, Falahatkar S, Kamran AN, Jamali M. Comparison of prevalence of varicocele in first-degree relatives of patients with varicocele and male kidney donors. *Urology* 2008; **71**:666–668.
- 19 Greenfield SP, Seville P, Wan J. Experience with varicoceles in children and young adults. *J Urol* 2002; **168**:1684–1688.
- 20 Bong GW, Koo HP. The adolescent varicocele: to treat or not to treat. *Urol Clin North Am* 2004; **31**:509–515.
- 21 Kattan S. The impact of internal spermatic artery ligation during laparoscopic varicoectomy on recurrence rate and short postoperative outcome. *Scand J Urol Nephrol* 2001; **3**:118–121.
- 22 Reinberg O, Meyrat BJ. Childs and adolescent's varicocele. *Rev Med Suisse* 2007; **136**:2779–2782.
- 23 Scaramuzza A, Tavana R, Marchi A. Varicoceles in young soccer players. *Lancet* 1996; **348**:1180–1181.
- 24 Jarow JP. Effects of varicocele on male fertility. *Hum Reprod Update* 2001; **7**:59–64.
- 25 Gorelick J, Goldstein M. Loss of fertility in men with varicocele. *Fertil Steril* 1993; **59**:613–616.
- 26 Figueroa ET, Casale P. Hydroceles and varicoceles. In: Mattei P, editor. *Surgical directives: pediatric surgery*. New York: Lippincott Williams & Wilkins; 2003. pp. 719–721.
- 27 Klufio GO. Varicoectomy: what benefits to the infertile Ghanaian male? *Ghana Med J* 1995; **27**:549–553.
- 28 Sun N, Cheung TT, Khong PL, Chan KL, Tam PK. Varicocele: laparoscopic and color Doppler follow-up. *J Pediatr Surg* 2001; **36**:1704–1707.
- 29 Koyle MA, Oottamasathien S, Bargawi A, Rajimwale A, Furness PD. Laparoscopic Palomo varicocele ligation in children and adolescent: results of 103 cases. *J Urol* 2004; **172**:1749–1752.
- 30 Comhaire F, Zalata A, Mahmoud A, Depuydt C. Pathophysiological effect of varicocele treatment. *Urologe A* 1998; **37**:251–253.
- 31 Lopez C, Serres-Cousine O, Averous M. Adolescent varicocele. Treatment with sclerotherapy and percutaneous embolization: reflections on the method. About 23 cases. *Prog Urol* 1998; **8**:382–387.
- 32 Esposito C, Monguzzi G, Gonzalez-Sabin MA, Rubino R, Montinaro L, Papparella A, et al. Results and complications of laparoscopic surgery for pediatric varicocele. *J Pediatr Surg* 2001; **36**:767–769.
- 33 Yaman O, Soygur T, Zumrutbas AE, Resorlu Bv. Results of microsurgical subinguinal varicoectomy in children and adolescents. *J Urol* 2006; **68**:410–412.
- 34 Okuyama A, Nakamura M, Namiki M, Takeyama M, Utsunomiya M, Fujioka H, et al. Surgical repair of varicocele at puberty: preventive treatment for fertility improvement. *J Urol* 1988; **139**:562–564.
- 35 Witt MA, Lipshultz LI. Varicocele: a progressive or static lesion? *Urology* 1993; **42**:541–543.
- 36 Pozza D, D'ottavio G, Masci P, Coia L, Zappavigna D. Left varicocele at puberty. *Urology* 1983; **22**:271–274.
- 37 Paduch DA, Niedzielski J. Repair versus observation in adolescent varicocele: a prospective study. *J Urol* 1997; **158**:1128–1132.