

Nonconventional mesocaval prosthetic shunt interposition in refractory case with portal hypertension in a 10-kg female infant

Ghazwani Salman, Arnauld Delarue and Bertrand Roquelaure

Surgical treatment of portal hypertension in infants is challenging because of the high risk of shunt thrombosis. A 10-kg female infant underwent six failed procedures before being successfully treated by interposition of a 10-mm-diameter prosthetic graft between two 3-mm-diameter splanchnic veins and the inferior vena cava. Follow-up at 10 years demonstrates shunt patency and normal development without rebleeding. An aggressive surgical strategy is justified as long as even nonconventional techniques are available to prevent life-threatening complications of portal hypertension. Prosthetic grafts can be used when no autologous vein graft is available. Decellularized allografts with reduced immunogenicity may also be effective alternative

materials. *Ann Pediatr Surg* 14:39–41 © 2018 Annals of Pediatric Surgery.

Annals of Pediatric Surgery 2018, 14:39–41

Keywords: mesocaval anastomosis, PHT, prosthetic shunt

Department of Pediatric Surgery and Pediatric Gastroenterology, Timone Children University Hospital, Marseille, France

Correspondence to Arnauld Delarue, MD, Department of Pediatric Surgery and Pediatric Gastroenterology, Timone Children University Hospital, Marseille 13005, France
Tel: +33 491 386 683; fax: +33 432 753 672;
e-mail: arnauld.delarue@ap-hm.fr

Received 13 June 2016 accepted 4 February 2017

Introduction

Prehepatic portal hypertension (PHT) in children is frequently associated with portal vein thrombosis and cavernous transformation of the vessel after umbilical vein catheterization during the neonatal period. A wide range of portacaval shunt techniques may be used for the surgical treatment of PHT [1,2]. This report describes a challenging case of neonatal PHT in which numerous attempts using conventional shunts have failed. Successful treatment was finally achieved by interposition of polytetrafluoroethylene (PTFE) prosthesis between two small newly formed splanchnic veins and the inferior vena cava (IVC).

Case report

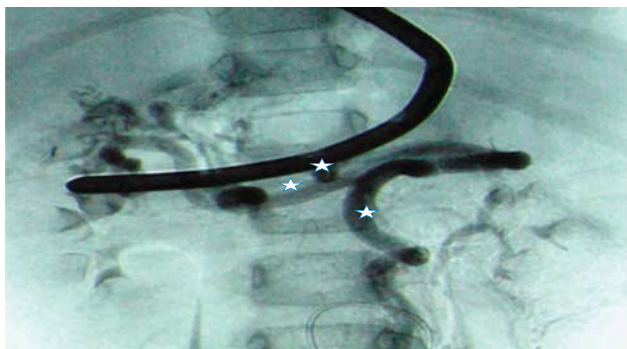
A 9-month-old girl weighing 5 kg was admitted to the emergency department owing to massive hematemesis. She was born at 27 weeks of gestation (weight = 650 g) in a setting of acute fetal distress and spent 4 months in neonatal intensive care unit. She presented multiple complications of prematurity including anemia and bronchopulmonary dysplasia and underwent umbilical vein catheterization. Workup at the time of admission demonstrated prehepatic PHT and splenomegaly. Upper gastrointestinal endoscopy revealed grade 3 esophageal varices. Ultrasound and MRI showed portal vein thrombosis and cavernoma. Initial liver function and coagulation tests were normal. All treatments failed to prevent the recurrence of hemorrhagic episodes. Conservative treatments included sclerotherapy of varices, β -blocker therapy, and octreotide. Initial operation was performed at the age of 11 months. A Meso-Rex bypass was not feasible because the left portal vein was found to be thrombosed intraoperatively, and a Warren splenorenal shunt was done. Multiple emergency procedures were required soon after: thrombectomy on Postoperative day-4 (POD-4), H-type mesocaval shunt using the right internal jugular vein on POD-10, and thrombectomy on POD-12.

Sugiura gastric disconnection on POD-14 and redo mesocaval shunt using an 8-mm PTFE prosthesis in POD-60. Anastomoses were performed with assistance of an operative microscope and anticoagulation therapy routinely added. The later shunt remained patent for 10 months before thrombosis occurred. However, the child's condition and growth improved for 20 months. At the age of 3 years, the 10-kg child was admitted for massive hematemesis leading to hemorrhagic shock. After stabilization, angiography demonstrated the presence of two newly formed splanchnic ('pancreatic' and 'colic') veins that were deemed suitable for surgical shunting (Fig. 1). A nonconventional shunt was performed: the colic vein was anastomosed end-to-side to the pancreatic vein using interrupted 8-0 sutures to gather the two splanchnic flows in which the pressure was 28 mmHg. A 3-cm-long, 10-mm-diameter nonringed PTFE prosthesis was connected between the distal pancreatic vein and the infrarenal IVC (Image 1). After shunting, pressure in the mesenteric network dropped to 13 mmHg, whereas pressure in the IVC was 11 mmHg. Heparin therapy was started intraoperatively. On the following day, reoperation was required to relieve occlusive compression of the afferent vein by the prosthesis that was shortened to 2 cm. The postoperative course was then uneventful. Ultrasonographic evaluation and splenoportography at 1-year follow-up assessed patency of the shunt and showed residual segmental sinistral PHT in the splenic region. Grade 2 esophageal varices underwent endoscopic preventive sclerotherapy 5 years after shunting. At the age of 13.5 years, the shunt is patent and bleeding had not recurred after 10 years and 7 months. The child has satisfactory weight and growth gain (40 kg, 146 cm, -1 SD). She shows neither clinical signs of PHT nor biological signs of hypersplenism.

Discussion

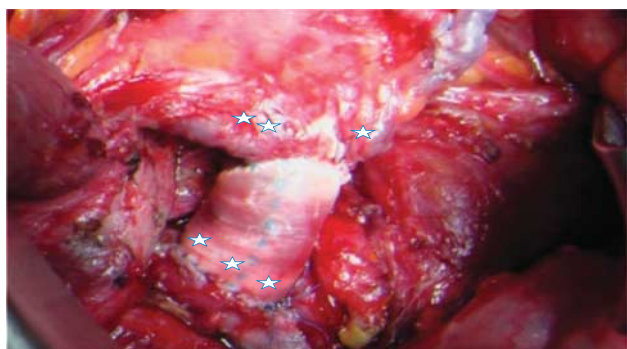In children, PHT due to extrahepatic block often results from portal thrombosis secondary to umbilical vein catheterization during the neonatal period. This complication

Figure 1



Angiography showing a newly formed colic (*) and pancreatic veins (**).

Image 1



End-to-side anastomosis between colic (*) and pancreatic veins (**) of 3-mm-diameter, polytetrafluoroethylene prosthesis interposed between the distal pancreatic vein and the inferior vena cava (***) .

occurs in 1.3–43% of cases [1,2]. Our patient presented numerous other risk factors for portal thrombosis – that is, prematurity, bronchodysplasia, hypoxemia, and sepsis [3]. Surgical treatment is included beside conservative medical treatment in the therapeutic armamentarium for extrahepatic PHT [4]. Early surgical intervention is recommended if vasoactive drugs (e.g. somatostatin) and endoscopic modalities (sclerotherapy and variceal ligation) fail [4,5]. Portosystemic shunt creation in patients less than 2 years of age and those involving small-diameter veins is challenging because of the high risk of thrombosis [6]. The same surgeon, head of the pediatric liver transplantation program and skilled in PHT surgery, performed all shunt procedures. Anastomoses were performed with microsurgical techniques under microscope magnification. Shunt thrombosis occurred supposedly because of the small size of the vessels of this 5-kg girl knowing that she has no coagulation disorders. Routine anticoagulation therapy did not prevent thrombosis. Surgery was initiated with a distal Warren shunt, as a Meso-Rex shunt was not feasible. The retroaortic course of the left renal vein could be partially responsible for the failure of the Warren shunt. Two attempts of mesocaval shunt and a Sugiura operation performed on an emergency basis also failed. Repeated shunt failures progressively reduced the extent of the available splanchnic vein network. At the time of the last

hemorrhagic attack, angiography identified only two 3-mm-diameter newly formed veins (pancreatic and colic vein) deemed suitable for shunting. Using microsurgical techniques, an end-to-side anastomosis was made between the two vessels to increase the venous inflow. The distal pancreatic vein was connected to the IVC by interposition of 10-mm PTFE prosthesis. The preferred shunt material for the treatment of PHT in children is an autologous venous graft, especially using the internal jugular vein. However, prosthetic PTFE grafts are used extensively in adult patients [7,8]. Few reports have described long-term patency outcome of prosthetic shunts in pediatric PHT [4,9]. Advantages of PTFE grafts include availability and sufficient stiffness to resist compression by adjacent organs that is a risk factor for thrombosis [8,10]. Sizing is an important factor in the successful use of prosthetic grafts. It has been recommended that the prosthesis be as short as possible to prevent kinking, promote internal coverage by endothelial cells, and reduce the risk of thrombosis [8]. In our case, reoperation was necessary to shorten the prosthesis and relieve its compression on the pancreatic vein. Experience in adult patients has shown that the use of small-diameter portacaval PTFE shunts (8–10 mm) reduces the risk of liver failure and hepatic encephalopathy supposedly by maintaining an appropriate hepatoportal flow [8,10].

Our rationale to implant a 10-mm-diameter prosthesis on a 10-kg infant was different. Indeed, we selected the largest prosthesis compatible with the splanchnic vein diameter to ensure that the shunt would remain effective as the child grows up. In this regard, the development of a mismatch between the fixed diameter of the prosthetic graft and the growing native vessels is a potential long-term problem. However, prosthetic grafts are widely used with good long-term outcome in pediatric cardiovascular surgery. Replacement of a hypoplastic thoracic aorta using a 14-mm-diameter straight prosthesis in a 3.5-year-old child allowed normal growth of the aorta after 11 years of follow-up [11]. Concerns about potential complications related to growth, thrombosis, and infection of prosthetic material have spawned a search for more biocompatible materials. Cryopreserved allografts are poorly suited because of immunogenicity with a high incidence of thrombosis related to antibody response [12,13]. A new generation of decellularized cryopreserved allografts with reduced antigen content is already in widespread use for the treatment of congenital heart disorders. Preliminary results indicate that they are well adapted to growing children with a lower risk of infection. Reduced immunogenicity also appears to promote long-term patency. Although their cost is high, decellularized allografts may offer a satisfactory alternative graft material. [14,15].

Conclusion

Thrombosis of portosystemic shunts is a major complication of the surgical treatment of PHT in infants even when performed in experienced centers. Six conventional procedures failed in a 5-kg baby despite skills and refinements in surgical techniques, as well as routine anticoagulation. Successful shunting was eventually

achieved by interposition of a 2-cm-long, 10-mm-diameter PTFE prosthesis between two newly formed 3-mm-diameter splanchnic veins and the IVC. This procedure allowed the infant to grow normally without rebleeding on a 10-year and 7-month follow-up. This case demonstrates that an aggressive surgical approach is mandatory as long as an even nonconventional surgical option is available to prevent life-threatening complications of PHT and improve quality of life.

Conflicts of interest

There are no conflicts of interest.

References

- Kim JH, Lee YS, Kim SH, Lee SK, Lim MK, Kim HS, *et al.* Does umbilical vein catheterization lead to portal venous thrombosis? Prospective US evaluation in 100 neonates. *Radiology* 2001; **219**:645–650.
- Schwartz DS, Gettner PA, Konstantino MM, Bartley CL, Keller MS, Ehrenkranz RA, Jacobs HC. Umbilical venous catheterization and the risk of portal vein thrombosis. *J Pediatr* 1997; **131**:760–762.
- Morag I, Epelman M, Daneman A, Moineddin R, Parvez B, Shechter T, Hellmann J. Portal vein thrombosis in the neonate: risk factors, course, and outcome. *J Pediatr* 2006; **148**:735–739.
- Sigalel DL, Mayer S, Blanchard H. Portal venous decompression with H-type mesocaval shunt using autologous vein graft: a North American experience. *J Pediatric Surg* 2001; **36**:91–96.
- Orloff MJ, Orloff MS, Rambotti M. Treatment of bleeding esophagogastric varices due to extrahepatic portal hypertension: results of portal-systemic shunts during 35 years. *J Pediatr Surg* 1994; **29**:142–154.
- Vila Carbo JJ, Ibanez V, Lluna J, Roca A, Genovés I, Garcia-Sala C, *et al.* Urgent distal splenorenal shunt in low-body weight patients. *Pediatr Surg Int* 2001; **17**:646–648.
- Adam R, Diamond T, Bismuth H. Partial portacaval shunt: renaissance of an old concept. *Surgery* 1992; **111**:610–616.
- He-jie H, Ge-liang X, Jian-sheng L, Shu-gao Y, Zhong-pei C, Rong-nan X. Small diameter prosthetic H-graft portocaval shunts in the treatment of portal hypertension. *Chin Med J* 2004; **117**:195–198.
- de Ville de Goyet J, Alberti D, Falchetti D, Rigamonti W, Matricardi L, Clapuyt P, Caccia G. Treatment of extrahepatic portal hypertension in children by mesenterico-to-left portal vein bypass: a new physiological procedure. *Eur J Surg* 1999; **165**:777–781.
- Shields R. Small diameter PTFE portosystemic shunts: portocaval vs mesocaval. *HPB Surg* 1998; **10**:413–414.
- Alexi-Meskishvili VV, Berger F. Eleven-year follow-up after descending thoracic aorta replacement in a small child. *Ann Thorac Surg* 2001; **71**:1006–1008.
- Darwish AA, Bourdeaux C, Kader HA, Janssen M, Sokal E, Lerut J, *et al.* Pediatric liver transplantation using left hepatic segments from living related donors: surgical experience in 100 recipients at Saint-Luc University Clinics. *Pediatr Transplantation* 2006; **10**:345–353.
- Breinholt 3rd JP, Hawkins JA, Lambert LM, Fuller TC, Profaizer T, Shaddy RE, *et al.* A prospective analysis of the immunogenicity of cryopreserved nonvalved allografts used in pediatric heart surgery. *Circulation* 2000; **102** (Suppl III): 179–182.
- Meyers RL, Lowichik A, Kraiss LW, Hawkins JA. Aortoiliac reconstruction in infants and toddlers: replacement with decellularized branched pulmonary artery allograft. *J Pediatr Surg* 2006; **41**:226–229.
- Burch PT, Kaza AK, Lambert LM, Holubkov R, Shaddy RE, Hawkins JA. Clinical performance of decellularized cryopreserved valved allografts compared with standard allografts in the right ventricular outflow tract. *The Annals of thoracic surgery* 2010; **90**:1301–1306.