

# The Penile Perception Score after distal hypospadias repair with tubularized incised plate and Mathieu

Abdullah Al-Debeiky, Hassan El-Tatawy, Mohamed Aboufarha, Tarek Gameel, Ahmed El-Sakka and Mohamed Taha

**Objective** The aim of this study was to evaluate the Penile Perception Score (PPS) after repair of distal penile hypospadias using tubularized incised plate (TIP) and Mathieu procedures.

**Methods** A randomized controlled study was conducted at urology department from October 2013 to May 2014. It included 60 children who were divided into three groups: group A included 20 patients with distal hypospadias corrected using TIP; group B included 20 patients with distal hypospadias corrected using Mathieu; and group C included 20 children with normal male genitalia who were circumcised and considered as a control group.

**Results** There were no statistically significant differences between group A and group B in urologists' and parents' average sum of PPS evaluation, but urologists' satisfaction was more than parents' satisfaction. The PPS for TIP was 8.43 and 7.80 for urologists and parents, respectively. The difference was significant. The PPS for Mathieu were 8.04 and 7.89 for urologists and parents, respectively, with no significance. There were no statistically significant differences between group A and group B in the

postoperative evaluation by urologists and by parents in meatus, glans, shaft skin, and general appearance. There were complications in 10% of cases from group A in the form of fistula, in 30% of cases from group B in the form of fistula in 25% and meatal stenosis in 5%, and no complication in group C.

**Conclusion** TIP showed better PPS score compared with Mathieu in hypospadias repair. However, the results of this study were not statistically significant. PPS was a good scale to evaluate hypospadias repair after surgery. *Ann Pediatr Surg* 14:31–35 © 2018 Annals of Pediatric Surgery.

*Annals of Pediatric Surgery* 2018, 14:31–35

**Keywords:** hypospadias, parents and urology, Penile Perception Score

Department of Urology, Tanta University, Tanta, Egypt

Correspondence to Ahmed El-Sakka, MD, Department of Urology, Tanta University, 31111 Tanta, Egypt

Tel: +20 120 422 2884; fax: +20 225 244 338; e-mail: zalabatta@gmail.com

Received 26 February 2017 accepted 5 April 2017

## Introduction

Hypospadias is a condition in which the urethral meatus is present on the ventral surface of the penis due to improper development of the penile shaft; it is thought to be improper sex differentiation, and it can be located from glans penis until the urethral groove [1].

Over 150 years, around 300 surgical procedures have been discovered to treat hypospadias; these procedures were simple and performed in a single main step to decrease complications and provide good cosmetic appearance in a condition in which around 65% of the cases had the hypospadiac meatus located in the glandular, subcoronal, or distal shaft position with minimal chordee [2].

There have been many techniques for the surgical correction of this problem (e.g. Mathieu repair, transverse preputial island flap (Duckett procedure), meatal advancement and glanduloplasty and Thiersch–Duplay technique). Tubularized incised plate urethroplasty (TIP or Snodgrass procedure) was a modification of the latter first introduced in 1994 for distal hypospadias depending on the concept of hinging the incised urethral plate [3].

TIP is used for the correction of distal hypospadias with minimal chordee by tubularizing the urethral plate through deep longitudinal incision of the plate without the need for additional flaps [3].

Perimeatal-based flap urethroplasty (Mathieu) is used commonly for the primary correction of distal hypospadias

with satisfactory cosmetic results, with the risk for devascularization of the neourethral flap [4].

Assessment of the result of hypospadias surgery by the lack of complications such as fistula was not completely sufficient [5].

Weber *et al.* [6,7] studied seventy-seven boys who underwent hypospadias repair and were between 6 and 17 years of age, and they had an interview with a psychologist with a standardized questionnaire asking about their penile self-perception, including the following items: meatus, glans, skin, and general appearance. The pediatric Penile Perception Score (PPS) was calculated, consisting of the sum of these four items, and the study proved that pediatric PPS is a significant self-assessment test for repair and for appraisal for surgical procedures used for correcting hypospadias.

Many groups have attempted to objectively assess the surgical outcome of hypospadias repair [8–10].

The main goal of this study was to evaluate the applicability of the PPS after repair of distal penile hypospadias using TIP and Mathieu procedures.

## Methods

In the study, 60 participants were enrolled after obtaining approval from the Ethics Committee of the Faculty of Medicine, Tanta University. Informed consent was obtained from parents of all participants.

### Selection criteria

Children with distal hypospadias aged between 2 and 10 years old were included in this study, whereas children with proximal hypospadias, or those with other signs of sexual development disorders besides hypospadias, and children with previous repair were excluded.

This was a randomized prospective controlled study including 60 children (40 children with distal hypospadias treated with surgery and 20 children with normally circumcised penis) at the Urology Department, Tanta University Hospital from October 2013 to May 2014.

Group A included 20 patients with distal hypospadias who were corrected using TIP.

Group B included 20 patients with distal hypospadias who were corrected using Mathieu.

Group C included 20 patients with normal male genitalia who were circumcised and served as a control group.

A detailed personal and family history was taken, asking about a similar condition in the father and/or siblings and complaints from the parents such as abnormal direction of the urinary stream of the child. Further, we asked about any associated congenital anomaly and any previous trials for repair.

A general examination was carried out to discover any associated congenital anomalies, followed by local examination that included examination of the penis (initial examination in the outpatient clinic and later examination under anesthesia). Shape of the penis and prepuce, presence of chordae or rotation, the condition of nearby skin, position and size of the meatus, and other associated anomalies such as undescended testis were reported.

After 2 months all children had undergone urological examination, and then four standardized views were photographed of the nonerect penis, including an anteroposterior and an oblique view, and two images of the penis held so that the meatus and the ventral side of the penis were visible.

The children's parents were asked to complete the PPS to express satisfaction with four items referring to their child's penis.

Thereafter, questionnaires were printed for 10 urologists at Tanta University to evaluate the appearance of the penis using the PPS. They were not aware of the identity and the repair carried out for each individual child.

The evaluation included the meatal position and shape, glans shape, shaft skin shape, and general penile appearance, according to a four-point Likert scale as shown in Table 1.

The PPS was calculated by adding the scores of all four items for a range of a minimum of 0 to a maximum of 12.

The mean PPS of urologists in each group was measured and compared with each other. The mean PPS of parents in each group was measured and compared with each other.

Finally, the mean PPS for urologists was compared with the mean PPS of parents for each group.

### Statistical analyses

The *t*-test was used to test agreement in penile perception between patients and urologist and evaluate the applicability of the PPS after repair of distal penile hypospadias using TIP and Mathieu procedures. All tests were performed on the 5% level of significance.

The primary objective was to evaluate the applicability of the PPS after repair of distal penile hypospadias using TIP and Mathieu procedures. In a previous study [6], there was a difference in mean between the two groups of about 1.4 and SD of 1.8; the *P*-value was more than 0.05 between the two groups.

A sample size of 60 participants (2:1), 40 in the experimental group (TIP and Mathieu) and 20 in the control group at confidence level 95% ( $\alpha$  error = 5%) would give a study power of 80% ( $\beta$  error = 20%).

### Results

The age of children ranged between 2 and 10 years with a mean age of  $3.36 \pm 1.15$  years.

To comply with the objective of the study in the three groups of patients we have evaluated the following:

#### Postoperative evaluation by urologists

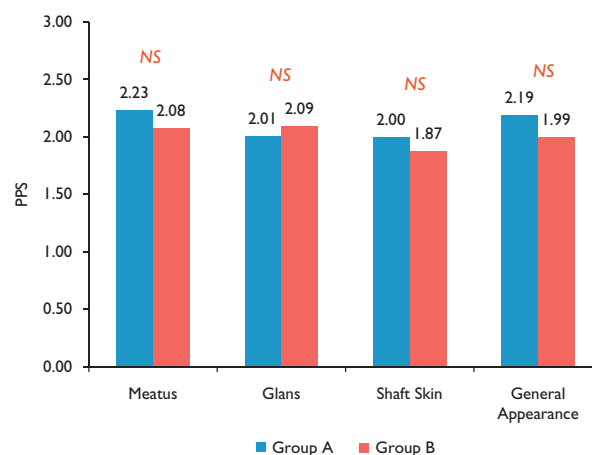
Figure 1.

- (1) Meatus: The average of meatus evaluation was 2.23 (0.51) in group A and 2.07 (0.72) in group B with a nonsignificant difference ( $P > 0.05$ ).

Table 1 Likert scale

Scale	Penile appearance
0 points	Very dissatisfied
1 points	Dissatisfied
2 points	Satisfied
3 points	Very satisfied

Fig. 1



Postoperative evaluation by the urologists in the three groups. PPS, Penile Perception Score.

- (2) Glans: The average of glans evaluation was 2.01 (0.52) in group A and 2.00 (0.53) in group B with a nonsignificant difference ( $P > 0.05$ ).
- (3) Shaft skin: The average of shaft skin evaluation was 2.00 (0.66) in group A and 1.80 (0.72) in group B with a nonsignificant difference ( $P > 0.05$ ).
- (4) General appearance: The average of general appearance evaluation was 2.19 (0.49) in group A and 1.90 (0.53) in group B with a nonsignificant difference ( $P > 0.05$ ).

**Postoperative evaluation by parents**

Figure 2.

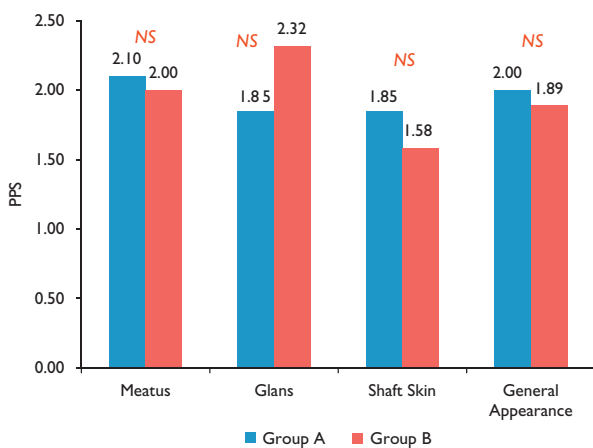
- (1) Meatus: As regards the meatus, the average of meatus evaluation was 2.1 (0.55) in group A and 2 (0.88) in group B. This study showed a nonsignificant difference ( $P > 0.05$ ).
- (2) Glans: As regards the glans, the average of glans evaluation was 1.85 (0.59) in group A and 2.31 (0.58) in group B. This study showed a nonsignificant difference ( $P > 0.05$ ).
- (3) Shaft skin: As regards the shaft skin, the average of shaft skin evaluation was 1.8 in group A and 1.5 in group B. This study showed a nonsignificant difference ( $P > 0.05$ ).
- (4) General appearance: As regards the general appearance, the average of general appearance evaluation was 2 (0.59) in group A and 1.89 (0.77) in group B. This study showed a nonsignificant difference ( $P > 0.05$ ).

**Penile Perception Score sum**

Figure 3.

The urologists average sum of PPS was 8.43 (1.90) in group A and 8.04 (2.16) in group B with a nonsignificant difference ( $P > 0.05$ ). The parents' average sum of PPS was 7.8 (1.51) in group A and 7.89 (2.21) in group B with a nonsignificant difference ( $P > 0.05$ ). Therefore, it was clear that urologists' satisfaction was greater than parents' satisfaction.

Fig. 2



Postoperative evaluation by the parents in the three groups. PPS, Penile Perception Score.

On comparing PPS between urologists and parents, the PPS for TIP was 8.43 and 7.80 for urologists and parents, respectively. The difference was significant [ $P = 0.03 (< 0.05)$ ]. The PPS for Mathieu were 8.04 and 7.89 for urologists and parents, respectively. The difference was not significant [ $P = 0.47 (> 0.05)$ ].

**Postoperative complications**

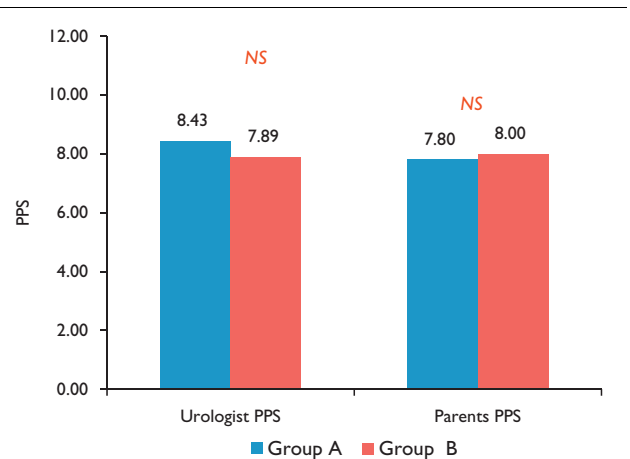
Figure 4.

As regards postoperative complications, this study showed complication in two (10%) children from group A in the form of fistula, in six (30%) children from group B in the form of fistula in five (25%) children and meatal stenosis in one (5%) child, and no complication in group C.

**Group C results**

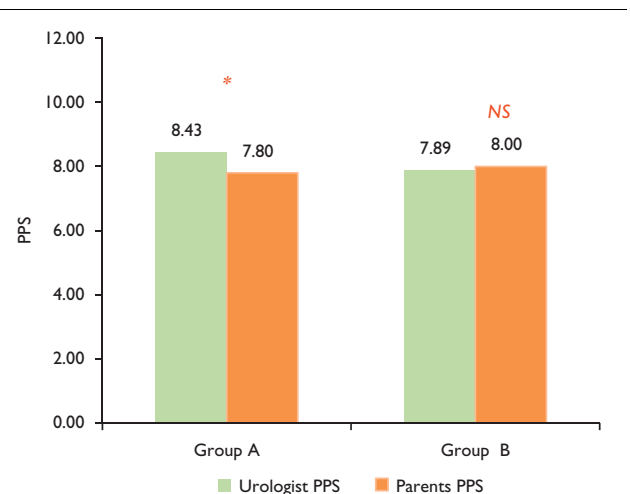
As group C included normally circumcised patients, it received 3 (very satisfied) in all parents and physician evaluations, and it showed no postoperative complications.

Fig. 3



Group A versus group B sum PPS. PPS, Penile Perception Score.

Fig. 4



Urologists versus parents sum PPS. PPS, Penile Perception Score.

## Discussion

This study involved 60 children and all of them were reviewed 2 months after surgery.

Weber *et al.* [6,7] conducted a study on a pediatric group, which included 56 patients with age ranging from 6 to 17 years. A total of 48 patients had distal hypospadias, 26 had penile hypospadias, and three had penoscrotal hypospadias. They studied children operated on for inguinal hernias at the same age at their institution as a control group.

In this study 10 urologists and children's parents were asked to complete the PPS to express satisfaction. Meanwhile, Weber *et al.* [6,7] on their pediatric study reported on six urologists, children, and parents who were asked to complete the PPS to express satisfaction.

In this study, the urologists were mostly satisfied with the results of both groups studied (group A treated with TIP and group B treated with Mathieu) with a nonsignificant difference. The mean PPS was 8.43 in group A and 8.04 in group B. However, parents were mostly satisfied with the results of their children in both groups with a nonsignificant difference. The mean PPS 7.8 in group A and 7.89 in group B.

However, Weber *et al.* [6,7] in their pediatric study showed that urologists were satisfied with the results; the mean PPS was 6.76. Further, parents were satisfied with their children's results, with a mean PPS of 8.54, and patients were mostly satisfied with their results, with a mean PPS of 9.75. Despite an overall high satisfaction reported by patients, young age is associated with higher PPS.

This might be due to a higher expectation of patients as regards their penile appearance during adolescence, and genital self-perception by patients decrease with advancing age.

In this study, comparison of parents' perception and urologists' PPS results revealed slightly more positive results by urologists for each group.

However, Weber *et al.* [6,7] in their pediatric study showed more positive results by patients and parents.

This might be related to the inferior results of hypospadias repair in their center when compared with other centers. However, as Bracka [11] has indicated, the treating surgeon was always confused when judging his or her own work, and current surgical techniques may affect the judgment once one was committed to a certain method of treatment.

Mureau *et al.* [12] published a survey on patient satisfaction after hypospadias repair surgery with a similar study design and discovered that patients were less satisfied with the penile appearance than were the performing surgeons.

Snodgrass *et al.* [10] reported a standardized questionnaire to both parents and operating surgeons to determine their opinions as regards the outcomes from the TIP hypospadias repair.

The results of Snodgrass *et al.* [10] are in accordance with this study as both the surgeon and parents were mostly satisfied and the surgeon was slightly more satisfied.

Ververidis *et al.* [8] reported an objective assessment of the results of hypospadias surgery. They reported a panel of five health professionals assessing the photographs of the penis after hypospadias repair surgery. They have used different forms of repair. The aspects of penile appearance that were assessed were the meatus, glans, shaft, and overall appearance.

Comparison of their results with this study result is difficult. They assessed the same items as in the present study, but they did not consider the patients' and parents' opinion. This may be attributed to the fact that they needed to compare the cosmetic results of various forms of repair.

In this study, as regards the postoperative complications, this study showed complications in two (11%) children from group A in the form of fistula and in six (30%) children from group B in the form of fistula in five (25%) children and a meatal stenosis in one (5%) child.

Similar to this study, Ververidis *et al.* [8], Merriman *et al.* [13], and Holland *et al.* [9] reported postoperative complications. However, Snodgrass *et al.* [10] reported no complications. This might be related to the level of surgeon experience.

As regards our recommendations, studies about hypospadias repair must always assess complications and include a measure for appearance, such as the PPS. Preoperative evaluation of the hypospadias should be carried out to compare the results of repair surgery.

Further parameters may be included, such as uroflow measurement, penile straightness upon erection, penile size, and erectile function.

## Conclusion

TIP showed better PPS scores compared with Mathieu in hypospadias repair. However, the results of this study were not statistically significant. PPS was a good scale to evaluate hypospadias repair after surgery. The authors recommended conducting a multicenter clinical trial on a larger number of patients to evaluate different types of surgery in hypospadias repair.

## Conflicts of interest

There are no conflicts of interest.

## References

- 1 Kissane JM. Hypospadias. In: Kissane JM, Anderson WAD, editors. *Anderson's pathology*, 8th ed. Philadelphia, USA: Mosby Year book; 1990. p. 393.
- 2 Duckett JW. Hypospadias. In: Walsh PC, Gittes RF, Perlmutter AD, Stancy TA, editors. *Campbell's urology*, 6th ed. Philadelphia, PA: W.B. Saunders Co.; 1992. p. 1893.
- 3 Snodgrass W. Tubularized, incised plate urethroplasty for distal hypospadias. *J Urol* 1994; **151**:464–465.
- 4 Kiss A, Nyirady P, Piro L, Merksz M. Combined use of perimeatal-based flap urethroplasty (Mathieu) with midline incision or urethral plate in hypospadias repair. *Eur J Pediatr Surg* 2003; **13**:383–385.
- 5 Kurzrock EA. How do we measure hypospadias outcomes? *J Urol* 2008; **180**:808.
- 6 Weber DM, Schonbucher VB, Landolt MA, Gobet R. The Pediatric Penile Perception Score: an instrument for patient self-assessment and surgeon evaluation after hypospadias repair. *J Urol* 2008; **180**:1080–1084.
- 7 Weber DM, Landolt MA, Gobet R, Kalisch M, Greeff NK. The Penile Perception Score: an instrument enabling evaluation by surgeons and patient self-assessment after hypospadias repair. *J Urol* 2013; **89**:189–193.

- 8 Ververidis M, Dickson AP, Gough DC. An objective assessment of the results of hypospadias surgery. *BJU Int* 2005; **96**:135–139.
- 9 Holland AJ, Smith GH, Ross FI, Cass DT. HOSE an objective scoring system for evaluating the results of hypospadias surgery. *BJU Int* 2001; **88**:255–258.
- 10 Snodgrass W, Ziada A, Yucel S, Gupta A. Comparison of outcomes of tubularized incised plate hypospadias repair and circumcision: a questionnaire based survey of parents and surgeon. *J Pediatr Urol* 2008; **4**:250–254.
- 11 Bracka A. Sexuality after hypospadias repair. *BJU Int* 1999; **83**:29–33.
- 12 Mureau MA, Froukje ME, Slob A, Verhulst FC, Nijman RJ. Satisfaction with penile appearance after hypospadias surgery. The patient and surgeon view. *Urology* 1996; **155**:703–706.
- 13 Merriman LS, Arlen AM, Broecker BH, Smith EA, Kirsch AJ, Elmore JM. The GMS hypospadias score: assessment of inter-observer reliability and correlation with post-operative complications. *J Pediatr Urol* 2013; **9**:707–712.