

A paratubal cyst associated with flegmonous appendicitis: a case report and review of literature

Volkan S. Erikci^a, Demet Payza^a, Malik Ergin^b and Münevver Hoşgör^a

Paratubal cysts (PTCs) are rare clinical entities and are believed to originate from the mesothelium or to be a remnant of Mullerian duct and Wolffian duct. These masses have been reported in all age groups, beginning from the premenarchial period up to menopause, and are mostly benign. A 14-year-old girl with flegmonous appendicitis diagnosed and treated during the management of PTC is presented. This report shows that PTC and flegmonous appendicitis can be seen together as distinct entities in children. *Ann Pediatr Surg* 13:101–103 © 2017 Annals of Pediatric Surgery.

Introduction

Paratubal cysts (PTCs) are remnants of paramesonephric or mesonephric ducts [1]. Paraovarian and PTCs are used synonymously [2]. These masses have been reported in all age groups, beginning from the premenarchial period up to menopause [2], but most commonly are seen in the third and fourth decades of life [3]. PTCs are mostly benign. A case of flegmonous appendicitis diagnosed and treated during the management of PTC is presented and discussed.

Case report

A 14-year-old girl had signs of acute surgical abdomen. All laboratory parameters were normal, except an increase in white blood cell count (16 300/ μ l). In addition to a normally perfused left ovary with multiple little cysts, a Pelvic Doppler ultrasonography demonstrated a cystic mass adjacent to the right ovary with a dimension of 60 × 50 × 40 mm with no perfusion. The cyst was found to be unilocular with no solid components or septations. The right ovary was not visible by ultrasonography (US). The abdominal MRI revealed a unilocular cystic mass with no septation or mural nodule with a dimension of 64 × 54 × 43 mm consistent with a PTC (Fig. 1). With a suspicion of torsion of the ovarian pedicle or the fallopian tube accompanied by a PTC, the patient underwent an emergent exploration. Laparotomy by Pfannenstiel incision revealed that both fallopian tubes and ovaries were normal. A mass of 6 × 5 cm in diameter between the left fallopian tube and the left ovary was found and enucleated, totally preserving the adjacent ovary and fallopian tube (Figs 2 and 3). Synchronous abdominal exploration also revealed an inflamed appendix (Fig. 4). Standard appendectomy was added to the procedure. Histopathology revealed a flegmonous appendicitis and a PTC with a smooth inner surface with a thin wall (1 mm). The patient had an uneventful postoperative course.

Discussion

PTCs are rare clinical entities and are believed to originate from the mesothelium or to be a remnant of

Annals of Pediatric Surgery 2017, 13:101–103

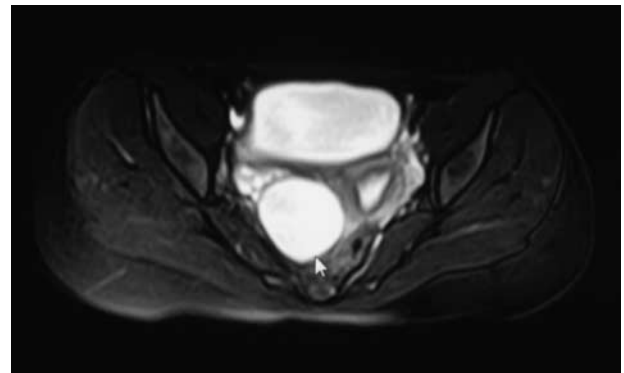
Keywords: children, flegmonous appendicitis, paratubal cyst

Departments of ^aPediatric Surgery and ^bPathology, Dr Behçet Uz Children's Hospital, İzmir, Turkey

Correspondence to Volkan Sarper Erikci, MD, Department of Pediatric Surgery, Süvari cad. Babadan apt. No. 34 D.6, Bornova, İzmir 35100, Turkey
Tel: +90 542 4372747; fax: +90 232 4892315; e-mail: verikci@yahoo.com

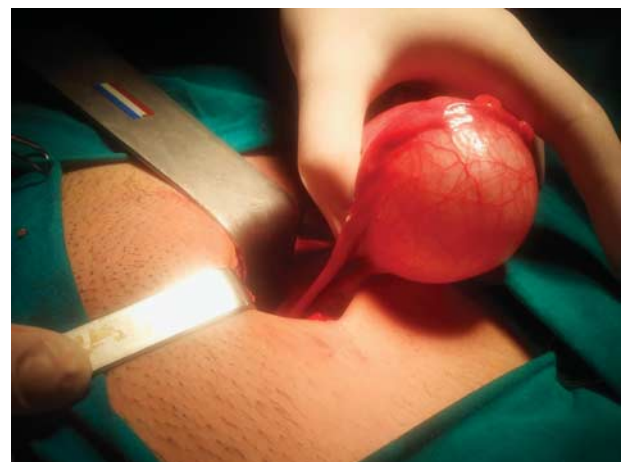
Received 5 April 2016 accepted 22 June 2016

Fig. 1



MRI view: contrast enhanced view showing a unilocular cystic mass (arrow).

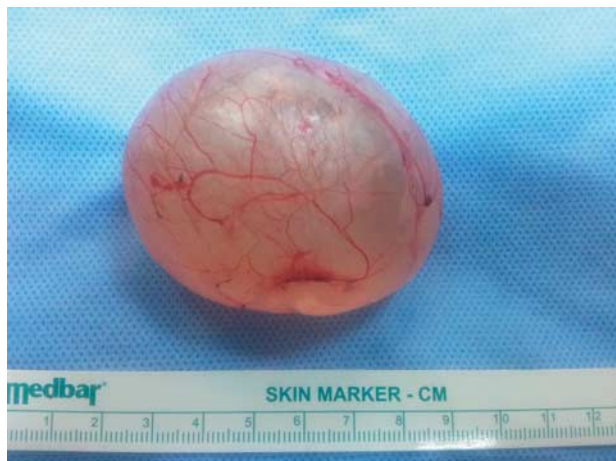Fig. 2



Intraoperative view of the PTC.

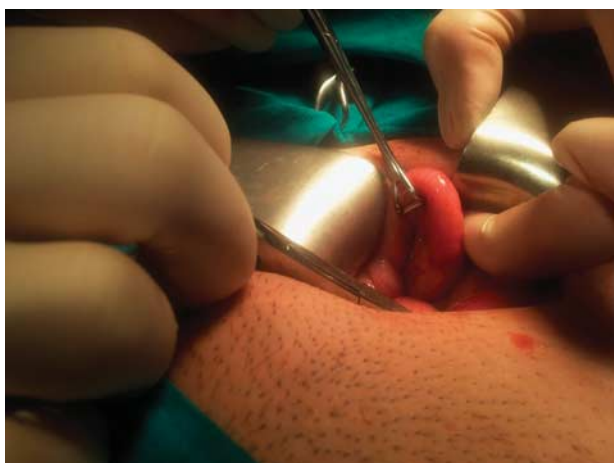the Mullerian duct and Wolffian duct [1]. Although the term paraovarian cyst is also used, generally, the terminology depends on the location of the cyst. When

Fig. 3



PTC after enucleation.

Fig. 4



Appendix vermiformis. Note distal tip is inflamed revealing flegmonous appendicitis.

adjacent to fallopian tubes it is referred to as PTC. Most reported cases of PTCs have occurred in pediatric patients [4]. It has been hypothesized that PTCs increase in size with hormonal activity [5]. Larger lesions may become symptomatic, causing pressure or pain. An association between PTCs and obesity has been suggested [6]. Our case was not considered to be obese and she was in the normal range for weight and height percentile. PTCs usually consist of either unciliated epithelium, ciliated cuboidal epithelium, or ciliated columnar epithelium [7,8]. Inside the cyst in our case there was serous fluid and the epithelium was of ciliated columnar type.

US, computed tomography, or MRI may be performed in preoperative evaluation. Sonographically, a PTC is unilocular, with serous fluid inside, without internal echoes, and has a smooth wall [9]. Because of the possibility that ovarian torsion may be one of the differential diagnoses as well, Pelvic Doppler ultrasonography was performed in

our patient. A unilocular cystic mass with no solid components or septations adjacent to the right fallopian tube was observed and there was no blood perfusion. The right ovary was not visible by US. Computed tomography or MRI may also be performed in the diagnostic workup in these patients. MRI findings of these paramesonephric or mesonephric remnants have been rarely reported [10]. It has been suggested that demonstration of a normal ipsilateral ovary close to, but separated from, the adnexal cyst may be an important MRI finding for the diagnosis of paraovarian cyst. MRI finding in our case was a large unilocular cystic mass at the level of the right ovary (Fig. 1). US and MRI findings in these patients are nonspecific and none of these imaging techniques have specific criteria for a definite diagnosis.

Treatment options for PTCs include cystectomy, fenestration of the cyst, and aspiration of cyst fluid [11]. Enucleation of the PTC with an attempt at tubo-ovarian salvage should be considered. Preservation of fallopian tubes and ovary during excision of the cyst may increase the future reproductive potential of these patients in general. Enucleation of the PTC was performed uneventfully in our patient. At the end of the operation abdominal exploration through the same incision revealed a striking finding: an inflamed flegmonous appendicitis. Standard appendectomy was added to the surgical procedure.

Literature review of the association of appendicitis with other pelvic pathologies shows only adult cases and include various pelvic pathologies. These are tubal pregnancy [12–16], ovarian cyst [17], hemorrhagic corpus luteal cyst [18], and bleeding ovarian follicle with hemoperitoneum [19]. Parovarian cyst torsion including rupture of the left ovary associated with flegmonous appendicitis has also been reported [20]. The association of appendicitis with pediatric pelvic pathologies includes mostly ovarian torsion and there are seven pediatric cases of ovarian torsion associated with appendicitis [21]. A case of suppurative salpingitis associated with flegmonous appendicitis has also been reported in an 11-year-old girl [22]. When PTC and acute appendicitis coexist in a same patient, it may not be evident as to which one is the primary event. In our case it appears that PTC with its huge volume full of serous fluid around the appendix may produce local irritation and later on may have contributed to appendicitis. Therefore, we suppose that PTC in our case occurred first and distal appendicitis second. To our knowledge, there is no pediatric case of PTC associated with a flegmonous appendicitis in the English language literature.

Physicians hesitate to accept the possibility of double pathology in the same patient. This reluctance stems from an experience that it is rare for two coincident pathological conditions to occur simultaneously. This case shows the importance of considering multiple pathologic disorders in a patient with an acute surgical abdomen. To our knowledge, this is the second report of a combination of PTC and flegmonous appendicitis and the first pediatric case. As shown in this case, PTC and

flegmonous appendicitis can be seen together as distinct entities in children.

Conflicts of interest

There are no conflicts of interest.

References

- 1 Stenbäck F, Kauppila A. Development and classification of parovarian cysts. An ultrastructural study. *Gynecol Obstet Invest* 1981; **12**:1–10.
- 2 Kiseli M, Caglar GS, Cengiz SD, Karadag D, Yilmaz MB. Clinical diagnosis and complications of paratubal cysts: review of the literature and report of uncommon presentations. *Arch Gynecol Obstet* 2012; **285**:1563–1569.
- 3 Pepe F, Panella M, Pepe G, Panella P. Paraovarian tumors. *Eur J Gynaecol Oncol* 1986; **7**:159–161.
- 4 Chauhan S, Blacker C. Paratubal cyst: a case report. *W V Med J* 2005; **101**:176.
- 5 Devouassoux-Shisheboran M, Silver SA, Tavassoli FA. Wolffian adnexal tumor, so-called female adnexal tumor of probable Wolffian origin (FATWO): immunohistochemical evidence in support of a Wolffian origin. *Hum Pathol* 1999; **30**:856–863.
- 6 Muolokwu E, Sanchez J, Bercaw JL, Sangi-Haghpeykar H, Banszek T, Brandt ML, Dietrich JE. Paratubal cysts, obesity, and hyperandrogenism. *J Pediatr Surg* 2011; **46**:2164–2167.
- 7 Samaha M, Woodruff JD. Paratubal cysts: frequency, histogenesis, and associated clinical features. *Obstet Gynecol* 1985; **65**:691–694.
- 8 Drews U. Hepler function of the Wolffian ducts and role of androgens in the development of vagina. *Sex Dev* 2007; **1**:100–110.
- 9 Hasuo Y, Higashijima T, Mitamura T. Torsion of parovarian cyst. *Kurume Med J* 1991; **38**:39–43.
- 10 Kishimoto K, Ito K, Awaya H, Matsunaga N, Outwater EK, Siegelman ES. Paraovarian cyst: MR imaging findings. *Abdom Imaging* 2022; **27**: 685–689.
- 11 Seçkin B, Özdener T, Tapisiz ÖL, Batioğlu S. Laparoscopic treatment of ovarian cysts in adolescents and young adults. *J Pediatr Adolesc Gynecol* 2011; **24**:300–303.
- 12 Allan NJ, Heringer R. Coincident acute appendicitis and tubal pregnancy. *Can Med Assoc J* 1970; **103**:531.
- 13 Hazebroek EJ, Boonstra O, van der Harst E. Concurrent tubal ectopic pregnancy and acute appendicitis. *J Minim Invasive Gynecol* 2008; **15**:97–98.
- 14 Kononski AD. Acute appendicitis associated with tubal pregnancy [in Ukrainian]. *Pediatr Akus Ginekol* 1967; **5**:65.
- 15 Pelosi MA, Apuzzio J, Iffy L. Ectopic pregnancy as an etiologic agent in appendicitis. *Obstet Gynecol* 1979; **53** (Suppl 3):4S–6S.
- 16 Mathelier AC. Tubal pregnancy coexisting with retrocecal gangrenous appendicitis. A case report. *J Reprod Med* 1983; **28**:45–46.
- 17 Gavrilenko BG, Chernyshenko GA, Chernega VI. Destructive appendicitis in combination with torsion of a left ovarian cyst [in Russian]. *Klin Khir* 1985; **4**:65–66.
- 18 Neinstein LS, Braud BJ. Coincident acute appendicitis and hemorrhagic corpus luteal cyst. *J Adolesc Health Care* 1984; **5**:137–138.
- 19 Rabinovitch J, Rabinovitch P. Coexisting acute appendicitis and bleeding ovarian follicle with hemoperitoneum. *AMA Arch Surg* 1955; **71**:178–184.
- 20 Nikolaev V. Phlegmonous appendicitis in association with a twisted left parovarian cyst and rupture of the left ovary. *Vestn Khir Im II Grek* 1971; **106**:141.
- 21 Hoey BA, Stawicki SP, Hoff WS, Veeramasuneni RK, Kovich H, Grossman MD. Ovarian torsion associated with appendicitis in a 5-year-old girl: a case report and review of the literature. *J Pediatr Surg* 2005; **40**:e17–e20.
- 22 Nikulin VG, Vesnin VA. Right-side suppurative salpingitis and secondary acute phlegmonous appendicitis in an 11-year-old girl [in Russian]. *Klin Khir* 1990; **6**:62–63.