

# Fibroadenoma of ectopic breast tissue of the axilla in an adolescent girl: report of a rare entity

Engin Yilmaz<sup>a</sup>, Çagatay E. Afsarlar<sup>a</sup>, Saynur Yilmaz<sup>c</sup> and Nilüfer Arda<sup>b</sup>

**Ectopic breast tissue (EBT) is a well-described entity in the English literature. However, fibroadenoma of the ectopic breast is a rare entity. We present a case of a 13-year-old adolescent girl with a subcutaneous mass in the right axilla that was pathologically identical to fibroadenoma seen in the EBT. To our knowledge, this is the second youngest patient reported with axillary EBT, which should be considered as a part of the differential diagnosis for axillary masses. *Ann Pediatr Surg* 13:99–100 © 2017 Annals of Pediatric Surgery.**

*Annals of Pediatric Surgery* 2017, 13:99–100

## Introduction

Ectopic breast tissue (EBT) is a relatively common and well-described entity in the English literature. The incidence varies between 0.22 and 6% depending on the geographical area, ethnic group, and sex. This anomaly may occur anywhere along the mammary line from the axilla to the pubic region or in other sites such as the neck, upper arm, shoulder, intra-areolar region, back, thigh, vulva, etc. Its diagnosis has significant importance, because it has risk for the same pathological challenges as do the naturally positioned breasts [1–6].

Fibroadenomas are the most common benign neoplasms of the breast and generally appear as well-circumscribed, painless masses in young women [7]. However, fibroadenoma of the EBT is an extremely rare condition among young women, especially in the pediatric age group [5,8].

We present the case of a 13-year-old adolescent girl with a right axillary subcutaneous mass that was identical to fibroadenoma of normal breast tissue on histopathological examination.

## Case report

A 13-year-old adolescent girl complaining of a right axillary mass causing mild local pain and discomfort was referred to our pediatric surgery clinic from the pediatric infection diseases clinic to determine whether she had a complicated axillary abscess. She had been diagnosed with axillary lymphadenitis, which did not improve with antibiotic treatment, and the size of the mass did not change during the follow-up. Her menarche and thelarche started at 12 years of age, and she did not have a family history relevant to breast cancer or polymastia.

The physical examination revealed a subcutaneous 3 × 4 × 3 cm firm, mobile, and painless right axillary mass, which did not have impression of an extension to the right breast tissue. Examination of the contralateral axilla and neck was normal, and other parts of her body did not show any similar pathology. Ultrasound imaging demonstrated multiple hypoechoic lesions suggestive of

**Keywords:** adolescent, axilla, ectopic breast tissue, fibroadenoma, mass

Departments of <sup>a</sup>Pediatric Surgery, <sup>b</sup>Pathology, Sami Ulus Maternity and Children's Hospital and <sup>c</sup>Department of Reproductive Endocrinology, Zubeyde Hanım Women Health Hospital, Ankara, Turkey

Correspondence to Engin Yilmaz, MD, Pediatric Surgery Specialist, Department Of Pediatric Surgery, Dr. Sami Ulus Maternity and Children's Hospital, Babur St, 44 06010-Altındağ, Ankara, Turkey  
Tel: +90 312 305 62 08; fax: +90 312 317 03 53;  
e-mail: cocukcerrahisi@hotmail.com

Received 1 September 2015 accepted 22 June 2016

the multiple lymph nodes on the right axilla, and a clearly circumscribed, superficial, homogenous, solid mass, measuring 37 × 28 mm in diameter was observed. On Doppler ultrasound, the mass was seen to have obvious blood flow both in the central and peripheral regions.

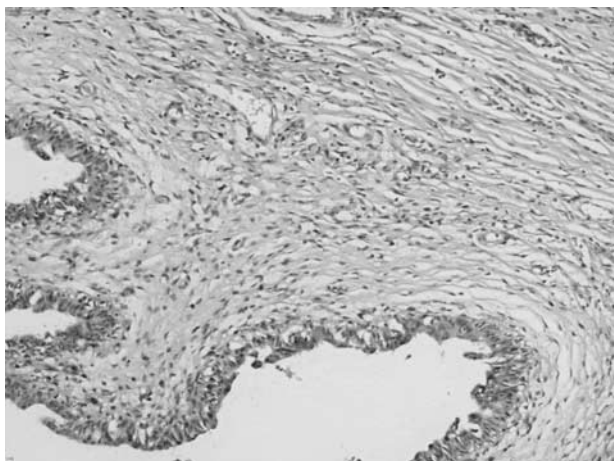
Consequently, surgical exploration of the mass was justified. Following a right axillary transverse skin incision overlying the mass, complete excision of the mass was performed. The macroscopic appearance of the specimen showed a smooth and glistening mass measuring 4 × 3 × 3 cm, and the cut surface demonstrated whitish multiple lobulations on histopathologic examination. The pathologic diagnosis was fibroadenoma of ectopic breast of the axilla (Figs 1 and 2). The postoperative period of the patient was uneventful.

## Discussion

There is a broad spectrum of diagnoses that should be considered in the differential diagnosis of a solitary axillary mass, such as infectious lymphadenopathy, vascular lesions, benign cutaneous or subcutaneous tumors, primary malignancies, as well as EBT or a torn muscle belly [6]. The differential diagnosis of EBT is important because it is under the same hormonal stimuli as the normally localized pectoral breast tissue. Therefore, EBT responds to hormonal stimuli with similar tissue changes and has the risk of developing various breast diseases. During menses or pregnancy, hormonal stimulation may cause EBT enlargement and axillary discomfort [4,5,9].

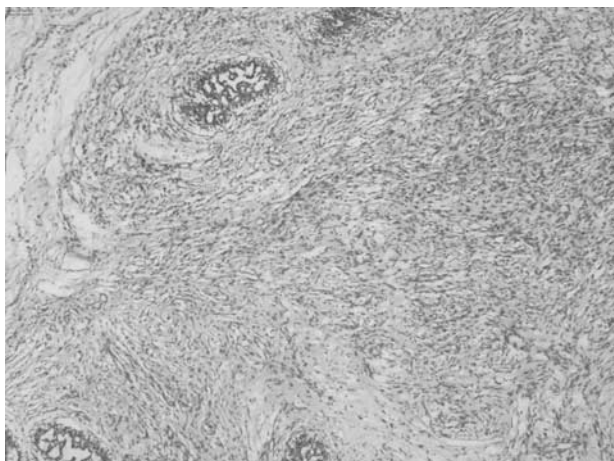
Fibroadenoma is a frequent cause of breast nodules among young women, with the highest incidence at 20–30 years of age [7]. Although the incidence of fibroadenoma of the breast is high, only a few cases of fibroadenoma of EBT in the axilla among young women under 30 have been reported in the literature [5,6,9]. Furthermore, only two cases have been reported among young women under 20 in the English literature. Borsook *et al.* [8] and Mukhopadhyay *et al.* [10] reported a similar

Fig. 1



Dilated ductus structures (hematoxylin eosin stain; 20 × 10 original magnification).

Fig. 2



Histologic appearance of the myxomatous stroma (hematoxylin eosin stain; 20 × 10 original magnification).

case in a 17-year-old girl and a 10-year-old-girl, respectively. To our knowledge, our case is the second youngest patient with fibroadenoma of the EBT until now.

Also malignant tumors may originate from the EBT. Ahmed *et al.* [4] have described infiltrating ductal carcinoma that developed within the EBT in a 30-year-old woman. For this reason, excision of the EBT is crucial whenever it is recognized.

In addition, an association between breast development anomalies and urogenital malformations has been described [2,6]. An attempt has been made to correlate this association to the parallel embryologic development of the mammary and the urogenital system [6]. The presented case in this paper did not have any urogenital system abnormality. Although it is not crucial, evaluation of urogenital system abnormalities should be considered in patients with EBT.

### Conclusion

Whenever a mass has been identified along the mammary line, particularly in the axilla, presence of EBT and its consequences such as a fibroadenoma should be considered in the differential diagnosis in the pediatric age group. To prevent latter complications, excision of the mass is the treatment of choice.

### Conflicts of interest

There are no conflicts of interest.

### References

- 1 Famà F, gioffrè Florio MA, Villari SA, Caruso R, Barresi V, Mazzei S, *et al.* Breast abnormalities: a retrospective study of 208 patients. *Chir Ital* 2007; **59**:499–506.
- 2 Ferrara P, Giorgio V, Vitelli O, Gatto A, Romano V, del Bufalo F, Nicoletti A. Polythelia: still a marker of urinary tract anomalies in children? *Scand J Urol Nephrol* 2009; **43**:47–50.
- 3 Köse R, Ozgoönül A, Bingöl I. Intraareolar polythelia: a rare anomaly. *J Pak Med Assoc* 2012; **62**:499–500.
- 4 Ahmed M, Aurangzeb PA, Pervez A, Kamal Z, Younas A. Primary carcinoma of ectopic breast tissue in axilla. *J Coll Physicians Surg Pak* 2012; **22**: 726–727.
- 5 Singh S, Bhargava A. Axillary fibroadenoma: case report and review of literature. *Saudi J Med Med Sci* 2014; **2**:207–209.
- 6 Coras B, Landthaler M, Hofstaedter F, Meisel C, Hohenleutner U. Fibroadenoma of the axilla. *Dermatol Surg* 2005; **31** (Pt 1):1152–1154.
- 7 Siddiqui MS, Kayani N, Gill MS, Pervez S, Muzaffar S, Aziz SA, *et al.* Breast diseases: a histopathological analysis of 3279 cases at a tertiary care center in Pakistan. *J Pak Med Assoc* 2003; **53**:94–97.
- 8 Borsook J, Thorner PS, Grant R, Langer JC. Juvenile fibroadenoma arising in ectopic breast tissue presenting as an axillary mass. *J Pediatr Surg Case Rep* 2013; **1**:359–361.
- 9 Ciralik H, Bulbuloglu E, Arican O, Cital R. Fibroadenoma of the ectopic breast of the axilla – a case report. *Pol J Pathol* 2006; **57**:209–211.
- 10 Mukhopadhyay M, Saha AK, Sarkar A. Fibroadenoma of the ectopic breast of the axilla. *Indian J Surg* 2010; **72**:143–145.