

# Peritoneal drainage versus laparotomy in necrotizing enterocolitis: a continued asked question

Mohammad G. Khirallah<sup>a</sup> and Ahmed I. Eid<sup>b</sup>

**Introduction** Necrotizing enterocolitis (NEC) is a severe surgical problem affecting mainly premature neonates (low birth weight and short gestational age neonates). Because of the severe deterioration in their general condition, some babies are subjected to formal laparotomy as a definitive treatment whereas others cannot tolerate this operative decision and may die if operated. Therefore, these poor babies may be subjected to bedside drainage with local anesthesia or sedation. Surprisingly, some of these neonates who undergo primary peritoneal drainage survive. This led us to compare both methods to identify a definitive management of this serious problem.

**Patients and methods** Fifty-six cases who presented with surgical NEC were studied during the period from March 2013 to March 2016. They were subdivided into two groups. Group A included cases treated by peritoneal drainage. Group B included cases treated by laparotomy. All cases had plain erect abdomen, abdominopelvic ultrasound, complete blood count, C-reactive protein, blood culture, and arterial blood gases. We inserted a central venous catheter in all cases and total parenteral nutrition was planned.

## Introduction

Necrotizing enterocolitis (NEC) is considered one of the most common gastrointestinal emergencies in newborns and represents a major cause of mortality [1].

The incidence of NEC is inversely related to the birth weight of affected neonates, hence affecting babies with low birth weight [2].

Classically, NEC is categorized into medical and surgical NEC depending on the clinical criteria such as refusal to feed, abdominal distention, vomiting, radiological positive or negative findings (free air, intestinalis pneumatosis, and air within the portal vein), and laboratory data such as thrombocytopenia, leukopenia, and positive blood culture [3–5].

Considerable controversy exists on the management of surgical NEC either by laparotomy or by primary peritoneal drainage [6].

Laparotomy in low birth weight infants is usually associated with 35–53% mortality and poor neurodevelopmental outcomes [7].

Bedside peritoneal drainage is performed under local anesthesia for extremely sick low birth weight neonates as an alternative to traditional laparotomy [8].

Surprisingly, some of these neonates survive. We aimed to evaluate primary peritoneal drainage versus traditional laparotomy.

**Results** The mean age of the babies at presentation was 10 days. The mean gestational age in group A was 31.9 weeks, whereas in group B it was 31.8 weeks. The mean body weight was 1.7 and 1.6 kg in groups A and B, respectively. Six babies in group A died during the study, whereas seven babies died in group B.

**Conclusion** Primary peritoneal drainage may be a reasonable line of treatment in neonates with NEC with good general condition, taking into consideration the possibility of traditional laparotomy if needed. *Ann Pediatr Surg* 13:81–84 © 2017 Annals of Pediatric Surgery.

*Annals of Pediatric Surgery* 2017, 13:81–84

**Keywords:** drainage, enterocolitis, laparotomy, necrotizing

Departments of <sup>a</sup>Pediatric Surgery and <sup>b</sup>Trauma and Emergency Medicine, Faculty of Medicine, Tanta University Hospitals, Tanta, Egypt

Correspondence to Mohammad G. Khirallah, MD, PhD, Pediatric Surgery Department, Tanta University Hospitals, El Geish Street, Tanta, El Gharbeya 31111, Egypt  
Tel: +20 100 354 6853; e-mail: mohamed.khirallah@med.tanta.edu.eg

Received 25 August 2016 accepted 25 September 2016

## Patients and methods

Fifty-six cases who presented with surgical NEC were studied during the period from March 2013 to March 2016. They were subdivided into two groups. Group A included cases treated by peritoneal drainage. Group B included cases treated by laparotomy. We excluded cases with severe manifestations and unsuitable for formal exploration and who had been subjected to a drainage procedure as a damage control strategy. Also, we excluded extremely low birth weight babies as they would not have been able to tolerate the exploration. All cases had plain erect abdomen, abdominopelvic ultrasound, complete blood count, C-reactive protein, blood culture, and arterial blood gases. We inserted a central venous catheter in all cases and total parenteral nutrition (TPN) was planned. Cases were all candidate for either exploration or drainage as lines of management. They were randomized into two groups: A and B. Group A included cases that received primary peritoneal drainage as a definitive treatment. Group B included cases that were subjected to laparotomy. In group A, lidocaine 2% at a dose of 0.05 mg/kg was infiltrated into subcutaneous planes in the right lower abdominal quadrant. A full-thickness incision 1 cm in length was performed. The pus or intestinal contents were expressed manually. Then, we irrigated the peritoneal cavity with warm saline until wash became clear. Drain was inserted and fixed to the anterior abdominal wall. Daily record of the output was obtained. Clinical and laboratory correlations were recorded. Deterioration of general condition despite the presence of drain called for

termination of this line of management and formal exploration was planned, provided that there was no severe metabolic acidosis or respiratory impairment. Follow-up of stable cases was performed. After 3–7 weeks of TPN and after the patient had an open bowel, we initiated oral intake gradually. In group B, formal exploration through the right upper abdominal transverse incision was performed. Resection of the bowel, ileostomy, or primary repair of the gut were performed according to the condition of the babies. Follow-up with TPN for 3–7 weeks was performed. Oral intake was initiated gradually as tolerated by the babies.

The study had ethical committee approval.

## Results

Fifty-six cases who presented with surgical NEC were studied during the period from March 2013 to March 2016. They were divided into two groups. Patients in group A were treated by primary peritoneal drainage. Group B included patients who were treated by traditional laparotomy. The baseline features and clinical data were almost the same for both groups in terms of birth weight, gestational age, platelet count, C-reactive protein, blood culture, clinical presentation, and radiological findings (Table 1).

The primary outcome variable was survival of the patients after either procedure. In group A, six (22.3%) patients died, whereas in group B, seven (24.4%) patients died; this was not significant. Radiological findings, birth weight, and platelet count had no significant effects on the mortality rates.

The mean hospital stay in group A was 37.36 days, with a SD of 5.09, whereas in group B, it was 41.17 days, with a SD of 4.6. This was significant.

There were no significant differences between the two groups in the dependence on TPN after the intervention. Oral intake was initiated just after the patient had an open bowel, no or minimal drain residual, absence of inflammatory mediators, and improved general condition.

Three cases in group A were treated by laparotomy after days 2–5 after drainage because of deterioration of the general condition and high output of drain. One of these patients died.

Ventilator support was required in 25 cases for a mean period of 21 days in group A. However, in group B, ventilator support was required in 26 cases for a mean period of 30 days (Table 2 and Figs 1 and 2).

The overall survival after 51 days of admission in neonatal ICU in groups A and B was illustrated using a Kaplan–Meier curve. In group A, five cases died, whereas in group B, six cases died (Fig. 3).

## Discussion

Primary peritoneal drainage was introduced for the first time by Ein and colleagues, who described it as an interval procedure for the treatment of neonates of very low birth weight babies who might not tolerate traditional laparotomy [9,10].

**Table 1 Admission and demographic data**

	Group A	Group B	P value
Gestational age (mean) (weeks)	31.926	31.828	0.855
Body weight (mean) (g)	1788.1	1685.5	0.364
CRP	67.11	87.86	0.054
TLC	13.370	13.207	0.799
Platelet count (mean/cm <sup>3</sup> )	143.7	121.4	0.119
Blood culture (number of cases)			
Positive	11	9	0.574
Negative	16	20	
Radiological findings			
Free air	17	20	0.703
Free air + IP	7	6	
Free air + IP + PVG	3	3	
US			
No free fluid	6	13	0.170
Free fluid	21	16	

CRP, C-reactive protein; IP, intestinalis pneumatosis; PVG, portal vein gas; TLC, total leukocytic count; US, ultrasound.

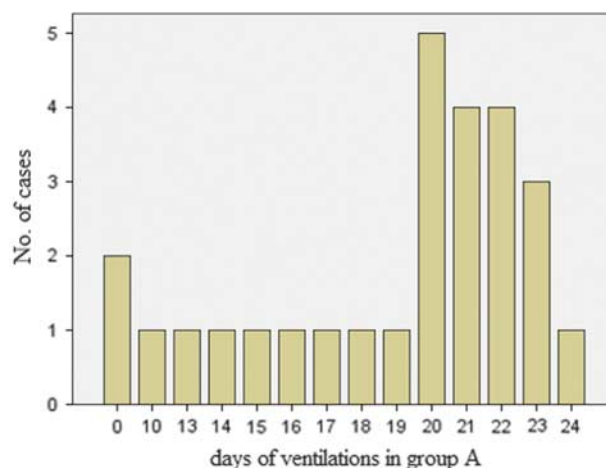
**Table 2 Operative and postoperative data**

	Group A	Group B	P value
Hospital stay (mean) (days)	37.63	41.17	0.009*
TPN (mean) (days)	30.23	38.11	0.005*
Need for laparotomy (number of cases)	3	–	
Ventilator support (mean) (days)	18.03	23.75	0.001*
Outcome			
Live	21	22	
Dead	6	7	0.235

TPN, total parenteral nutrition.

\*Significant difference.

**Fig. 1**



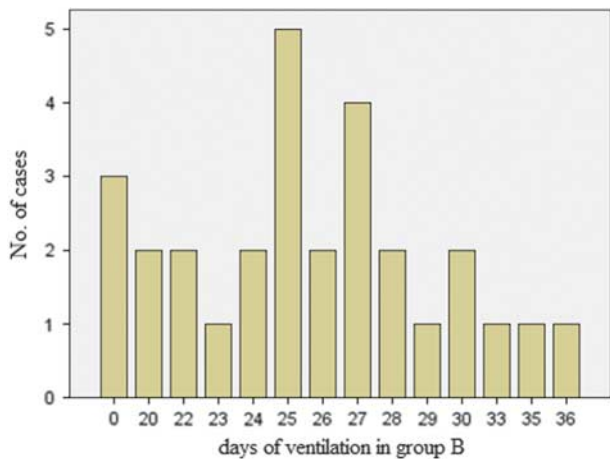
Ventilation days in relation to cases in group A.

Since then, some studies have depended on this procedure as a temporary method until stabilization of patients and then proceeded to laparotomy [11].

In cases of NEC that were unstable and had been subjected to primary drainage, surprisingly, some of the patients showed a rapid improvement and continued well without the second stage until discharge.

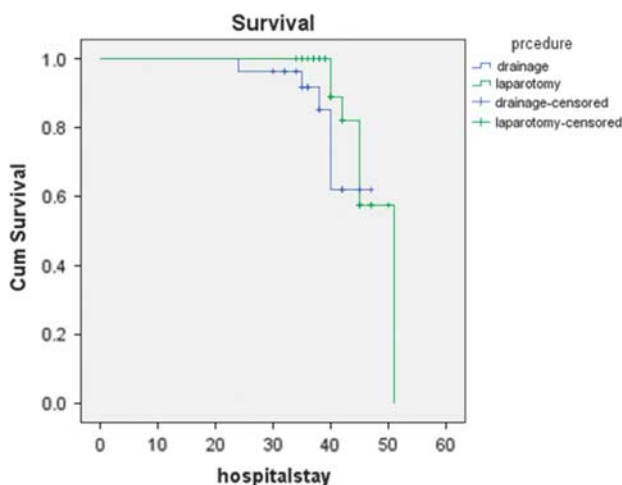
This was in agreement with some retrospective observational case series that documented survival rates that

Fig. 2



Ventilation days in relation to cases in group B.

Fig. 3



Kaplan–Meier curve for mortality in both groups.

were close to or even much better than those with laparotomy [12].

During this study, neonates with NEC were randomized into two groups irrespective to their clinical, laboratory, or radiological findings. Exclusion criteria were neonates with severe metabolic acidosis and very poor general condition and who could undergo drainage as the only interventional procedure.

However, some researchers believe that the procedure that should be performed in neonates with surgical NEC should be decided on the basis of radiological findings. They assumed that the presence of intestinal pneumatosis indicated extensive involvement of the gut, whereas presence of free air in the peritoneum without intestinal pneumatosis indicated limited involvement of the gut. Therefore, neonates with intestinal pneumatosis require formal laparotomy and patients with free air and with or

without a small segment of intestinal pneumatosis might be managed with drainage [13,14].

During analysis of the two groups in this study, no significant differences were found between them in the presence or absence of intestinal pneumatosis.

The overall survival after either procedure in the two groups of this study was insignificant. However, neonates subjected to primary peritoneal drainage showed some improvement over the laparotomy group.

In the same context, Demestre *et al.* [15] reported that 64% of neonates survived after primary peritoneal drainage irrespective of gestational age or birth weight.

In this study, the mean time to initiate oral intake was similar (42 and 44 days, respectively) in both groups; however, neonates who underwent drainage initiated oral intake earlier than those who underwent laparotomy.

Morgan *et al.* [16] found that neonates treated with immediate laparotomy initiated and achieved full oral intake in 52 days compared with 76 days for neonates subjected to drainage only.

Another important factor related to increased morbidity and mortality in those neonates was the need for ventilatory support either after drainage or after laparotomy.

According to our data, no published works have assessed this factor. Although there was no significant difference in the number of cases requiring respiratory support in the two groups, there was a significant difference in the total duration of ventilation between the two groups.

Dzakovic *et al.* [17] proved that peritoneal drainage improves respiratory functions on ventilation in critically ill neonates with NEC.

## Conclusion

We found that peritoneal drainage alone may be an alternative line of management not only in critical ill neonates with low birth weight but also stable neonates who were considered candidates for classic laparotomy.

## Conflicts of interest

There are no conflicts of interest.

## References

- Fitzgibbons SC, Ching Y, Yu D, Jaksic T. Mortality of necrotizing enterocolitis expressed by low birth weight categories. *J Pediatr Surg* 2009; **44**: 1072–1075.
- Neu J, Walker WA. Necrotizing enterocolitis. *N Engl J Med* 2011; **364**: 255–264.
- Lianos AR, Moss ME, Pinzon MC, Dye T, Sinkin R, Kendig WJ. Epidemiology of neonatal necrotizing enterocolitis: a population-based study. *Pediatr Perinat Epidemiol* 2002; **16**:342–349.
- Kliegman RM, Fanaroff AA. Necrotizing enterocolitis. *N Engl J Med* 1984; **310**:1566–1573.
- Bell MJ, Ternberg JL, Feigin RD, Keating JP, Marshal R, Barton L, *et al.* Neonatal necrotizing enterocolitis: therapeutic decisions based upon clinical staging. *Ann Surg* 1978; **187**:1–7.
- Luig M, Lui K. Epidemiology of necrotizing enterocolitis: changing regional trends in extremely preterm infants over 14 years. *J Pediatr Child Health* 2005; **41**:169–173.
- Henry MC, Moss RL. Surgical therapy for necrotizing enterocolitis: bringing evidence to the bedside. *Semin Pediatr Surg* 2005; **14**: 181–190.

- 8 Soula JE, Tepas JJ, Koniaris LG. Peritoneal drainage versus laparotomy for necrotizing enterocolitis and intestinal perforation: a meta analysis. *J Surg Res* 2010; **161**:95–100.
- 9 Cass D, Brandt M, Patel DL, Nuchtern JG, Minifee PK, Wesson D. Peritoneal drainage as definitive treatment for neonates with isolated intestinal perforation. *J Pediatr Surg* 2000; **35**:1531–1536.
- 10 Ein SH, Marshall DG, Grivan D. Peritoneal drainage under local anesthesia for necrotizing enterocolitis. *J Pediatr Surg* 1977; **12**:963–967.
- 11 Janik JS, Ein SH. Peritoneal drainage under local anesthesia for necrotizing enterocolitis perforation: a second look. *J Pediatr Surg* 1980; **15**:565–568.
- 12 Dimmitt RA, Meier AH, Skarasgard ED, Halamek LP, Smith BM, Moss RL. Salvage laparotomy for failure of peritoneal drainage in necrotizing enterocolitis in infants with extremely low birth weight. *J Pediatr Surg* 2005; **35**:856–859.
- 13 Ehrlich PF, Sato TT, Short BL, Hartman GE. Outcome of perforated necrotizing enterocolitis in the very low birth weight neonate may be independent of the type of surgical treatment. *Am Surg* 2001; **67**:752–756.
- 14 Gollin G, Abarabnell A, Baerg JE. Peritoneal drainage as definitive management of intestinal perforation in extremely low birth weight infants. *J Pediatr Surg* 2003; **38**:1814–1817.
- 15 Demestre X, Ginovart G, Figueras AJ, Porta R, Krauel X, Garcia AA. Peritoneal drainage as primary management in necrotizing enterocolitis: a prospective study. *J Pediatr Surg* 2002; **37**:1534–1539.
- 16 Morgan LJ, Shochat SJ, Hartman GE. Peritoneal drainage as primary management of perforated NEC in the very low birth weight infants. *J Pediatr Surg* 1994; **25**:310–315.
- 17 Dzakovic A, Notrica DM, Smith OB, Wesson DE, Jaksic T. Primary peritoneal drainage for increasing ventilator requirements in critically ill neonates with necrotizing enterocolitis. *J Pediatr Surg* 2001; **35**:730–732.