

# Double sigmoid atresia with meconium pseudocyst masquerading as a mesenteric cyst

Shalini Hegde, Monika Bawa, Raj Kumar and KLN Rao

**Sigmoid atresia is one of the rarest cause of neonatal intestinal obstruction. We report an antenatally diagnosed mesenteric cyst in a neonate that was subsequently diagnosed as a meconium pseudocyst with double sigmoid atresia. A localized type 4 atresia or a colonic atresia associated with meconium pseudocyst has not been reported in the literature to date. *Ann Pediatr Surg* 13:166–169 © 2017 Annals of Pediatric Surgery.**

*Annals of Pediatric Surgery* 2017, 13:166–169

## Introduction

Sigmoid colon is rarely involved in patients with atresia of the colon. Reported cases are usually type 1, although other types have also been reported. The reason for publishing this case is its unusual presentation as an antenatally and postnatally diagnosed mesenteric cyst. This is not only the first reported case of a localized type 4 sigmoid atresia but also of any colonic atresia associated with a meconium pseudocyst.

## Case report

We present the case of a primigravida with an antenatal diagnosis of a mesenteric cyst who was delivered by caesarean section at full term. The diagnosis was made by ultrasound at 38 weeks of gestation and the cyst measured 46 × 54 mm in size (Fig. 1). The child had abdominal distension at birth, intolerance to feed and did not pass meconium. A postnatal ultrasound showed a complex cystic mass in the abdomen measuring 64 × 52 mm in size; dilated bowel loops with increased peristalsis close to the lesion were observed. The child presented to us on the second day of life with moderate abdominal distension and bilious aspirates. An infant feeding tube passed per rectum was mucous stained. Radiography of the abdomen revealed dilated bowel loops with a sharp cutoff. A computed tomography of the abdomen showed a cystic lesion in the lower abdomen of size 8.6 × 4.7 × 6.6 cm causing large bowel obstruction (Fig. 2). On explorative laparotomy, an 8 × 6 cm dark cystic lesion was present in the left iliac fossa, which was delivered intact after it got avulsed from its narrow 1 cm pedicle during exploration. The colon was dilated more than the small bowel. A blind ending sigmoid was noticed, which was widely separated from its distal rectosigmoid stump. The distal bowel had another atresia 1.5 cm above the peritoneal reflection (Fig. 3). The sigmoid stump was brought out as a stoma and the atretic bowel left *in situ*. The child was discharged in satisfactory condition after 3 days and is awaiting pull-through procedure.

## Discussion

Colonic atresia is a rare cause of intestinal obstruction in neonates with an incidence of one in 20 000. Large gut atresia accounts for 5–15% of all atresias and less than

**Keywords:** atresia, obstruction, pseudocyst, sigmoid colon

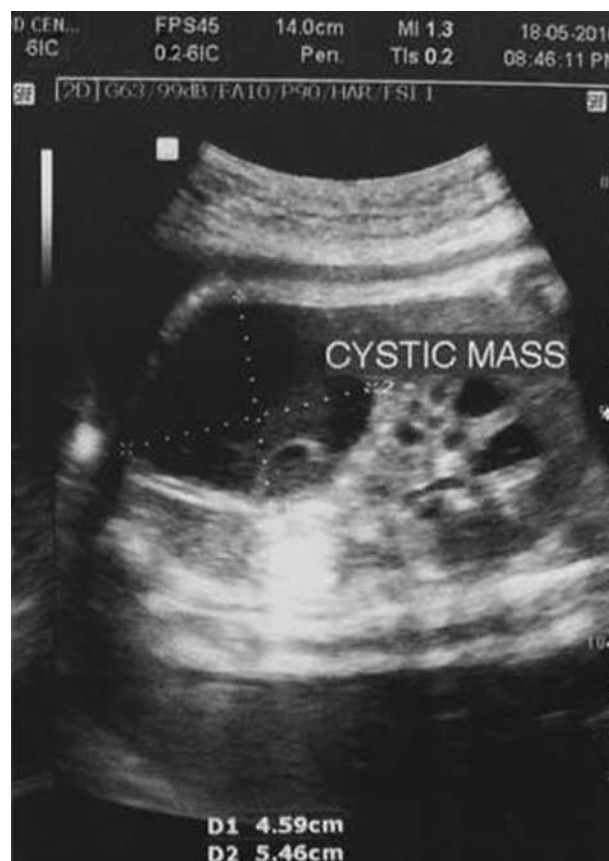Department of Pediatric Surgery, Post Graduate Institute of Medical Education and Research (PGIMER), Chandigarh, India

Correspondence to Monika Bawa, MS, MCh, Department of Pediatric Surgery, Advanced Pediatric Center, Post Graduate Institute of Medical Education and Research (PGIMER), Sector 12, Chandigarh 160012, India  
Tel: +91 172 275 5352; fax: +91 172 2744401;  
e-mail: monikabawa@hotmail.com

Received 6 September 2016 accepted 27 October 2016

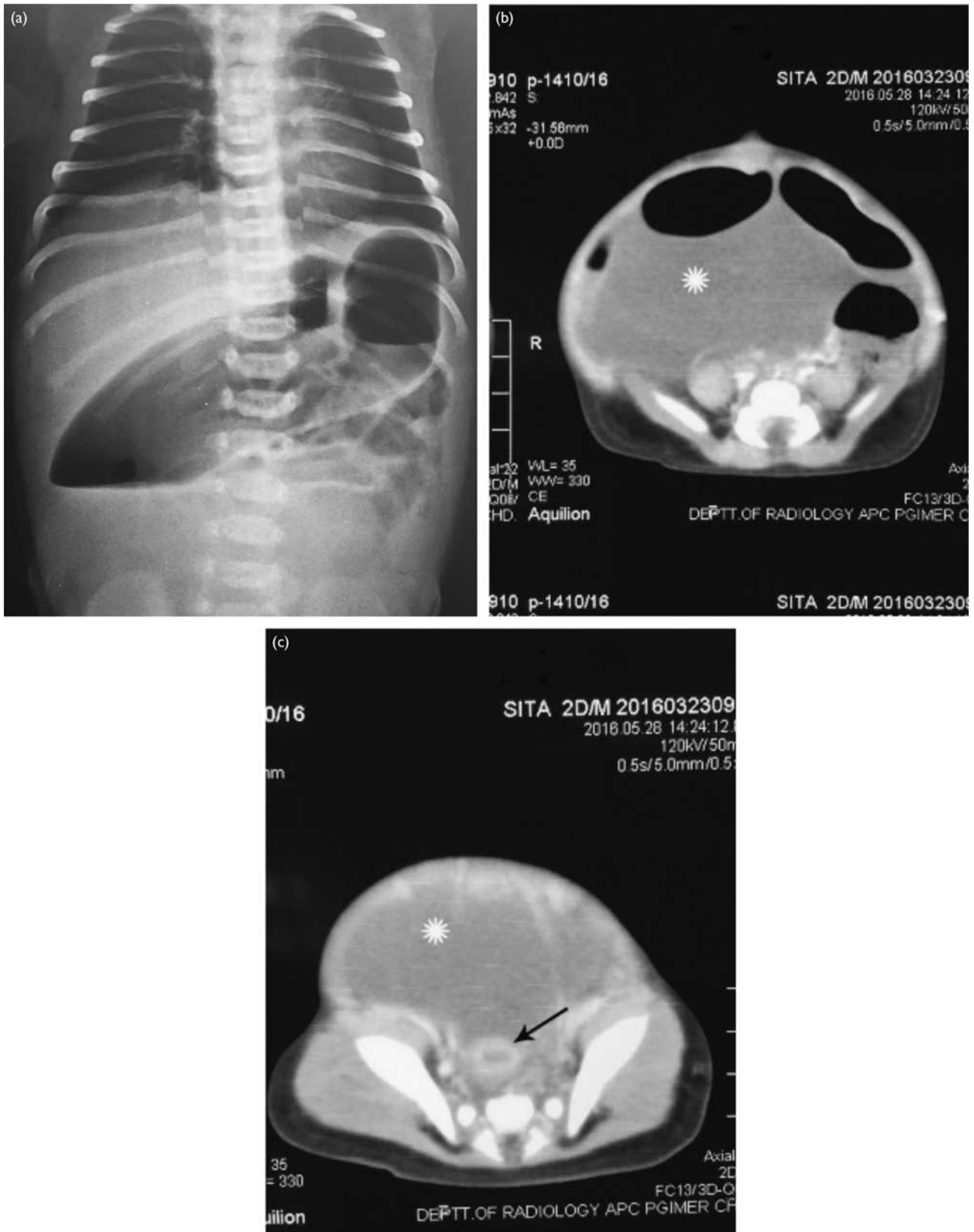
25% occur distal to the splenic flexure [1]. Etensel *et al.* [2] conducted a literature survey of colonic atresia and found only 224 cases between 1963 and 2005. Of the 208 cases of atresia, only 22 were found to be involving the sigmoid colon. On a thorough search for previously published reports of patients with only sigmoid atresia, we found less than 35 cases reported so far [2–6]. Out of these, only four patients had type 4 sigmoid atresia (Table 1). In these four patients, the second atresia was

**Fig. 1**



Antenatal ultrasound showing the cystic lesion.

Fig. 2

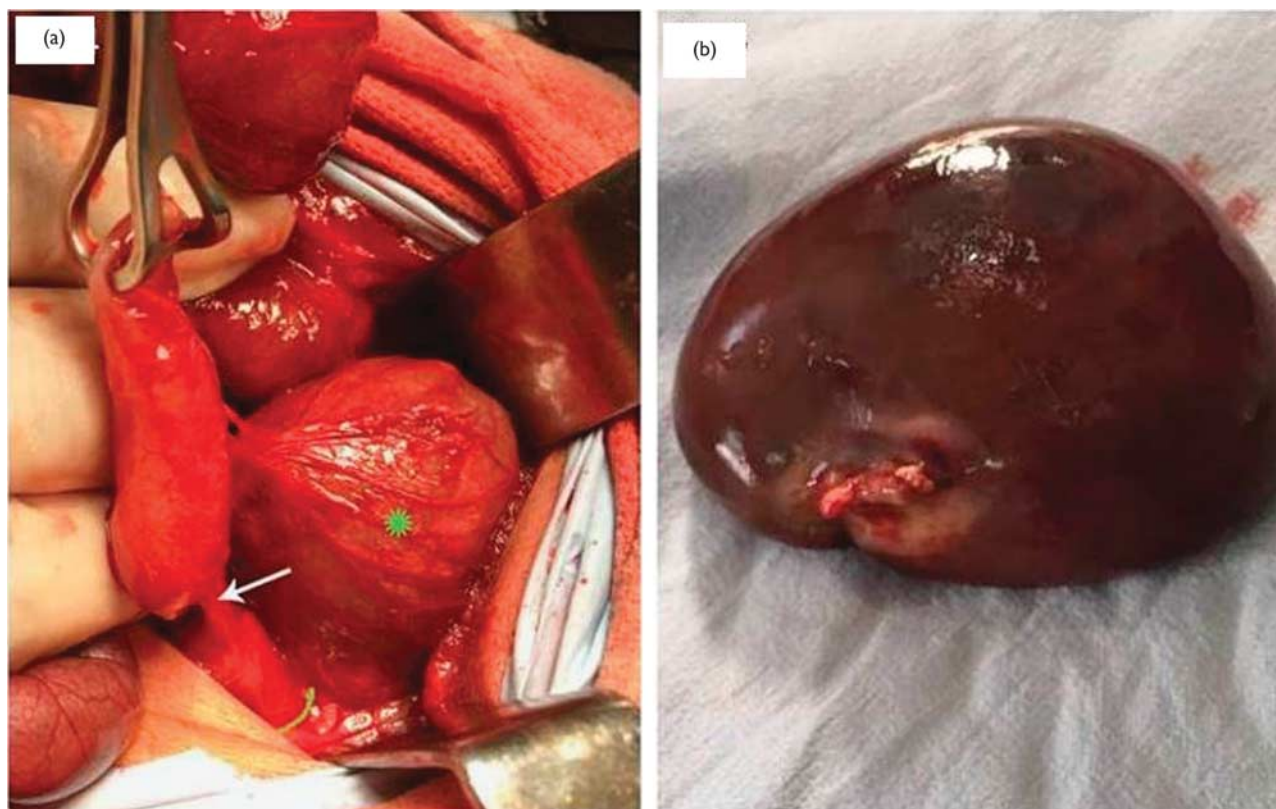


(a) Erect radiography of the abdomen showing a dilated bowel loop with air-fluid levels. (b) CT of the abdomen: white star is the cyst, which can be seen surrounded by dilated bowel loops. (c) CT of the abdomen: arrow indicates the collapsed rectum. CT, computed tomography.

present at the ascending colon, hepatic flexure, transverse colon and splenic flexure. Our case is unusual in having the second atresia also in the rectosigmoid

segment. It is possible that the cause of this two-point atresia in the rectosigmoid is an antenatal volvulus around a long sigmoid mesentery. Other explanations for a

Fig. 3



(a) Intraoperative photograph. Green star indicates blind ending sigmoid. Babcock holding atretic distal stump. Arrow indicates second atresia. Green line indicates peritoneal reflection. (b) Meconium pseudocyst.

**Table 1** Published reports of sigmoid atresia [2–6]

References	Types	Number of cases
Gaug, 1922	–	1
Gann and Hoffman, 1952	–	1
Garrish, 1955	–	1
Feggetter, 1955	–	1
Armitage, 1958	–	1
Harbour <i>et al.</i> , 1965	III	1
Freeman, 1966	I and II	2
Coran and Eraklis, 1965	I/II	2
Boles <i>et al.</i> , 1976	I and II	2
Grosfeld <i>et al.</i> , 1979	I	1
Alexander, 1979	–	1
Benawra <i>et al.</i> , 1981	– and III	2
Doody and Nguyen, 1987	–	1
Nitta <i>et al.</i> , 1987	I	1
Pohlson <i>et al.</i> , 1988	I and IV	2
Davenport <i>et al.</i> , 1990	IV	1
Karnak <i>et al.</i>	I and III	2
Watts <i>et al.</i> , 2003	III	1
Sauve and Leung, 2003	IV	1
Komuro <i>et al.</i> , 2003	III	1
Etensel <i>et al.</i> , 2004	IV and II	2
Baglaj <i>et al.</i>	IIIa, II, I – and	4
Mirza B <i>et al.</i>	–	1

vascular catastrophe leading to atresia in the sigmoid include internal hernia, intussusceptions, strangulation due to a closing umbilical ring and emboli in fetal circulation [5].

Patients with colonic atresia commonly present with features of intestinal obstruction [7]. Type 1 atresia

patients may present later and may need to be differentiated from those with Hirschsprung's disease with a contrast enema [8]. Our case presented with an antenatal and postnatal diagnosis of a mesenteric cyst. Large bowel obstruction was evident on the abdomen computed tomography with dilated bowel loops but a collapsed rectosigmoid was thought to be due to pressure effect from the cyst. Antenatal perforation causing a meconium pseudocyst is seen commonly with ileal atresia and has previously not been reported with colonic atresia.

### Conclusion

Sigmoid atresia is a rare cause of neonatal intestinal obstruction. It can present with a meconium pseudocyst and multiple strictures.

### Acknowledgements

Authors contribution: Shalini Hegde: literature search, patient care, drafting the manuscript; Monika Bawa: supervision, patient in charge, finalizing the manuscript; Raj Kumar: patient care and intraoperative assistance; KLN Rao: supervision, finalizing the manuscript.

### Conflicts of interest

There are no conflicts of interest.

### References

- Powell RW, Raffensperger JG. Congenital colonic atresia. *J Pediatr Surg* 1982; 17:166–170.

- 2 Etensel B, Temir G, Karkiner A, Melek M, Edirne Y, Karaca I, *et al.* Atresia of the colon. *J Ped surg* 2005; **40**:1258–1268.
- 3 Chester ST, Robinson WT. Congenital atresia of the transverse colon. *Ann surg* 1957; **146**:824–829.
- 4 Karnak I, Ciftci AO, Senocak ME, Tanyel FC, Buyukpamukcu N. Colonic atresia: surgical management and outcome. *Pediatr Surg Int* 2001; **17**:631–635.
- 5 Mirza B, Iqbal S, Ijaz L. Colonic atresia and stenosis: our experience. *J Neonat Surg* 2012; **1**:4.
- 6 Baglaj M, Carachi R, MacCormack B. Colonic atresia: a clinicopathological insight into its etiology. *Eur J Pediatr Surg* 2010; **20**: 102–105.
- 7 Cox SG, Numanoglu A, Millar AJW, Rode H. Colonic atresia: spectrum of presentation and pitfalls in management. A review of 14 cases. *Pediatr Surg Int* 2005; **21**:813–818.
- 8 Mustafa G, Mirza B, Bashir Z, Sheikh A. Delayed recognition of type I sigmoid-colon atresia: the perforated web variety. *APSPJ Case Rep* 2010; **1**:5.