

Enteral reduction and oblique anastomosis: a novel technique in the treatment of small bowel atresia

Abdelbasit E. Ali^{a,b} and Awad R. Abdalla^a

Background Jejunoileal atresias are major causes of neonatal intestinal obstruction, and various surgical techniques were described for their treatment. Resection and/or tapering of the proximal dilated pouch and end-to-end or end-to-back enteral anastomosis are the most commonly used techniques. Either of these techniques, however, has shortcomings such as loss of bowel length, kink obstruction, and anastomotic leak due to anastomotic line mismatch.

Objective The aim of this study was to describe an alternative surgical technique for bowel atresia repair, enteral reduction and oblique anastomosis.

Patients and methods The technique involves reduction of the dilated bowel diameter by removing an elliptical full-thickness part of the anterior wall of the proximal dilated pouch and oblique anastomosis of the resultant window with a longitudinally incised posterior wall of the distal bowel.

Results This technique was used in seven successive neonates, four female and three male, in 1 year. Their ages at operation ranged between 2 and 30 days

(median 3 days). Six neonates recovered well. Enteral feeds were tolerated in 7–10 days and the length of hospital stay ranged between 15 and 36 days. One baby, who underwent surgical repair at the age of 30 days, died following severe sepsis and anastomotic leak.

Conclusion Enteral reduction and oblique anastomosis is an easy and safe alternative to current surgical techniques used for the treatment of small intestinal atresia. No bowel resection is required while proximal bowel tapering is achieved. *Ann Pediatr Surg* 13:133–135 © 2017 Annals of Pediatric Surgery.

Annals of Pediatric Surgery 2017, 13:133–135

Keywords: oblique anastomosis, small bowel atresia, tapering

^aDepartment of Paediatric Surgery, Soba University Hospital, Khartoum, Sudan and ^bDepartment of Paediatric Surgery, King Saud Medical City, Riyadh, KSA

Correspondence to Abdelbasit E. Ali, MBBS, MD, FRCS (Glasg), FRCS (Paed Surg), MD Paed Surg, SMSB (Hon), Department of Paediatric Surgery, Soba University Hospital, PO Box 102, 11111 Khartoum, Sudan
Tel: +249 912 349 336; fax: +249 157 795 224; e-mail: aliabdelbasit@hotmail.com

Received 10 November 2016 accepted 5 April 2017

Introduction

Jejunoileal atresias are major causes of neonatal intestinal obstruction. The condition is attended with significant morbidity and mortality. With improvements in surgical technique and perioperative neonatal care, overall mortality from intestinal atresia decreased from 90% in 1952 to 10% in recent years [1].

Depending on the type of atresia, various surgical techniques were described for treatment. Resection and/or tapering of the proximal dilated pouch and end-to-end or end-to-back enteral anastomosis are the most commonly used techniques [2]. Both of these techniques, however, have shortcomings such as loss of bowel length, kink obstruction, and anastomotic leak. The condition is particularly difficult when proximal jejunal atresia is encountered.

Objective

This study was carried out to describe an alternative surgical technique for jejunoileal atresia repair and present the results of its application in a series of babies. The enteral reduction and oblique anastomosis (EROA) technique was introduced to decrease the complication rate and to improve the overall outcome.

Patients and methods

Following adequate resuscitation and preoperative preparation, the surgical technique involves reduction of the dilated bowel diameter by removing an elliptical


full-thickness part of the anterior wall of the proximal dilated pouch and oblique anastomosis of the resultant window with a longitudinally incised posterior wall of the distal bowel using continuous absorbable suture. At the proximal dilated blind end, 1/3 to 3/8 of the circumference is removed as a ventral wall elliptical window excision with a lower margin closer to the mesenteric border to avoid twisting/kinking yet preserving adequate blood supply to the lower margin and that of the upper margin is secured from the dorsal wall blood supply.

It is very important to avoid leaving a shoulder at the anastomosis. To achieve this, the resected window should reach the farthest distal point in the ampulla of the dilated proximal bowel (Fig. 1). Care is taken not to kink/twist the anastomosis or to damage the mesenteric vessels.

Anastomosis is completed with a single layer, continuous absorbable suture material. There is no need for a transanastomotic tube or a peritoneal drain insertion. Moreover, there is no need to close a mesenteric defect as the mesentery of the proximal and distal segments overlap when EROA is performed (Fig. 2). In case of multiple intestinal atresias, type IV, the distal atretic segments are treated with the conventional resection and end-to-end anastomosis.

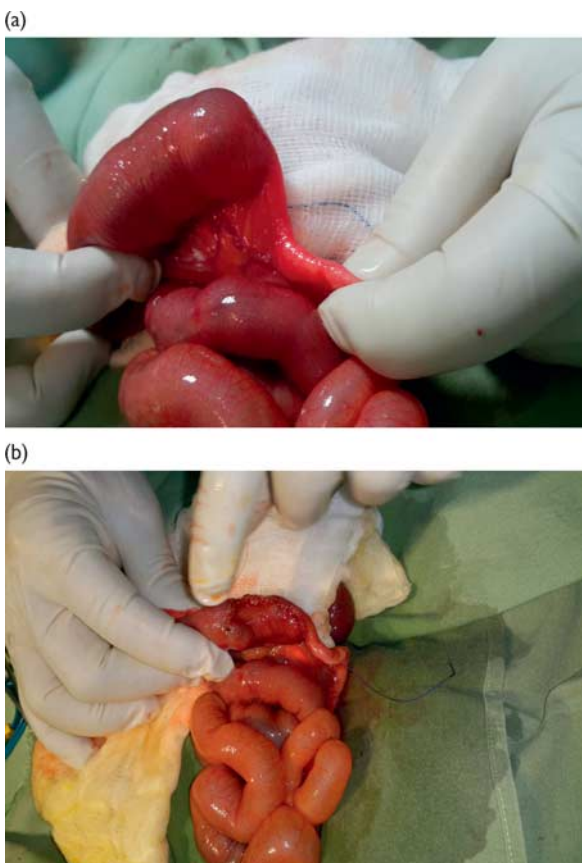
The study group included all neonates with small intestinal atresia treated at Soba University Hospital in 1 year (2015). Babies were nursed during the perioperative period in the NICU at Soba University Hospital and

Fig. 1



A schematic representation of the enteral reduction and oblique anastomosis operative procedure. The dotted lines indicate the incision and the letters indicate the key suture points to achieve the oblique anastomosis.

Fig. 2



(a) Intraoperative view of type I jejuna atresia. (b) Operative view of jejunal atresia following enteral reduction and oblique anastomosis. Note the resulting proximal bowel reduction and tapered anastomosis.

Elsewedy Charity Children's Hospital in Khartoum. Data were collected from patients' notes. Age at operation, body weight, diagnosis, surgical procedure, time to tolerating enteral feeds, length of hospital stay, and outcome were documented.

Results

This technique was used in seven successive neonates, four females and three males, in 1 year. Their ages at operation ranged between 2 and 30 days (median 3 days). Six neonates recovered well. Enteral feeds were tolerated for 7–10 days and the length of hospital stay ranged between 15 and 36 days. One baby, who underwent surgical repair at the age of 30 days, died following severe sepsis and anastomotic leak (Table 1).

Discussion

In their experimental work with occluding the blood supply to some parts of the intestine under development, Louw and Barnard [3] postulated that the supply to bowel areas adjacent to the atretic segment was likely to be compromised, not enough to cause necrosis but enough to cause a functional problem with resultant defective peristalsis. Thus, they recommended resection of the blind bulbous end of the proximal intestine before the anastomosis. When the intestinal length is normal, the dilated pouch can be resected, removing 10–15 cm of bowel proximal to the atresia, and, paradoxically, every effort is made to preserve bowel length, particularly in the presence of foreshortened bowel in type IIIb or IV atresia [2].

Several surgical techniques were described and are in use in the treatment of jejunoileal atresia. Such techniques include resection and end-to-end or end-to-back anastomosis and various tapering methods such as antimesenteric wedge excision, seromuscular mucosa preserving strip excision, and inversion tapering with end-to-end anastomosis [1,4]. These techniques are not without possible shortcomings. Although loss of bowel length and potential short bowel syndrome may not be a real concern in the situations of distal jejunal or ileal atresia due to the feasibility of an adequate back resection to preserve an adequate residual bowel length, this however may be technically difficult to achieve when a proximal jejunal atresia is encountered, particularly when the proximal dilatation extends up to involve the duodenum. Such a high jejunal atresia with proximal dilatation extending to the duodenum represents a particular challenge because of the risks associated with proximal resection into the duodenum, potential anastomotic discrepancy, leak, and loss of bowel length. Anastomotic leak results from discrepancy between the proximal and distal ends of the atretic segment, or from the junction of the longitudinal tapering with the anastomotic margin, particularly when full-thickness inversion tapering is used. Kink obstruction is likely to complicate any end to back or end to fishmouthed-end anastomosis. Several surgical technique modifications have, therefore, been reported [5,6].

To achieve the treatment goals of an adequately patent, nonvulnerable to kink, orthostatic anastomosis with bowel length and functional preservation and with no or minimal risks for anastomotic disparity and leak, the technique of EROA was introduced. At laparotomy for jejunal atresia, it is not unusual to observe a degree of peristalsis at the blind-ended dilated part of the jejunum. There is no published quantification of the degree or effectiveness of such observed peristalsis; however, it is justifiable to

Table 1 Outcome of enteral reduction and oblique anastomosis in infants with jejunoileal atresia

Patient nos	Age (days)	Sex	Weight (kg)	Diagnosis	Outcome	Comment
1	3	Female	2.2	Jejunal atresia	Alive	NICU-TPN discharged after 10 days
2	30	Male	–	Jejunal atresia	Died	Anastomotic leak at day 6
3	3	Female	2.5	Ileal atresia	Alive	Discharged well
4	2	Female	1.9	Jejunal atresia	Alive	Discharged well
5	2	Female	2.1	Jejunal atresia	Alive	Discharged well
6	3	Male	2.4	Jejunal atresia	Alive	Discharged well
7	4	Male	3.2	Jejunal atresia	Alive	Discharged well

TPN stands for Total Parenteral Nutrition.

anticipate an improvement in such bowel movements once distal obstruction is relieved. Parnasogastric tube water soluble contrast study under fluoroscopy in one representative sample of our series 15 days after EROA showed passage of the contrast from the stomach through the anastomosis in 2 min with no evidence of a contrast hold-up. Therefore, to preserve the duodenum and bowel length in the event of proximal jejunal atresia, proximal resection does not have to be extensive. We believe it is the discrepancy and bowel kinking – rather than the atonia – that affect and interfere with adequate motility, with the subsequent manifestation as vomiting or partial obstruction.

In summary, as an alternative technique in the treatment of jejunal atresia, the EROA technique has the following advantages:

- (1) As regards the anastomotic ring integrity and the risk for leak, the intraluminal pressure distribution is uniform and is partially accommodated by the intact wall of the distal end as no shouldering exists.
- (2) The surgical technique facilitates the intestinal motility by ensuring tapering and adequately patent, nonkinked anastomosis.
- (3) There is no mesenteric defect to repair, thereby reducing the risk for ischemia and bowel kinking.
- (4) No transanastomotic tube is required.

Conclusion

EROA is an easy and safe alternative to conventional surgical techniques used for the treatment of jejunoileal atresia. With no bowel resection required while proximal bowel tapering is achieved, the anastomosis provides adequate orthostatic restoration of patent continuity without undue pressure on the anastomotic line.

Conflicts of interest

There are no conflicts of interest.

References

- 1 Rode H, Miller AJW. Jejunoileal atresia. In: Puri P, Hollwarth M, editors. *Pediatric surgery*. Springer-Verlag Berlin Heidelberg; New York, 2006. pp. 213–228.
- 2 Millar A, Numanoglu A. Congenital atresia and stenosis of the intestine. In: Spitz L, editor. *Operative pediatric surgery*, 7th ed. London: CRC Press; 2013. pp. 422–432.
- 3 Lowy IH, Barnard CN. Congenital intestinal atresia. *Lancet* 1955; **269**:1065–1067.
- 4 Kimura K, Perdzynski W, Soper RT. Elliptical seromuscular resection for tapering the proximal dilated bowel in duodenal or jejunal atresia. *J Pediatr Surg* 1996; **31**:1405–1406.
- 5 Patil VK, Kulkarni BK, Jiwane A, Kothari P, Poul S. Intestinal atresia: an end-to-end linear anastomotic technique. *Pediatr Surg Int* 2001; **17**:661–663.
- 6 Kamal NR, Deepak KG. Modified gut anastomotic technique in type III and type IV jejunoileal atresias. *J Neonat Surg* 2016; **5**:48.