

# Atypical back pain in a child: subcutaneous lumbar abscess associated with chickenpox

Ian C. C. King<sup>a</sup>, Geoff Lawson<sup>b</sup> and Lisa Turret<sup>c</sup>

**Back pain in children has numerous possible causes. Although chickenpox is an extremely common and contagious condition in the paediatric population, it can be associated with potentially life-threatening musculoskeletal complications. We discuss the extremely unusual case of a child with an extensive subcutaneous lumbar abscess who presented with severe back pain associated with active chickenpox infection. *Ann Pediatr Surg* 13:62–64 © 2017 Annals of Pediatric Surgery.**

Annals of Pediatric Surgery 2017, 13:62–64

**Keywords:** abscess, back pain, chickenpox, group A  $\beta$ -haemolytic streptococcus, varicella zoster virus

<sup>a</sup>Department of Plastic and Reconstructive Surgery, Royal Victoria Infirmary, Newcastle upon Tyne, <sup>b</sup>Department of Paediatrics, Sunderland Royal Hospital, Sunderland and <sup>c</sup>Department of Trauma and Orthopaedics, Royal Sussex County Hospital, Brighton, UK

Correspondence to Ian C. C. King, MA (Oxon), MBBS, MRCSd, Department of Plastic and Reconstructive Surgery, Royal Victoria Infirmary, Newcastle upon Tyne NE1 4LP, UK  
Tel/fax +44 781 687 7914;  
e-mail: iancking@doctors.org.uk

Received 20 July 2013 accepted 20 June 2016

## Introduction

Back pain in children can be attributed to a wide range of pathologies. Although chickenpox is an extremely common condition in the paediatric population, the development of potentially life-threatening cutaneous complications is not frequently seen. We present the case of a child with severe back pain associated with active chickenpox infection. The presentation is extremely uncommon in the literature and has not previously been encountered within our paediatric and orthopaedic units. We intend this report to highlight an important differential diagnosis for consideration when assessing patients with concomitant infection with chickenpox and back pain.

## Case report

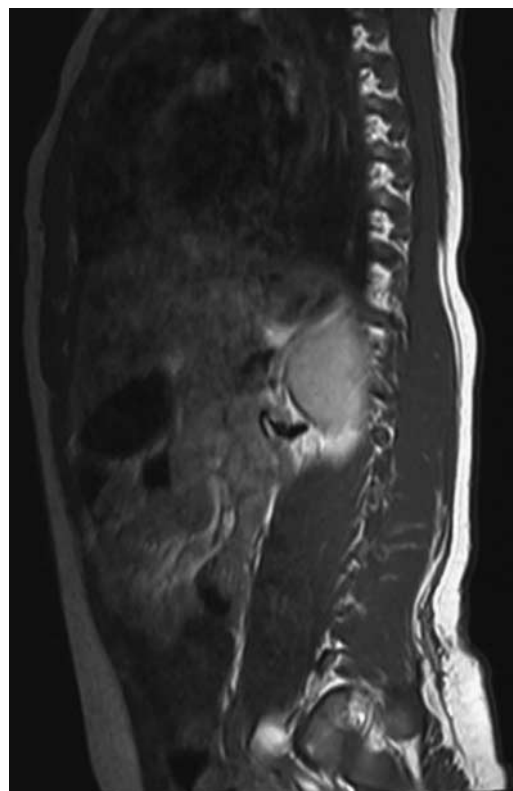
A 4-year-old previously healthy boy was admitted with infected chickenpox. The patient had developed chickenpox spots 3 days before admission. Within 2 days of the onset of the chickenpox the child was pyrexial, unable to weight-bear because of back pain and the left arm had become cellulitic from the elbow to the wrist. There was no evidence of a collection on admission, and the child was treated for systemic malaise secondary to chickenpox.

Broad-spectrum intravenous antibiotics failed to resolve the child's pyrexia, and his lower back pain worsened to the extent that he required opiate analgesia. A tender swelling was found under skin overlying the thoracolumbar junction and sacrum, but no redness or fluctuance was detectable. Inflammatory markers were grossly elevated, but nothing was grown on blood cultures. MRI of the back revealed an extensive fluid focus with peripheral enhancement confined to the subcutaneous fat plane, located primarily over the lumbar spine but extending from T11 to the coccyx. The collection measured 13 mm at its deepest point, extending 7 cm laterally to both loins from the midline (Figs 1–3). There was no evidence of myositis or osteomyelitis.

This abscess was managed conservatively with intravenous flucloxacillin and clindamycin. Within 3 days, despite antibiotic cover the cellulitic and tender right

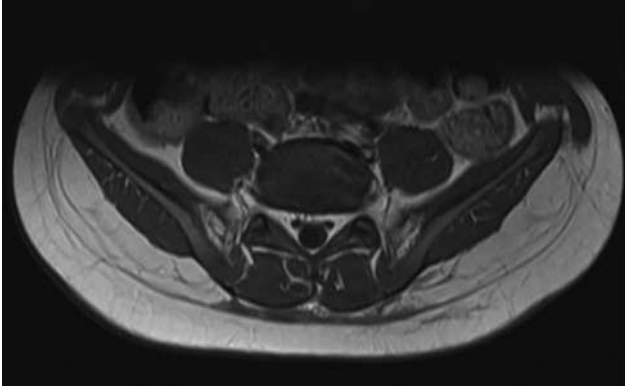
forearm developed a fluctuant collection, which, unlike the back, required incision and drainage. Fluid from the debrided wound grew nothing on culture. The patient improved both clinically and biochemically over the following fortnight and began mobilizing and was successfully discharged. Follow-up MRI charted the resolution of the back collection with an extended course of antibiotics. Informed consent was obtained. All data were anonymised.

Fig. 1



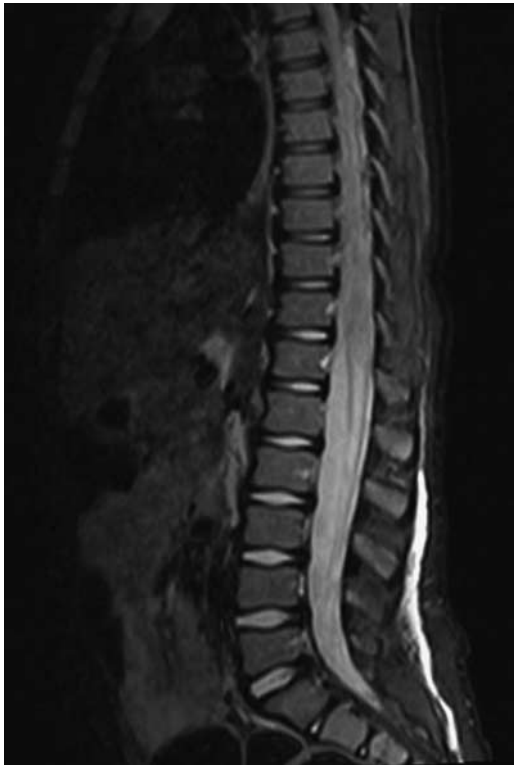
Sagittal MRI showing fluid collection in the subcutaneous plane.

Fig. 2



MRI of the fluid collection at its maximal depth.

Fig. 3



Sagittal STIR sequence MRI of the fluid collection in the subcutaneous plan.

## Discussion

Severe back pain in children should always raise concern and be investigated as a matter of urgency. Careful history and thorough examination are essential in helping to differentiate between the many possible causes of back pain in children. Although trauma is a common reason for presentation, more significant pathologies must also be ruled out if the patient is systemically unwell. Any child presenting with bony pain and fever should be investigated for osteomyelitis, with MRI being the imaging modality of choice. Bone tumours such as eosinophilic granuloma or Ewing's sarcoma can mimic osteomyelitis

radiologically, although metastatic disease, such as from neuroblastoma, is usually more distinct. Acute leukaemias frequently present with bone pain secondary to osseous infiltration.

Septic arthritis is common in young children. Often involving the metaphysis, septic arthritis also presents with fever, raised inflammatory markers, swelling, arthralgia and an inability to weight-bear with restricted movements. Acute rheumatic fever also can present with arthralgia, fever and raised markers. There are many other differentials, including spondylolisthesis, discitis, disc herniation, tuberculosis and transient synovitis, highlighting the importance of thorough assessment and an appreciation of the patient's clinical context. Our patient presented with infected chickenpox.

Chickenpox is a very common and highly contagious infection in childhood with a recognizable course that is usually self-limiting and benign. However, the disease can be associated with a number of potentially serious and life-threatening complications. Rare but well-known complications of chickenpox can occur in previously healthy children and include encephalitis, meningitis, secondary bacterial infection and, in very rare cases, stroke. Cutaneous and musculoskeletal complications of chickenpox have been reported and can be limb-threatening and even life-threatening if not recognized and treated early in both immunocompromised and immunocompetent patients.

Severe complications include cellulitis [1], abscess formation [2–6], osteomyelitis [5–7], septic arthritis [8] and necrotizing fasciitis [5,9,10]. Death is a rare but reported occurrence [11] in the population group affected. Staphylococcal and streptococcal toxic shock syndromes are often seen in association with these complications [10], and studies note an increasing rise in the incidence of invasive Group A  $\beta$ -haemolytic streptococcus (GABHS) infection in primary varicella [7]. Schreck *et al.* [5] found that 78% of their patients between 1984 and 1994 who required operative treatment for their musculoskeletal complications had grown GABHS on culture. Complications of chickenpox have also been attributed to *Streptococcus pyogenes* [9], *Staphylococcus aureus* [1] and methicillin-resistant *S. aureus* [2]. It should be noted that blood cultures and aspirates are frequently sterile [12,13], as encountered in our case, posing an obstacle to diagnosis.

Studies have shown that the diagnosis of invasive GABHS in patients with chickenpox can often be missed [7,14], with diagnosis then dependent on subsequent admission with a more advanced illness. Doctor *et al.* [14] notes a correlation between the presence of GABHS and children with chickenpox who manifest fever on or beyond the fourth day of the exanthema and observes that cutaneous cellulosic lesions are not always present with systemic infection. Runel-Belliard *et al.* [12] further observed in their series of 54 patients a correlation between the presence of cellulitis, a child's age (being aged 6 and over) and the frequency of coexisting deep soft-tissue infections. Within the literature, however, there appears to be a broad age range in which patients present with deep soft-tissue infections.

Some authors suggest that patients with chickenpox are also potentially at risk of developing severe skin and soft-tissue complications as a result of using NSAIDs [15,16]. This, however, remains controversial with further in-depth and rigorous studies needed to assess. Nonetheless, when treating patients with chickenpox and pain or fever, avoidance of NSAIDs might be prudent in favour of an alternative from the wide range of analgesics available.

## Conclusion

The differential diagnoses for back pain in children are extensive, and symptoms should not be dismissed readily. Children presenting with extremity pain, fever and concomitant infection with chickenpox should be thoroughly investigated. Recognition of the potential for secondary infection, particularly with group A haemolytic streptococcus, and a high index of suspicion for the presence of underlying soft-tissue infection is essential in making a prompt diagnosis and initiating treatment. Definitive diagnosis may not always be possible as cultures are often negative, but the majority of causative pathogens include staphylococci and group A  $\beta$ -haemolytic streptococci. We note that back pain secondary to chickenpox infection is extremely unusual and should be considered in the unwell child. Our experience illustrates how such significant collections can be managed successfully with intravenous antibiotics and supportive treatment. A low threshold should nonetheless be maintained for operative drainage and washout should the patient's condition worsen. Close collaboration between paediatricians, radiologists and surgeons is ultimately required to manage such complications of chickenpox infection.

## Acknowledgements

### Conflicts of interest

There are no conflicts of interest.

## References

- Héraud MC, Loriette Y, Grassano A, Magand F, Labbé A. Severe streptococcal complications in varicella. *Arch Pediatr* 1997; **4**:430–432.
- Larcamon JE, Juanco G, Alvarez LA, Pebe FV. Psoas abscess as a chicken pox complication. *Arch Argent Pediatr* 2010; **108**:e86–e88.
- Quach C, Tapiero B, Noya F. Group A streptococcus spinal epidural abscess during varicella. *Pediatrics* 2002; **109**:E14.
- Prais D, Varsano I, Schwarz M, Ofir-Mintzer H, Lazar E. Lung abscess complicating post-varicella pneumonia. *Arch Dis Child* 2002; **87**:110.
- Schreck P, Schreck P, Bradley J, Chambers H. Musculoskeletal complications of varicella. *J Bone Joint Surg Am* 1996; **78**:1713–1719.
- Bin Yap FB, Kiung ST. Adult varicella zoster infection complicated with streptococcal retrosternal abscess. *South Med J* 2009; **102**:653–655.
- Mills WJ, Mosca VS, Nizet V. Orthopaedic manifestations of invasive group A streptococcal infections complicating primary varicella. *J Pediatr Orthop* 1996; **16**:522–528.
- Briard D, Betremieux P, Gandemer V, Lucas MM, Chapuis M, Tréguie C, Pladys P. Severe streptococcal group A infection complicating varicella zoster. *Arch Pediatr* 1998; **5**:754–757.
- Wilson GJ, Talkington DF, Gruber W, Edwards K, Dermody TS. Group A streptococcal necrotizing fasciitis following varicella in children: case reports and review. *Clin Infect Dis* 1995; **20**:1333–1338.
- Gnann JW Jr. Varicella-zoster virus: atypical presentations and unusual complications. *J Infect Dis* 2002; **186**:S91–S98.
- Kernbach-Wighton G, Oehmichen M, Saternus KS. Fatal outcome of varicella in children. *Leg Med (Tokyo)* 2003; **5**:S233–S236.
- Runel-Belliard C, Collet L, Hebert JC. Children's soft tissue infections in tropical countries. Prospective study in Mayotte. *Bull Soc Pathol Exot* 2009; **102**:162–166.
- Gupta AK, Bonajmah AA. Varicella-related musculoskeletal complications in children. *J Pediatr Orthop B* 2011; **20**:264–269.
- Doctor A, Harper MB, Fleisher GR. Group A beta-haemolytic streptococcal bacteraemia: historical overview, changing incidence, and recent association with varicella. *Pediatrics* 1995; **96**:428–433.
- Mikaeloff Y, Kezouh A, Suissa S. Nonsteroidal anti-inflammatory drug use and the risk of severe skin and soft tissue complications in patients with varicella or zoster disease. *Br J Clin Pharmacol* 2008; **65**:203–209.
- Choo PW, Donahue JG, Platt R. Ibuprofen and skin and soft tissue superinfections in children with varicella. *Ann Epidemiol* 1997; **7**:440–445.