

Single-stage repair versus traditional repair of high anorectal malformations, functional results' correlation with Kelly's score and postoperative magnetic resonance imaging findings

A.N. Gangopadhyaya^a, Vijayendra Kumar^a, Vijay D. Upadhyaya^a, Sarita Chowdhary^b, Arvind Srivastava^c, D.K. Gupta^a, Ashish D. Upadhyaya^d, S.P. Sharma^a and S.C. Gopal^a

Introduction Posterior sagittal anorectoplasty (PSARP) is the standard treatment for anorectal malformations. In the present study, the clinical evaluation of anal continence was carried out using Kelly's scoring system and the results of primary PSARP or abdomino-PSARP were compared with the traditional three-stage procedure and the functional outcome was correlated with the findings of MRI, which was used as an objective method of evaluation.

Patients and methods A total of 40 patients with intermediate and high anorectal malformations were studied and were divided into two groups on the basis of a random number table. The patients in group A were treated with a single-stage operation, whereas the patients in group B were treated with a standard staged operation (either PSARP or abdominoperineal pull-through). After clinical evaluation using the Kelly score, patients were divided into three clinical groups irrespective of whether they were operated in one stage or in three stages. All patients were subjected to MRI at the age of 3 years and the findings were correlated with the clinical scoring system.

Result Patients were categorized according to their Kelly's scores as follows: group 1: clinically good (score 5–6); group 2: clinically fair (score 3–4); and group 3: clinically

poor (score 0–2). The proportions of good development of the muscles (puborectalis, external sphincter muscle, and levator muscle hammock) were 78.9% in group 1, 40% in group 2, and none in group 3. Development of muscles was found to be a significant factor for anal continence. Other significant factors for anal continence are rectal diameter and anorectal angle.

Conclusion Clinical assessment using the Kelly score was similar for the single-stage operation and the staged procedure, and this was supported by MRI findings. Therefore, we recommend the single-stage procedure to achieve a better outcome in intermediate and high anorectal malformation. *Ann Pediatr Surg* 9:108–113 © 2013 Annals of Pediatric Surgery.

Annals of Pediatric Surgery 2013, 9:108–113

Keywords: anorectal malformations, MRI, posterior sagittal anorectoplasty

Departments of ^aPediatric Surgery, ^bSurgery, ^cRadiodiagnosis, Institute of Medical Sciences, Banaras Hindu University (BHU), Varanasi and ^dAll India Institute of Medical Sciences (AIIMS), New Delhi, India

Correspondence to Vijayendra Kumar, MD, Department of Pediatric Surgery, Institute of Medical Sciences, Banaras Hindu University (BHU), Varanasi 221005, India
E-mail: upadhyayavj@rediffmail.com

Received 29 February 2012 accepted 29 April 2013

Introduction

Anorectal malformations including an imperforate anus affect ~1/5000 live births. Single-stage abdominoperineal procedures had been performed for many years until the introduction of posterior sagittal anorectoplasty (PSARP) [1,2]. For the high/intermediate types of imperforate anus, poor functional outcome is a major problem for many patients, even after corrective surgery. When compared with the traditional abdominoperineal method, PSARP has been shown to be a superior technique in terms of defecation function [3,4], which may be because of a more precise placement of the pull-through rectocolonic segment within the center of the sphincteric complex. However, a few authors have achieved better results with abdominoperineal pull-through plus PSARP in comparison with PSARP in patients with high defects [5]; others did not find any substantial difference between the results of PSARP and other techniques [6,7]. At our center, we perform single-stage surgery for almost all types of anorectal

malformations, except common cloacae, with satisfactory results [8,9]. In this study, we have compared the functional results of single-stage repair for high and intermediate anorectal malformations with that of the traditional three-stage procedure using Kelly's method of scoring [10] and have correlated the functional outcome with anatomical features of the anorectal region on MRI findings.

Materials and methods

All patients with high or intermediate anorectal malformation admitted during July 2005 to June 2006 were divided into two groups on the basis of a random number table without substitution. A total of 40 patients were studied. The patients in group A were treated with single-stage primary PSARP or combined abdomino-PSARP depending on the site of fistula, whereas patients in group B were treated with conventional staged surgery. The patients with low anorectal malformation and common cloacae were excluded from the study.

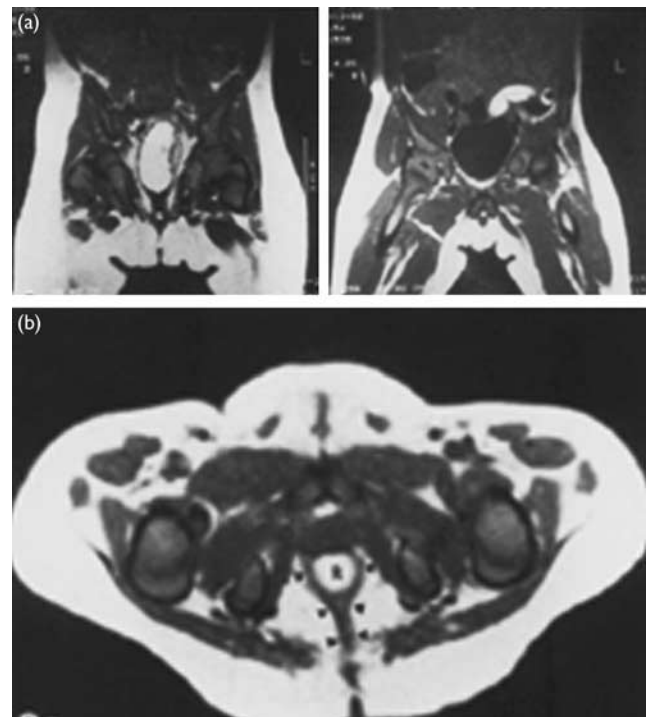
All patients were operated by the same surgeon (patients of group A as well as patients of group B) to avoid any bias. The functional assessment of anal continence was carried out at the age of 3 years using Kelly's method by the senior staff nurse and resident to make the study blind and patients were divided into three groups according to the score: group 1 – good (score 5–6), group 2 – fair (score 3–4), and group 3 – poor (score 0–2). All these patients were then subjected to an MRI scan of the pelvic region at the age of 3 years (assessment of MRI findings of each patient was carried out by two senior radiologists who had no knowledge of the study). MRI was performed using a 0.2T superconductive system; 5–6 mm contiguous sections were obtained using a head or a body coil according to the size of the patient to obtain a sharp image with sharp anatomical detail. T1-weighted images with a spin-echo pulse sequence and a short repetition time (400–600 ms) and echo time (20 ms) were obtained in all patients. T2-weighted images were obtained in selected patients. T1-weighted images are better for morphological description, which is the area of interest of the study. Patients were placed on a liquid diet for 12 h and enema or Dulcolax supplement was administered the night before the procedure. For children younger than 5 years of age or agitated children, an injectable sedative (diazepam/pentazocine/ketamine) was used.

Axial and coronal T-weighted images of the pelvis including the perineal region were obtained in all patients. Sagittal images were obtained in all patients. To facilitate identification of the anus in pulled-through patient, a catheter was placed through the anus in selected patients. The puborectalis (PR) and external sphincter muscle (ESM) was evaluated on an axial MRI image through the symphysis pubis and coccyx and ischial rammi, respectively. The levator muscle hammock (LMH) was evaluated on coronal images (Fig. 1a and b). The following findings were analyzed on the MRI scan.

- (1) the degree of development of the PR and ESM (Fig. 2) and LMH (Fig. 3).
- (2) Symmetry passage of the rectum or pulled-through intestine.
- (3) The angle (anorectal angle) formed when the rectum or pulled-through intestine course was anterior to the PR muscle on sagittal image.
- (4) Rectal diameter.

The PR and ESM were evaluated on an axial MRI through the symphysis pubis and coccyx and ischial rammi, respectively. LMH was evaluated on the coronal image. A score of good (+ +) was assigned if the sphincter muscle of a patient with anorectal malformations (ARM) showed the same development as those without ARM. A score of fair (+) was assigned if sphincter muscles could be nearly identified but less developed. A score of poor (–) was assigned if the sphincter muscles were not identified or barely identified. Statistical analysis was carried out using the χ^2 -test, χ^2 -trend test, and *t* exact test. The control group for the present study included patients of the same age group in whom MRI was performed for some other reason.

Fig. 1

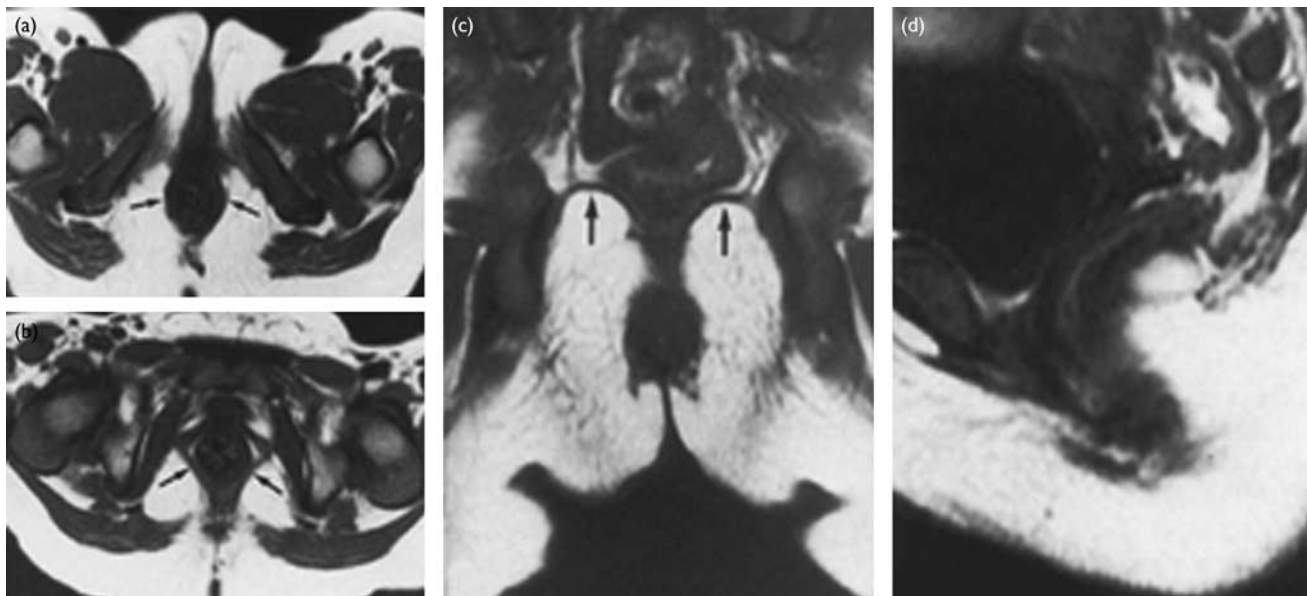


(a) Well-developed sphincter structure of the pelvic floor. (b) Well-developed levator sling.

Results

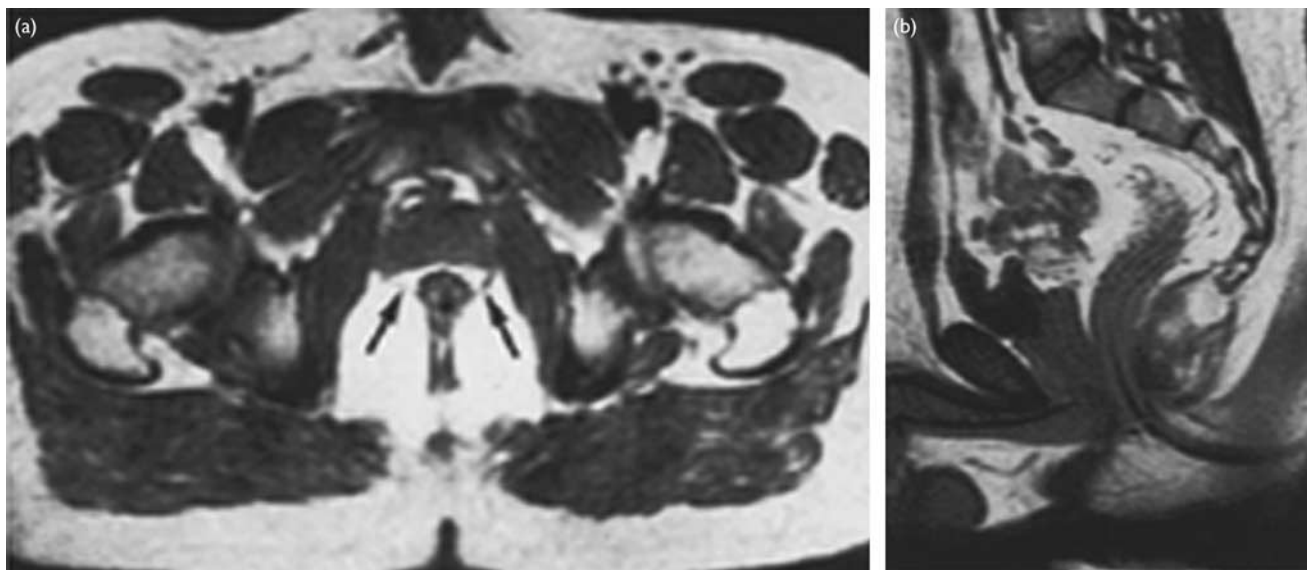
The two groups were comparable in age, sex, body weight, associated anomalies, and time of presentation in hospital. The mean age at the time of definitive operation for patients of group A was 2.4 days (range 1–7 days), whereas it was 269.3 days (range 150–450 days) for patients in group B (out of 20 patients in group B, definitive repair was carried out between 5 and 10 months in 10 patients and between 11 and 15 months in 10 patients). On the basis of Kelly's clinical scoring, patients were divided into the following groups: group 1 (19 patients), group 2 (10 patients), and group 3 (11 patients). It was observed that the 14/20 patients operated before the age of 7 days had good anal continence and were placed in clinical group 1, 4/20 cases were placed in group 2, and 2/20 cases were placed in group 3, whereas in patients on whom definitive repair was performed between 5 and 10 months, 4/10 had a good result, 3/10 had a fair result, and 3/10 had a poor result and were placed in clinical groups 1, 2, and 3, respectively. Among those patients in whom definitive operation was performed after 10 months of age, only 1/10 had a good result, 2/10 had a fair result, and 7/10 had a poor result. High and intermediate ARM was almost equally distributed in these three groups ($P = 0.99$). Associated anomalies were present in 57.5% of patients (Table 1). MRI scan showed that patients in group 1 had well-developed PR muscle (16/19), ESM (13/19), and LMH development (11/19), whereas in the patients in group 2, good development of these muscles was observed in 3/10, 3/10, and 4/10, respectively; in group 3, none of the patients had well-developed muscle (Table 2). The mean value of the

Fig. 2



(a) Axial MRI through the ischial rami showing a normally developed external sphincter muscle (arrows). (b) Axial MRI through the symphysis pubis showing a normally developed puborectalis muscle (arrows). (c) Coronal MRI showing a normally developed levator muscle hammock (arrows). (d) Sagittal MRI showing an anorectal angle of $\sim 95^\circ$. This patient had an intermediate malformation with a Kelly's score of 6.

Fig. 3



(a) Axial MRI showing fair development of the puborectalis muscle (arrows). (b) Sagittal MRI showing an anorectal angle of approximately 110° . This patient had a low malformation with a Kelly's score of 6.

anorectal angle was $110 \pm 10.56^\circ$, $128 \pm 12.94^\circ$, and $138 \pm 14.64^\circ$, respectively, for groups 1, 2, and 3 and the difference was found to be statistically significant ($P = 0.003$). Rectal diameter was 2.36 mm (range 2.3–2.4 mm), 2.65 mm (range 2.52–2.8 mm), and 3.16 mm (range 2.95–3.3 mm), respectively, for groups 1, 2, and 3, and was statistically significant ($P = 0.001$). Comparison of the development of all muscles in patients operated by the single-stage procedure and those operated in three stages (Table 3) showed that greater number of patients operated by single-stage surgery had

well-developed muscles (PR, ESM, and LMH) in comparison with those who were operated in three stages, and this difference was found to be statistically significant. There was no death in the present series.

Discussion

There is a considerable variation in the literature in terms of the functional results after repair of anorectal malformations. This is because of the fact that there is

Table 1 Associated anomalies in two groups

	Group 1	Group 2	Group 3
No other associated anomaly	11	3	3
GU (PUV, hypospadias, vaginal agenesis)	3	2	1
Cardiac anomalies	2	2	0
Vertebral anomalies (sacral agenesis)	3	3	7

The difference in associated anomalies in these three groups was not found to be statistically significant.

Table 2 Distribution of muscle development (MRI finding) in different clinical groups

	Group 1	Group 2	Group 3
Puborectalis muscle (PR) development			
Poor	0	0	5
Fair	4	6	6
Good	15	4	0
External sphincter muscle (ESM) development			
Poor	0	0	7
Fair	5	6	4
Good	14	4	0
Levator muscle hammock (LMH) development			
Poor	0	0	8
Fair	8	6	3
Good	11	4	0

The well-developed PR, ESM, and LMH were associated with good outcome in terms of anal incontinence and this association was found to be statistically significant (the *P* value was 0.002, 0.001, and 0.001, respectively, for PR, ESM, and LMH).

Table 3 Distribution of development of different muscles in patients operated by a single-stage surgery and the conventional three-staged surgery

	<i>n</i> (%)	
	Single-stage procedure	Staged procedure
Levator muscle hammock		
++	12 (60)	3 (15)
+	7 (35)	10 (50)
-	1 (5)	7 (35)
External sphincter		
++	13 (65)	5 (25)
+	5 (25)	10 (50)
-	2 (10)	5 (25)
Puborectalis muscle		
++	14 (70)	5 (25)
+	5 (25)	11 (55)
-	1 (5)	4 (20)

The patients operated by a single-stage surgery had better developed levator muscle hammock, external sphincter muscle, and puborectalis in comparison with patients operated by the conventional three-staged surgery.

no generally agreed method to assess the bowel function of patients with anorectal malformations. The main problem in comparing different series is the highly variable criteria used in the evaluation of fecal continence. The most commonly used classifications are the Kelly score [10], the Templeton score [11], the Holschneider score [12], and the Rintala score [13]. All these classifications ultimately categorize the outcomes as good, fair, or poor. At our center, we use the Kelly score for evaluation of anal continence [8,9]. There are various other methods for objective assessment of the postoperative outcome of ARM. Manometry and electromyography can be used for functional assessment. Manometry has been used for assessment of anal continence; however, there is no standard protocol for manometric

evaluation and the clinical results and the manometric findings are often been found to be contradictory. Some investigators have found a positive correlation between clinical continence and the anal resting pressure profile [13,14], whereas others have reported no correlation at all between clinical continence and pressure profile or squeeze force [15]. Of available and relevant imaging modalities, MRI is considered superior, because of excellent soft tissue characterization, multiplanar imaging, and lack of ionizing radiation. Few studies had been carried out for structural assessment of sphincters with computed tomography scan [16–18] and discovered a correlation between the computed tomography findings and the clinical picture. Fukuya *et al.* [19], in their study of postoperative MRI evaluation of anorectal malformations with clinical correlation, reported that hypoplastic sphincteric complex, misplacement of the bowel in relation to the sphincter, and obtuse anorectal angle are related to a poor outcome. In the present study, we have evaluated the muscle (PR, ESM, and LMH), anorectal angle, and rectal diameter for evaluation of pelvic anatomy in operated patients with anorectal malformation and have correlated it with clinical evaluation.

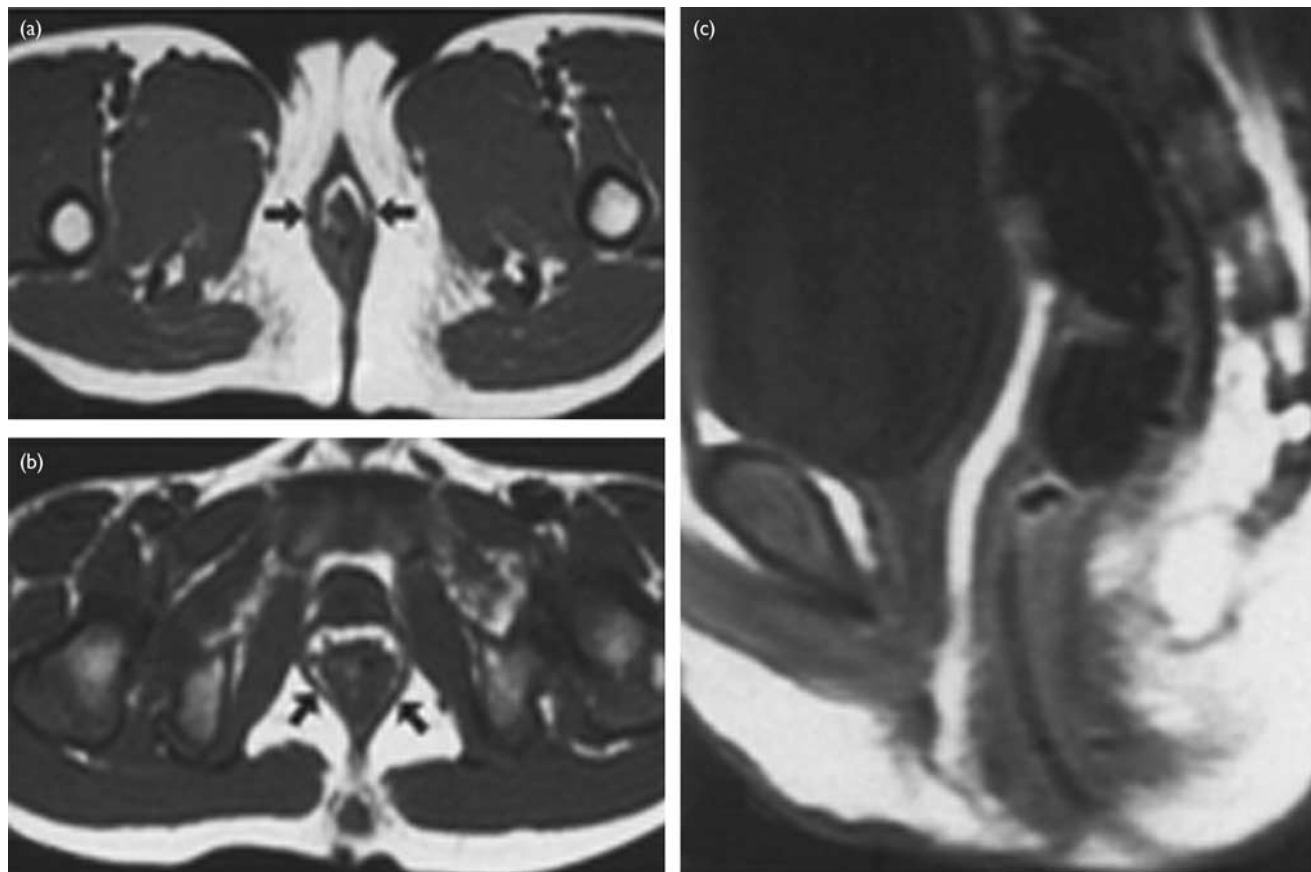
On clinical evaluation using the Kelly score, 70% (14/20) of patients operated in a single stage were placed in clinical group 1, 20% of patients in group 2, and only 10% of patients in group 3, whereas of the patients operated in three stages, only 25% of patients were placed in group 1, 30% in group 2, and 45% (9/20) cases in group 3.

It was observed that most of the patients (14/20) in whom definitive repair was performed at the age of 7 days or less were placed in clinical group 1 and in patients in whom definitive repair was performed after the age of 10 months, most (7/10) were placed in group 3. On statistical analysis, the odds ratio of the groups were 1, 3.5, and 13.5 for patients who underwent definitive repair after the age of 10 months, 5–10 months, and less than 7 days, respectively (*P* = 0.01), which shows that if the likelihood of having good anal continence is 1 in patients with definitive repair after 10 months, the likelihood of a good result will be 3.5 and 13.5 times higher for patients subjected to definitive repair at the age of 5–10 months and less than 7 days, respectively. These findings suggest that early age of definitive repair results in better outcome in terms of anal continence.

In the present study, it was observed that patients with well-developed pelvic muscle had better outcome in terms of anal continence. This suggests that the better development of each muscle (PR, ESM, and LMH) was associated with better outcomes in terms of anal continence in postoperative cases of anorectal malformation and this association was statistically significant (*P* = 0.001). Our findings are similar to those of Kiesewetter *et al.* [20], who concluded that PR muscle is important for anal continence, and of Pena [21], who suggests that electromyography is a significant factor for anal continence.

Patients with lower obtuse anorectal angle ($110 \pm 10.56^\circ$) had better anal continence and this association was found to be statistically significant (*P* = 0.003), which suggests

Fig. 4



Axial MRI showing normal development of the external sphincter (arrows) (a) and puborectalis (arrows) (b) muscles. (c) Sagittal MRI showing a wide anorectal angle ($\sim 136^\circ$). This patient had a high malformation with a Kelly's score of 4.

that anorectal angle is a significant factor for anal continence, which is in contrast to the finding of Fukuya *et al.* [19].

Asymmetry of pulled bowel was associated with poor outcome in terms of anal continence, but this association was not significant, and hence suggests that asymmetry of pulled bowel is not a significant factor for anal continence, which is in contrast to the finding of Wong *et al.* [22], who concluded that asymmetry for pulled bowel is a significant factor for anal continence.

Patients with a rectal diameter of 2.36 mm (range 2.3–2.4 mm) had better anal continence in comparison with patients with a rectal diameter of 3.16 mm (range 2.95–3.3 mm), and the difference was found to be statistically significant ($P = 0.001$), which is similar to the finding of Singh *et al.* [23].

Another advantage of MRI is that it may also aid diagnosis of spinal cord deformity such as tethering cord if present and also aid decision making of a redo operation.

The present study showed that most of the patients operated in a single stage had better anal continence (70%), and there were more patients with a well-developed muscle complex (PR – 70%, electromyography – 65%, and LMH – 60%) compared with those operated

in three stages. Sixty-five percent patients who underwent single-stage surgery had a rectal diameter of 2.36 mm (range 2.3–2.4 mm), whereas only 30% of patients operated in three stages had the same rectal diameter.

The finding in the present study suggests that an MRI scan can help properly delineate the anatomy of soft tissue of the pelvic region and aids proper assessment of the postoperative outcome of anorectal malformation and its findings correlate well with clinical evaluation. The clinical evaluation showed that single-stage treatments for anorectal malformation lead to similar if not better results than those of a conventional multistage approach in terms of anal continence and this was supported by MRI findings.

Conclusion

We suggest that an MRI scan is a good objective method for the postoperative evaluation of anorectal malformation and its finding correlates with the clinical evaluation. Second, we suggest that if definitive repair is performed earlier (single-stage operations), similar if not better results than those of the conventional multistage approach may be achieved, and hence the trend for anorectal malformation may move toward a single-stage operation rather than the conventional three-stage operation (Fig. 4).

Acknowledgements

Conflicts of interest

There are no conflicts of interest.

References

- 1 Rebein F. Imperforate anus; experiences with abdomino-perineal and abdomino-sacro-perineal pull-through procedures. *J Pediatr Surg* 1967; **2**:99–105.
- 2 DeVries P, Peña A. Posterior sagittal anorectoplasty. *J Pediatr Surg* 1982; **17**:638–643.
- 3 RATM Langemeijer, Molenaar JC. Continence after posterior sagittal anorectoplasty. *J Pediatr Surg* 1991; **26**:587–590.
- 4 Rintala RJ, Lindahl HG. Fecal continence in patients having undergone posterior sagittal anorectoplasty procedure for a high anorectal malformation improves at adolescence, as constipation disappears. *J Pediatr Surg* 2001; **36**:1218–1221.
- 5 Gil-Vernet JM, Asensio M, Marhuenda C, Broto J, Wayar A. Nineteen years experience with posterior sagittal anorectoplasty as a treatment of anorectal malformation. *Cir Pediatr* 2001; **14**:108–111.
- 6 Bliss DP Jr, Tapper D, Anderson JM, Schaller RT Jr, Hatch EI, Morgan A, et al. Does posterior sagittal anorectoplasty in patients with high imperforate anus provides superior fecal continence? *J Pediatr Surg* 1996; **31**:26–30.
- 7 Mulder W, de Jong E, Wauters I, Kinders M, Heij HA, Vos A. Posterior sagittal anorectoplasty: functional results of primary and secondary operations in comparison to the pull-through method in anorectal malformations. *Eur J Pediatr Surg* 1995; **5**:170–173.
- 8 Gangopadhyay AN, Gopal SC, Sharma S, Gupta DK, Sharma SP, Mohan TV. Management of anorectal malformations in Varanasi, India: a long-term review of single and three stage procedures. *Pediatr Surg Int* 2006; **22**:169–172.
- 9 Upadhyaya VD, Gopal SC, Gupta DK, Gangopadhyaya AN, Sharma SP, Kumar V. Single stage repair of anovestibular fistula in neonate. *Pediatr Surg Int* 2007; **23**:737–740.
- 10 Ong NT, Beasley SW. Comparison of clinical methods for the assessment of continence after repair of high anorectal anomalies. *Pediatr Surg Int* 1990; **5**:233–237.
- 11 Templeton JM, Ditesheim JA. High imperforate anus – quantitative result of long-term fecal continence. *J Pediatr Surg* 1985; **20**:645–652.
- 12 Holschneider AM. *Elektromanometrie des Enddarms*. Munich: Urban & Schwarzenberg; 1983. pp. 213–218.
- 13 Rintala RJ, Lindahl H. Is normal bowel function possible after repair of intermediate and high anorectal malformations. *J Pediatr Surg* 1995; **30**:491–494.
- 14 Hedlund H, Peña A, Rodriguez G, Maza J. Long-term anorectal function in imperforate anus treated by a posterior sagittal anorectoplasty: manometric investigation. *J Pediatr Surg* 1992; **27**:906–909.
- 15 Doolin EJ, Black CT, Donaldson JS, Schwartz D, Raffensperger JG. Rectal manometry, computed tomography and functional results of anal atresia surgery. *J Pediatr Surg* 1991; **28**:195–198.
- 16 Taccone A, Martucciello G, Fondetli R, Doderio P, Ghiorzi M. CT of anorectal malformation: a postoperative evaluation. *Pediatr Radiol* 1989; **19**:375–376.
- 17 Armbjornsson E, Laurin S, Mikaelsson C. Computed tomography of anorectal anomalies: correlation between radiologic findings and clinical evaluation of faecal incontinence. *Acta Radiol* 1989; **130**:25–28.
- 18 Vade A, Reyes H, Wilbur A, Gyi B, Spigos D. The anorectal sphincter after rectal pull-through surgery for anorectal anomalies: MRI evaluation. *Pediatr Radiol* 1989; **19**:179–183.
- 19 Fukuya T, Honda H, Kubota M, Hayashi T, Kawashima A, Tateshi Y, et al. Postoperative MRI evaluation of anorectal malformations with clinical correlation. *Pediatr Radiol* 1993; **23**:583–586.
- 20 Kiesewetter WB. Rectum and anus. In: Ravitch MM, Welch KJ, Benson OD, Aberdeen E, Randolph JG, editors. *Pediatric surgery (year book)*. 3rd ed. Chicago: Yearbook Medical Publishers; 1979. p. 1059.
- 21 Pena A. Posterior sagittal approach for the correction of anorectal malformations. In: Mannick JA, Cameron JL, Jordan GL Jr, Maclean LD, Shires GT, Thompkins RK, et al., editors. *Advances in surgery (year book)*. Chicago: Yearbook Medical Publishers; 1986; p. 69.
- 22 Wong KK, Khong PL, Lin SC, Lam WW, Lan LC, Tam PK. Post-operative magnetic resonance evaluation of children after laparoscopic anorectoplasty for imperforate anus. *Int J Colorectal Dis* 2005; **20**:33–37.
- 23 Singh SJ, Gibbons NJ, Vincent MV, Sithole J, Nwokoma NJ, Alagarwami KV. Use of pelvic ultrasound in the diagnosis of megarectum in children with constipation. *J Pediatr Surg* 2005; **40**:1941–1944.