

# Fistulotomy versus fistulectomy as a treatment for low anal fistula in infants: a comparative study

Ahmed M.A. Ali Gafar

**Objective** To compare between two methods of surgical treatment for fistula-in-ano (FIA) in infants, fistulotomy and fistulectomy, and their surgical outcome and also to review the clinical presentation and diagnosis of this condition in our tertiary center.

**Background** FIA occurring in infants is a relatively common condition. It is more common in boys than in girls, and 96% of cases occur in infants younger than 1 year. The surgical treatment options of these fistulas are fistulotomy or fistulectomy.

**Patients and methods** In this study, between January 2010 and December 2011, 36 infants with low-type FIA were treated surgically. Eighteen infants were treated by fistulotomy (group A) and 18 were treated by fistulectomy (group B). No infant had underlying illness. All cases were subjected to the same protocol of preoperative evaluation, anesthesia, and follow-up protocol. The two techniques were compared in terms of the operative time, healing time, complications, and outcome. All were reported, analyzed, and compared.

**Results** Male sex predominance was reported. Twenty-seven infants were younger than 1 year old and the remaining patients were in their second year of life, with a mean age of  $9.7 \pm 4.9$  months. The mean values of healing

time were  $21 \pm 3.01$  days for group A (range 17–28 days) and  $26.6 \pm 1.42$  days for group B (range 25–30 days). There was a statistically significant difference between the two groups in both the operative time and the healing time. There was one recurrence and one granuloma in group B. One wound infection was reported in patients who underwent fistulotomy (group A).

**Conclusion** The treatment of FIA in infants remains controversial and it can be treated either by fistulotomy or by fistulectomy. However, there are fewer risks and shorter recovery times associated with fistulotomy as compared with fistulectomy. A future study involving nonoperative management would be required to assess other treatment options. *Ann Pediatr Surg* 9:103–107 © 2013 Annals of Pediatric Surgery.

*Annals of Pediatric Surgery* 2013, 9:103–107

**Keywords:** fistula-in-ano, fistulectomy, fistulotomy

Department of Surgery, Pediatric Surgery Unit, Faculty of Medicine, Sohag University, Sohag, Egypt

Correspondence to Ahmed M.A. Ali Gafar, MD, Department of Surgery, Pediatric Surgery Unit, Sohag University Hospitals, Faculty of Medicine, Sohag University, Sohag, Egypt

Tel: +20 932 323 228; fax: +20 934 602 963; e-mail: agafar3@yahoo.com

Received 30 November 2012 accepted 5 April 2013

## Introduction

Fistula-in-ano (FIA) is an abnormal connection between the inner surface of the anal canal and the perineal skin [1]. It is a relatively common condition in infants [2]. The etiology of perianal abscess (PAA) and FIA in infants has been a subject of controversy. FIA may be congenital or acquired [3]. PAA is considered as a precursor to FIA or both PAA and FIA are considered as two distinct entities [4]. It is unclear why some PAA form fistulas whereas others do not [5]. However, PAA in infants who are younger than 12 months is associated with a 20–80% overall rate of progression to FIA [6,7].

Although the pathogenesis of FIA is not fully understood, it has certain characteristics that distinguish this condition from that of adults [8,9]. The clinical characteristics of FIA in infants are different from those of older children [10]. With the exception of those with inflammatory bowel diseases, infants with FIA generally do not have underlying medical conditions and it is usually first noticed during a diaper change [11]. The usual presentation involves a recurrent PAA and an external opening that may be discharging a purulent material [4]. No specific laboratory or imaging studies are necessary for the evaluation of otherwise healthy infants with FIA.

The treatment of FIA remains controversial. Antibiotics are frequently initiated by pediatricians before surgical

referral [5]. Surgical management is the widely accepted method for treatment and includes fistulotomy or fistulectomy [9,12]. Complications of surgical management include recurrence, delayed and/or impaired healing, and bleeding [13]. Our objectives are to compare between fistulotomy and fistulectomy as a treatment of FIA in infants and their surgical outcome.

## Patients and methods

This comparative study was carried out at the pediatric surgery unit, Sohag university hospitals, a local health insurance hospital, and private sector, Sohag, Egypt from January 2010 to December 2011. Ethical committee approval was obtained and counseling of the parents was performed.

Infants with FIA were prospectively randomized to undergo fistulotomy (18 patients, group A) or fistulectomy (18 infants, group B) and surgically managed by a single pediatric surgeon. Infants (< 2 years old) with low FIA were enrolled in the study after the parents signed an informed consent. Exclusion criteria included infants with systemic diseases, inflammatory bowel disease, high fistula, and recurrent lesion; infants who were lost to follow-up were also excluded from the study.

Diagnosis was mainly clinical and routine laboratory studies were performed. Radiological examination and

histopathological study of tissue obtained at operation were sometimes performed (Figs 1–3).

Preoperative preparation consisted of bowel preparation as one enema (20 ml/kg warm saline) the previous day and 4 h before the operation to clean the anus and rectum. Eating of solid food was avoided for 6 h and fluids for 3 h before surgery. Prophylactic antibiotic and prophylactic analgesia were used routinely.

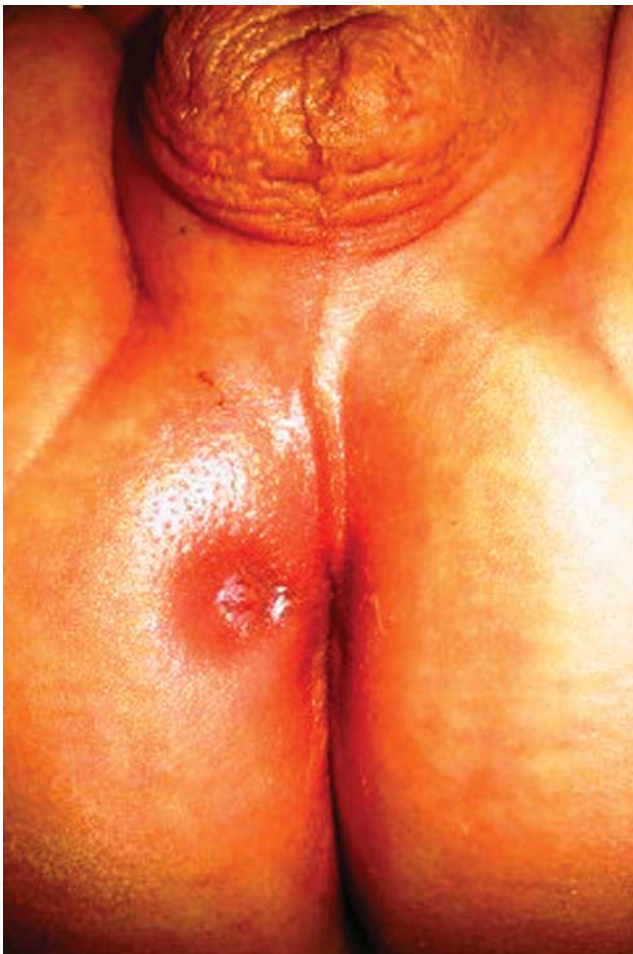### Surgical techniques

Either a fistulotomy or a fistulectomy was performed; both were carried out under general anesthesia. The patient was positioned in the lithotomy position and at the end the wound was packed with gauze soaked in povidone iodine 10%.

### Fistulotomy

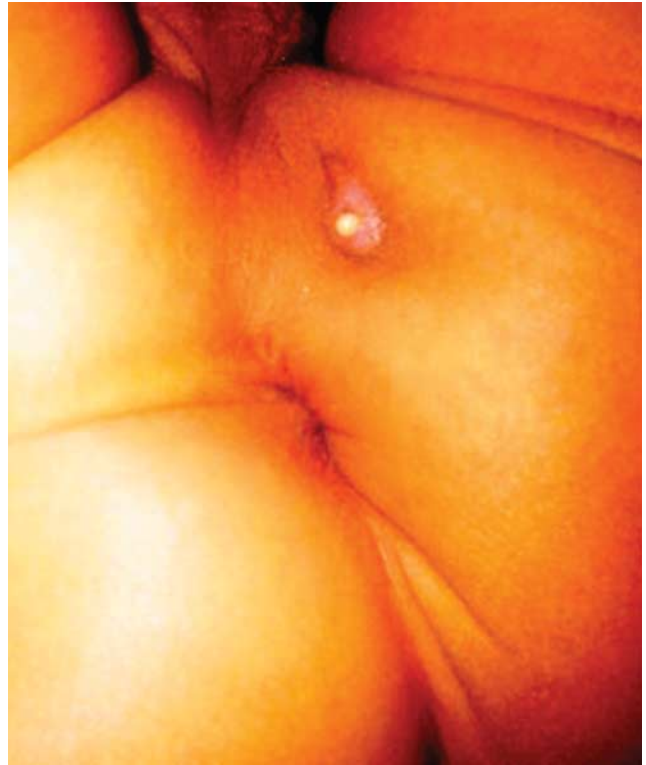The fistulous opening was identified within the anal canal and a probe was passed gently from the skin side into the anal lumen. The fistulous tract was opened up completely over the probe with a fine needle-tip electrocautery (Figs 4 and 5).

Fig. 1



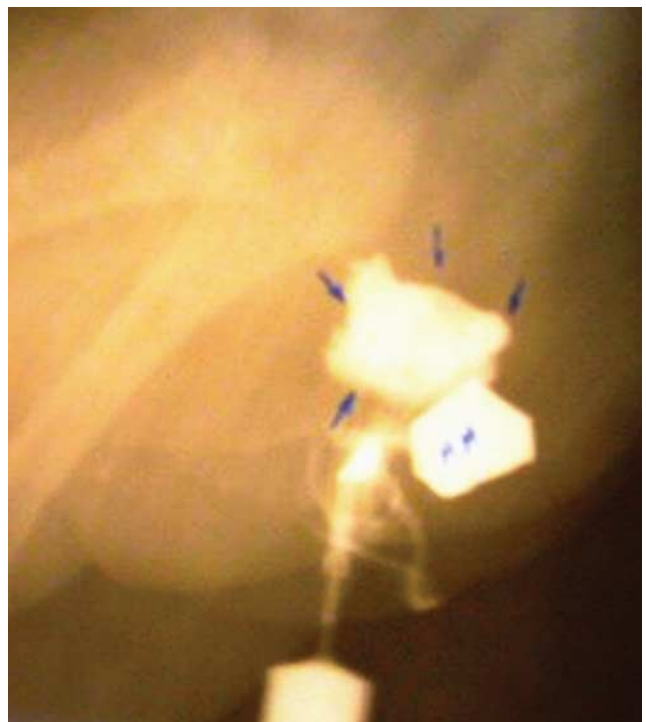FIA: external opening. FIA, fistula-in-ano.

Fig. 2



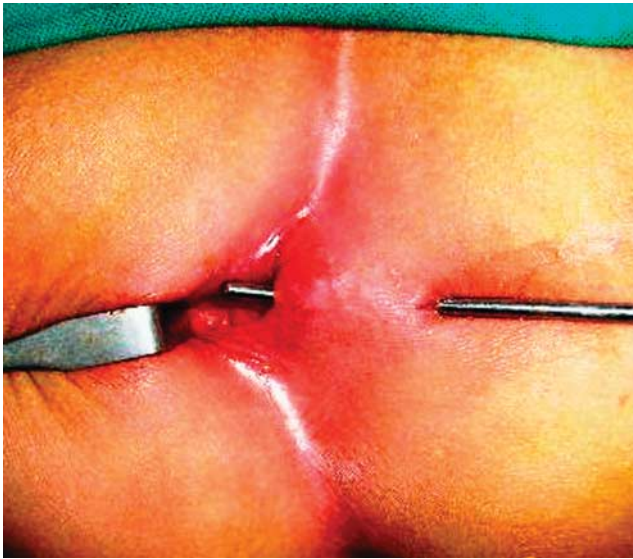
Presentation with purulent discharge.

Fig. 3



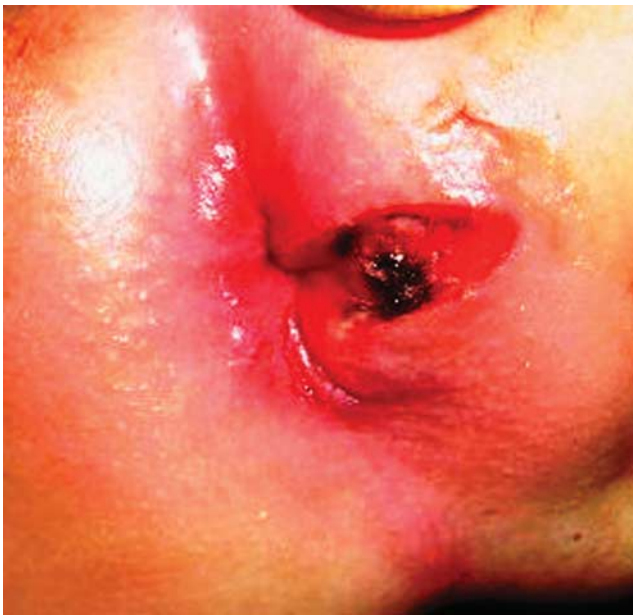
Fistulogram: low FIA. FIA, fistula-in-ano.

Fig. 4



Fistulotomy: probing.

Fig. 5



Fistulotomy: postoperative wound.

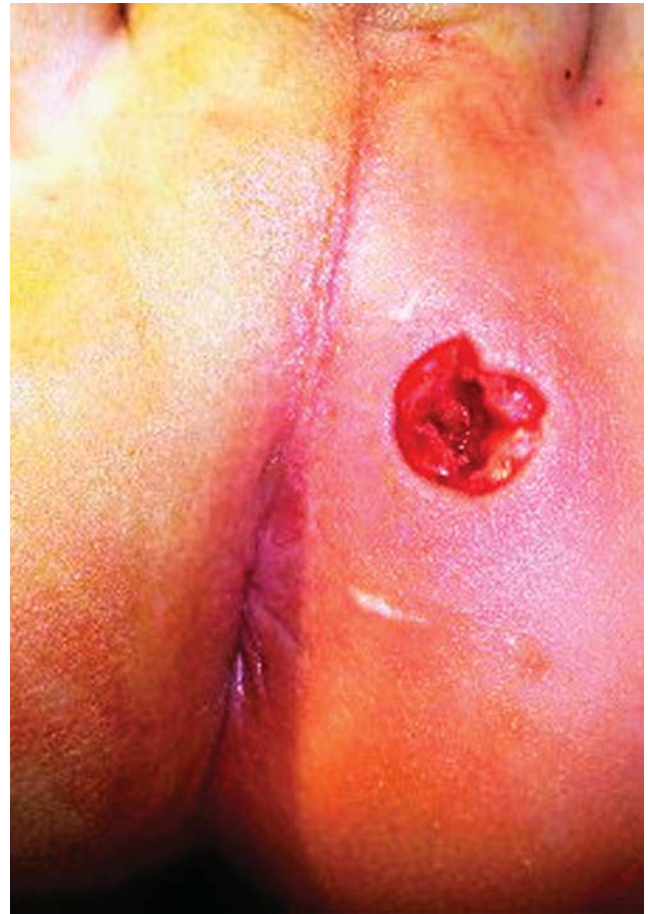### **Fistulectomy**

The fistula tract was dissected from all sides by sharp dissection with scissors or diathermy from the external opening to the internal opening (Fig. 6).

### **Postoperative management**

Postoperative pain control, antibiotics (appropriate broad-spectrum antibiotics, effective against gram-negative enteric bacilli, gram-positives, and anaerobes), and surgical dressing were used. Parents were counseled that a drop of blood in the diaper or dressing is not unusual but persistent bleeding is a problem and requires medical attention. Patients were discharged home on the first

Fig. 6



Fistulectomy: postoperative wound.

postoperative day. Babies were given a brief warm bath after every bowel movement to ensure local hygiene. The wound was cleaned and lightly packed with gauze soaked in povidone iodine 10% or native honey to allow gradual filling of the cavity by granulation tissue; thus, the wound was allowed to heal by secondary intention.

Patients were followed up weekly until the wound had healed completely and monthly thereafter until 4 months had passed without any evidence of recurrence.

Randomization was carried out using closed envelopes before surgery at the time of admission in hospital. Demographic information of the patients, symptoms, and localization of the lesion were recorded and analyzed. Operative time, healing time, and complication rate all were recorded and compared. Statistical analysis of data was carried out using SPSS (Chicago, Illinois, USA) and data were summarized and expressed with percentages, means  $\pm$  SD, and the level of statistical significance was set at  $P$  equal to 0.05.

### **Results**

Thirty-six infants with low FIA were included and were subjected to either fistulotomy or fistulectomy. The most commonly affected site was in the 3 O'clock direction with 15 (41.7%) lesions, followed by the 9 O'clock direction in 12 (33.3%) patients. Twenty-three of these



29 patients had received previous surgical drainage for PAA (nine patients in our hospitals and 14 elsewhere); the remaining six patients had received nonoperative management. Demographic and other baseline characteristics are presented in (Table 1).

The mean values for operative time were  $13.9 \pm 1.76$  min for group A (range 12–18 min) and  $15.9 \pm 0.94$  min for group B (range 15–18 min).

The overall complication rate for group A was documented in one patient (5.6%) and it was reported in two patients (11.1%) in group B. There was one wound infection in a patient in group A that was treated conservatively. One patient experienced granuloma in group B. Recurrence was observed in one patient (5.6%) in group B who was 20 months old and had a previous history of nonoperatively treated PAA. This patient underwent fistulotomy 4 months later and was completely cured after the second operation. Intraoperative and postoperative bleeding was negligible and usually controlled by diathermy or compression. Histopathological examination of tissue obtained was performed in two cases and indicated no specific inflammatory cells and no evidence of specific granuloma.

The mean values of healing time were  $21 \pm 3.01$  days for group A (range 17–28 days) and  $26.6 \pm 1.42$  days for group B (range 25–30 days).

The statistical analysis showed that there was a statistically significant difference ( $P = 0.00$ ) between the two groups in both the operative time and the healing time (Table 2).

Although there was a numerical difference between the two groups as regards the complication rate, it was statistically insignificant ( $P = 0.5$ ) (Table 3).

## Discussion

In 2011, Carmona *et al.* [1] documented in his case series a male predominance in 94.1% of cases. Other studies reported incidences of male predominance varying from 75 to 100% [2,5,10,14–16], which is in agreement with our results.

The disease was presented before the age of 1 year in 87.1% of infants [17]. Chang *et al.* reported in 2010 that the mean age of the presented infants was  $6 \pm 4.5$  months [14].

The usual presentation involves intermittent relapse of inflammation with purulent discharge, perianal pruritis, and granuloma [2].

Lesion localization and characteristics vary in the literature; lesions were right sided in 62.5% and left sided in 22.5% of cases [18] and all patients with FIA had been treated previously for PAA [19]. In a case series of 17 patients, lesions were located on the right side in 31.25%, on the left side in 18.75%, and were preceded by PAA in 25% of cases [1]. This is almost consistent with our results.

In our study, the mean operative time was shorter for group A and this may be attributed to the simpler technique and less time taken to control bleeding,

**Table 1 Demographic and other baseline characteristics**

	N (%)
Sex	
Male	34 (94.4)
Female	2 (5.6)
Age at presentation	
Mean	$9.7 \pm 4.9$ months
First year	27 (75)
Second year	9 (25)
Symptoms	
Discharge	33 (91.6)
Granuloma	23 (63.8)
Irritability	9 (25)
Anal pruritis	4 (11.1)
Past history of PAA	29 (80.6)
Lesion site	
Right side	20 (55.6)
Left side	16 (44.4)

PAA, perianal abscess.

**Table 2 Comparing the mean values between the two groups in terms of both operative time and healing time using independent t-test**

	Group A (N=18)	Group B (N=18)	P value
Operative time/min			
Mean	13.9444	15.9444	0.00
SD	1.7648	0.9376	
Healing time/day			
Mean	21	26.6	0.00
SD	3.01	1.42	

$P = 0.00$ , very highly statistically significant difference.

**Table 3 Postoperative complications using the  $\chi^2$ -test for comparison between the two groups for complications**

	Group A (N=18)	Group B (N=18)
Wound infection	1	–
Granuloma	–	1
Recurrence	–	1
Total	1	2

$P = 0.5$ , statistically insignificant difference.

especially using needle diathermy. Our results are in agreement with those of many studies in the literature.

Postoperative complications such as wound infection, recurrence, and other complications were reported in the literature with variable incidence. Wound infection and granuloma were reported at a rate of 2.8% for each [20]. Oh *et al.* (2001) reported that none of the patients who underwent fistulotomy had recurrent fistula during an average follow-up of 25.4 months [2]. However, in 2010, Jun [10] reported a recurrence rate of 4.5% in surgically treated FIA, whereas other authors reported a recurrence rate up to 13% [9].

However, many reviews have reported no recurrence of FIA after either fistulotomy or fistulectomy [1,14,19]. Novotny *et al.* [13] reported that recurrence is more likely in older children and in children who had previous episodes of PAA or if pus was noted at the time of surgery. Our results are in agreement with those of many authors.

The average healing time after fistulotomy was found to be shorter than that after fistulectomy in the general population [21]. In our study, the shorter healing time in group A may be attributed to less tissue loss than that in group B.

## Conclusion

Although FIA in infants can be treated either by fistulotomy or by fistulectomy, its treatment remains controversial and fistulotomy is still considered the standard surgical treatment. Fistulotomy is simple and results in shorter operative time, lesser recurrence rate, and earlier wound healing as compared with fistulectomy.

## Acknowledgements

### Conflicts of interest

There are no conflicts of interest.

## References

- 1 Carmona J, Osterman A, Lugo Vicente H. Fistula-in-ano in children: a case series. *Bol Asoc Med P R* 2011; **103**:14–17.
- 2 Oh J-T, Han A, Han SJ, Choi SH, Hwang EH. Fistula-in-ano in infants: is nonoperative management effective? *J Pediatr Surg* 2001; **36**:1367–1369.
- 3 Shafer AD, McGlone TP, Flanagan RA. Abnormal crypts of Morgagni: the cause of perianal abscess and fistula-in-ano. *J Pediatr Surg* 1987; **22**:203–204.
- 4 Gupta PJ. Anal fistulotomy using radiowaves – long-term outcome. *Acta Chir Iugosl* 2008; **55**:115–118.
- 5 Christison-Lagay ER, Hall JF, Wales PW, Bailey K, Terluk A, Goldstein AM, et al. Nonoperative management of perianal abscess in infants is associated with decreased risk for fistula formation. *Pediatrics* 2007; **120**:e548–e552.
- 6 Macdonald A, Wilson-Storey D, Munro F. Treatment of perianal abscess and fistula-in-ano in children. *Br J Surg* 2003; **90**:220–221.
- 7 Piazza DJ, Radhakrishnan J. Perianal abscess and fistula-in-ano in children. *Dis Colon Rectum* 1990; **33**:1014–1016.
- 8 Longo WE, Touloukian RJ, Seashore JN. Fistula in ano in infants and children: implications and management. *Pediatrics* 1991; **87** (1): 737–739.
- 9 Festen C, Van Harten H. Perianal abscess and fistula-in-ano in infants. *J Pediatr Surg* 1998; **33**:711–713.
- 10 Jun SY. Fistula-in-ano in children less than 2 years of age. *J Korean Assoc Pediatr Surg* 2010; **16**:170–176.
- 11 Rosen NG, Gibbs DL, Soffer SZ, Hong A, Sher M, Peña A. The nonoperative management of fistula-in-ano. *J Pediatr Surg* 2000; **35**: 938–939.
- 12 Al-Salem AH, Laing W, Talwalker V. Fistula-in-ano in infancy and childhood. *J Pediatr Surg* 1994; **29**:436–438.
- 13 Novotny NM, Mann MJS, Rescorla FJ. Fistula in ano in infants: who recurs? *Pediatr Surg Int* 2008; **24**:1197–1199.
- 14 Chang HK, Ryu JG, Oh J-T. Clinical characteristics and treatment of perianal abscess and fistula-in-ano in infants. *J Pediatr Surg* 2010; **45**:1832–1836.
- 15 Afşarlar ÇE, Karaman A, Tanır G, Karaman I, Yılmaz E, Erdoğan D, et al. Perianal abscess and fistula-in-ano in children: clinical characteristic, management and outcome. *Pediatr Surg Int* 2011; **27**:1063–1068.
- 16 Ezer SS, Oguzkurt P, Ince E, Hiçsönmez A. Perianal abscess and fistula-in-ano in children: aetiology, management and outcome. *J Paediatr Child Health* 2010; **46**:92–95.
- 17 Meyer T, Weinger M, Höcht B. Perianal abscess and anal fistula in infancy and childhood: a congenital etiology? *Chirurg* 2006; **77**:1027–1032.
- 18 Al-Salem AH, Qaisaruddin S, Qureshi SS. Perianal abscess and fistula in ano in infancy and childhood: a clinicopathological study. *Pediatr Pathol Lab Med* 1996; **16**:755–764.
- 19 Serour F, Somekh E, Gorenstein A. Perianal abscess and fistula-in-ano in infants: a different entity? *Dis Colon Rectum* 2005; **48**:359–364.
- 20 Poenaru D, Yazbeck S. Anal fistula in infants: etiology, features, management. *J Pediatr Surg* 1993; **28**:1194–1195.
- 21 Bhatti Y, Fatima S, Shaikh GS, Shaikh S. Fistulotomy versus fistulectomy in the treatment of low fistula in ano. *Rawal Med J* 2011; **36**:284–286.