

# Absent testis: does it exist in 46,XY males?

Mohamed Amin ElGohary

**Aim** To challenge the concept of genetically absent testis in normal 46,XY males.

**Background** The term absent testes has been used in the literature to denote vanishing testis, atrophied testis, nubbin of testicular tissue, or genetically absent testes. When no testicular tissues are found during diagnostic laparoscopy, the vas and testicular vessels are traced as leading points for testicular localization, and if both end blindly at a closed ring, vanishing testis is diagnosed. When the vas and vessels are seen entering the canal, a testicular nubbin may be present at the end of the epididymis.

**Methods** Both Mullerian inhibitory factor and testosterone act locally as paracrine hormones. Unilateral absent testis should be associated with an ipsilateral persistent of Mullerian tissues. Individuals with bilateral testicular agenesis will develop into a phenotypic female with persistent Mullerian structures.

**Results** The absence of Mullerian structures in patients with impalpable testis means that there has been a

functional testis that survived well beyond the ninth week of gestation. We have encountered testicles at the subrenal position after an initial laparoscopic finding of an absent.

**Conclusion** Based on embryological process of testicular development and testicular descent, agentic absent testis cannot exist. Therefore we strongly recommend to re-scope all patients who were initially diagnosed as absent testis to look for a hidden testis at the initial site of development and along the line of descent. *Ann Pediatr Surg* 9:79–80 © 2013 Annals of Pediatric Surgery.

*Annals of Pediatric Surgery* 2013, 9:79–80

**Keywords:** absent testis, undescended testis, vanishing testis

Al Noor Hospital, Abu Dhabi, UAE

Correspondence to Mohamed Amin ElGohary, FRCS, Al Noor Hospital, PO Box 48481, Abu Dhabi, UAE  
Tel: +971 506 225 532; fax: +971 249 44470; e-mail: amingoh@gmail.com

Received 19 August 2012 accepted 1 January 2013

## Introduction

Normal testicular development and descent depends on a complex interaction among endocrine, paracrine, growth, and mechanical factors. Bipotential gonadal tissues begin differentiation into a testis during the sixth and seventh weeks of gestation under the effects of the testis-determining *SRY* gene. At the eighth week of gestation, Sertoli cells appear and produce Müllerian inhibitory substance. By the 10th week, Leydig's cells produce androgens and insulin-like factor 3. Agenetic testes in a 46,XY individual do occur if the gonadal ridge fails to form or its blood supply fails to develop. Both Müllerian inhibitory factor and testosterone act locally as paracrine hormones. Unilateral absent testis should be associated with an ipsilateral persistent of Müllerian tissues. Individuals with bilateral testicular agenesis will develop into a phenotypic female with persistent Müllerian ducts [1,2].

## Discussion

### Absent testis during groin exploration

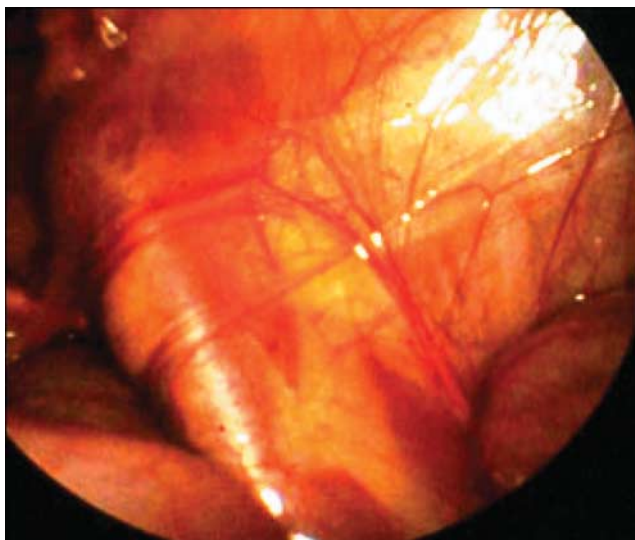
As the vas and epididymis develop embryologically separate from the testis [3], finding the vas and epididymis with no testicular vessels does not exclude an existing testis along the line of descent or merely separated from the vas. Testicular epididymal separation allowing epididymis to elongate and descent into the scrotum without associated testicular descent is a known phenomenon [4], and there are rare situations of complete urogenital nonunion in which there is no communication between the descended epididymis and the undescended testis (UDT) [5,6,7]. Limited groin

exploration in those cases will miss an intra-abdominal testis, and label the finding as an absent testis.

### Absent testis during diagnostic laparoscopy

When no testis identified during laparoscopy, the vas and the testicular vessels are traced as leading points for testicular localization. The testicular vessels are the primary landmark for testicular localization [8,9]. Visualization of well-developed spermatic vessels predicts the presence of a good-sized testis, whereas poor blood supply is invariably associated with poorly developed or atrophied testes. If no testes are identified, one is left with the possibility of vanishing or absent testes. Vanishing abdominal testes are readily diagnosed when a blind-ending vas meets a leach of flimsy testicular vessels, and are considered to result from a prenatal vascular accident or intrauterine testicular torsion (Fig. 1). Agenetic testes in a 46,XY individual do occur if the gonadal ridge fails to form or its blood supply fails to develop. Individuals with bilateral testicular agenesis or those individuals in whom the testes are lost before the ninth week of gestation will develop into a phenotypic female with persistent Müllerian ducts. In unilateral cases of an absent testis, an ipsilateral Müllerian structure will be present because of failure of secretion of the paracrine (MIH). The key clinical sign indicating testicular agenesis rather than a vanished testis is the presence of Müllerian structures. UDT is known to be associated with varying degrees of dysgenesis. The higher the testis, the worse the histology. Although the lack of germ cells is a common finding in abdominal testes, the Sertoli cells that secrete Müllerian inhibitory substance are usually present. However, under these circumstances,

Fig. 1



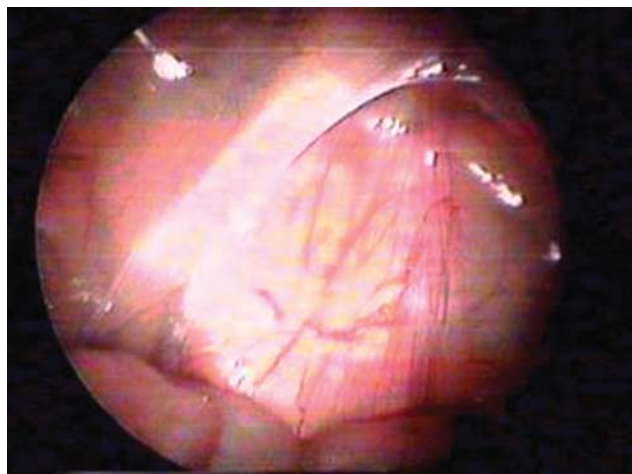
Vanishing testis.

there must be a remnant of testicular tissues that can be visualized at laparoscopic or open exploration.

True congenital absence of one testis is almost impossible in a phenotype male with no remnant of Müllerian structures. Cases that were initially diagnosed as absent testes in our series turned out to be related to a rare subset of an abdominal testis reported as no descent of the testis [10]. Testes were located at their initial embryological position below the kidneys, in contrast to the high abdominal testes that are present along the line of descent at a variable distance from the internal ring.

This entity was identified when, during diagnostic laparoscopy for impalpable testes, a leach of what resembled flimsy vessels were encountered entering an open internal ring, with no associated vas. The initial impression was that of an absent testis (Fig. 2). However, during the further inspection, a vas was found hidden under the large bowel and heading upwards subrenal testis. In 2008, we reported eight testes in seven patients found at the subrenal position: seven on the right side and one on the left. The latter belonged to a patient with bilateral UDT [10]. We have since encountered another four cases, all on the right side. The predominance of the right side for these particular cases is difficult to explain, and it is rather early to generalize or make conclusions. The etiology might be attributed to poorly developed or absent gubernaculum, which is known to be attached to the epididymis and plays an integral part in testicular descent. This is highlighted by the fact that the only trace of gubernacular tissues in these cases was a leach of vascular tissues along the course of testicular descent. There are two reports of subrenal testes with an initial

Fig. 2



Absent testis, initial finding.

laparoscopic finding very similar to our cases, but with the difference that they had no vas or epididymis [11,12].

## Conclusion

We do believe that testicular absence does not exist in normal males, and that cases that were labeled as an absent testes should be rescoped to exclude subrenal testes.

## Acknowledgements

### Conflicts of interest

There are no conflicts of interest.

## References

- 1 Husmann DA, Levy JB. Current concepts in the pathophysiology of testicular undescend. *Urology* 1995; **46**:267–276.
- 2 Shenker NS, Huynh J, Farmer PJ, Hutson JM. A new role for androgen in testicular descent: permitting gubernacular cell proliferation in response to the neuropeptide, calcitonin gene-related peptide. *J Pediatr Surg* 2006; **41**:407–412.
- 3 Hadziselimovic F, Herzog B, Buser M. Development of cryptorchid testes. *Eur J Pediatr* 1987; **146** (Suppl 2):S8–S12.
- 4 Marshall FF, Shermeta DW. Epididymal abnormalities associated with undescended testis. *J Urol* 1979; **121**:341–343.
- 5 Emanuel ER, Kirsch AJ, Thall EH, Hensle TW. Complete separation of the testis and epididymis. *J Pediatr Surg* 1997; **32**:754–755.
- 6 Wakeman D, Warner BW. Urogenital nonunion – a rare anomaly associated with the undescended testis. *Am J Surg* 2010; **199**:e59–e60.
- 7 El Gohary MA. Failure of fusion of epididymis and testis: a rare laparoscopic finding. *Eur J Pediatr Surg* 2009; **19**:108–109.
- 8 El-Gohary MA. The role of laparoscopy in the management of impalpable testes. *Pediatr Surg Int* 1997; **12**:463–465.
- 9 Smolko MJ, Kaplan GW, Brock WA. Location and fate of the nonpalpable testis in children. *J Urol* 1983; **129**:1204–1206.
- 10 El Gohary MA. Non-descent of the testis: an overlooked laparoscopic finding. *J Pediatr Urol* 2008; **4**:364–366.
- 11 Kim C, Bennett N, Docimo SG. Missed testis on laparoscopy despite blind-ending vessels and closed processus vaginalis. *Urology* 2005; **65**:1226.e7–1226.e8.
- 12 Sahin C, Kalkan M, Yalcinkaya S. Findings concerning testis, vas deference, and epididymis in adult Cases with nonpalpable testes. *Int Braz J Urol* 2011; **37**:727–732.