

# Ureteral triplication: need to see beyond the splitting of the ureteral bud

Kirtikumar J. Rathod, Dhananjay Vaze, Ravi Prakash Kanojia and Katragadda Lakshmi Narasimhanrao

Ureteral triplication is one of the rare anomalies of the urinary system. The following case describes management of child with triple system of right kidney with refluxing upper moiety ureter. It is not unusual to find such clinical presentations but the embryology with relevance to these malformations has been intriguing. The recent knowledge of the molecular mechanisms governing the process of ureteral budding and elongation raises some important questions. The current report discusses and hypothesizes the concept that certain family of molecules may be responsible for helping the ureteral bud to find its way to the respective

metanephros. *Ann Pediatr Surg* 8:95–98 © 2012 Annals of Pediatric Surgery.

*Annals of Pediatric Surgery* 2012, 8:95–98

**Keywords:** embryology of ureter, Robo2, Slit2, ureteral triplication, Weigert–Meyer law

Department of Pediatric Surgery, Advanced Pediatric Center and Post Graduate Institute of Medical Education and Research (PGIMER), Chandigarh, India

Correspondence to Kirtikumar J. Rathod, Department of Pediatric Surgery, Advanced Pediatric Center and Post Graduate Institute of Medical Education and Research (PGIMER), Chandigarh, India  
Tel: +91 921 651 3867; e-mail: drkirtirathod@gmail.com

Received 28 November 2011 accepted 10 May 2012

## Introduction

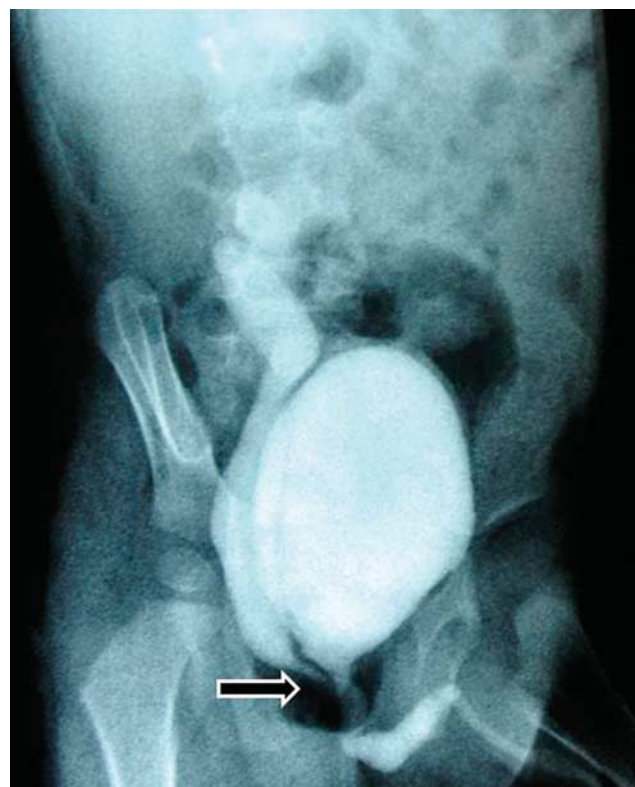Ureteral triplication is one of the rarest anomalies of the urinary system. It is a developmental abnormality of the ureteral bud originating from the Wolffian duct during the fifth week of embryological life [1,2]. The ureteral bud arises from the distal part of the Wolffian duct after 4 weeks of fetal development. It grows dorsally at first and cranially later, and makes contact with the metanephros; the distal end differentiates into the renal pelvis and the major and minor calyces during the sixth–eight weeks.

## Case report

A 2-year-old boy presented to the pediatric surgical outpatient department with a history of recurrent episodes of urinary tract infection since 6 months of age. Physical examination did not indicate any significant clinical finding. Ultrasonography indicated a duplicated collecting system right kidney with hydroureteronephrosis of the upper moiety. Micturating cystourethrogram was performed, which showed a grade 5 vesicoureteric reflux (VUR) with ectopic insertion of the dilated ureter in the posterior urethra (Fig. 1). Intravenous pyelography (IVU) was performed, which indicated triple moiety collecting system on the right side (Fig. 2). Middle and lower moieties were immediately delineated in the IVU and were of normal size and shape. The ureters draining the middle and the lower moiety were observed to be separate at the upper part, but joined immediately distal to the renal pelvis to form a single ureter. The upper moiety was delineated in delayed films and was grossly dilated. The left kidney and ureter were normal. A dynamic renal scan performed indicated a duplex system right kidney with hydronephrosis of the upper moiety. The perfusion and the cortical tracer uptake in the upper moiety were impaired and the drainage of the tracer from the upper moiety was also delayed. The right lower moiety and the left kidney showed good cortical tracer uptake and prompt drainage. The differential function of

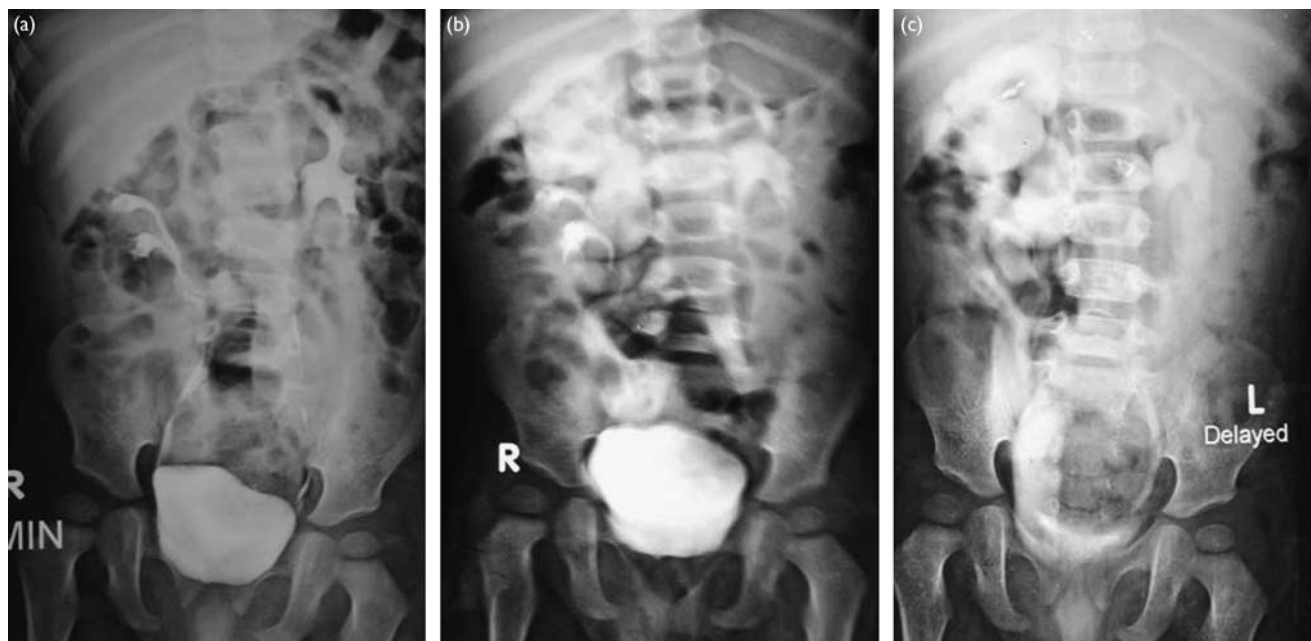
the right and left kidney was reported to be 55 and 45%, respectively, whereas the differential function of the right upper moiety was 33% and that of the right lower moiety was 67%. On the basis of the obvious IVU findings, a provisional diagnosis of a right kidney triplex system with grade 5 VUR of the upper moiety was made and the child was posted for right upper ureteral reimplantation. Two

Fig. 1



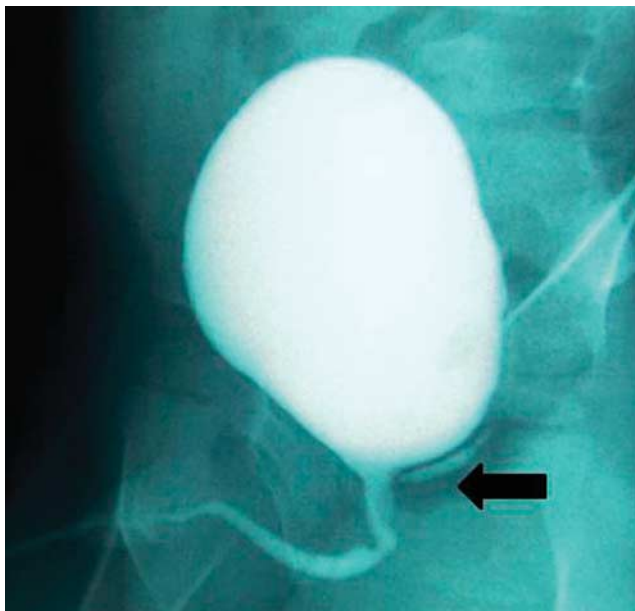
Voiding cystourethrogram showing the vesicoureteric reflux in an ectopically inserted ureter in the posterior urethra (arrow).

Fig. 2



Intravenous urography showing ureteric triplication with poorly functioning and hydronephrotic uppermost moiety. (a), 7 min film; (b), 30 min film; (c), 2 hr film.

Fig. 3



Postoperative voiding cystourethrogram showing the resolution of reflux with a residual ectopic ureter (black arrow).

ureters were seen on the right side; one was grossly dilated, tortuous, and was going behind the bladder and was probably opening in the posterior urethra. The second ureter on the right side was of normal caliber. On opening the bladder, only two normal, right and left, ureteric openings were observed in the trigone. The dilated tortuous

ureter was flush ligated till its visible end and was reimplanted on the same side in a Politano–Leadbetter manner. The child was discharged uneventfully on the 10th postoperative day. At 3 months of follow-up in the outpatient department, the child was asymptomatic. Ultrasonography abdomen performed showed a significant reduction in the size of the upper moiety as compared with the previous scan. Postoperative micturating cystourethrogram showed no VUR; however, some contrast was seen in the left over ureteral stump that was in communication with the posterior urethra (Fig. 3). Postoperative IVU showed good uptake of the dye by the upper moiety of the right kidney at 7 min, which became more prominent after 15 min of the study (Fig. 4). At present, the child is absolutely asymptomatic and has been advised a sixth-monthly follow-up.

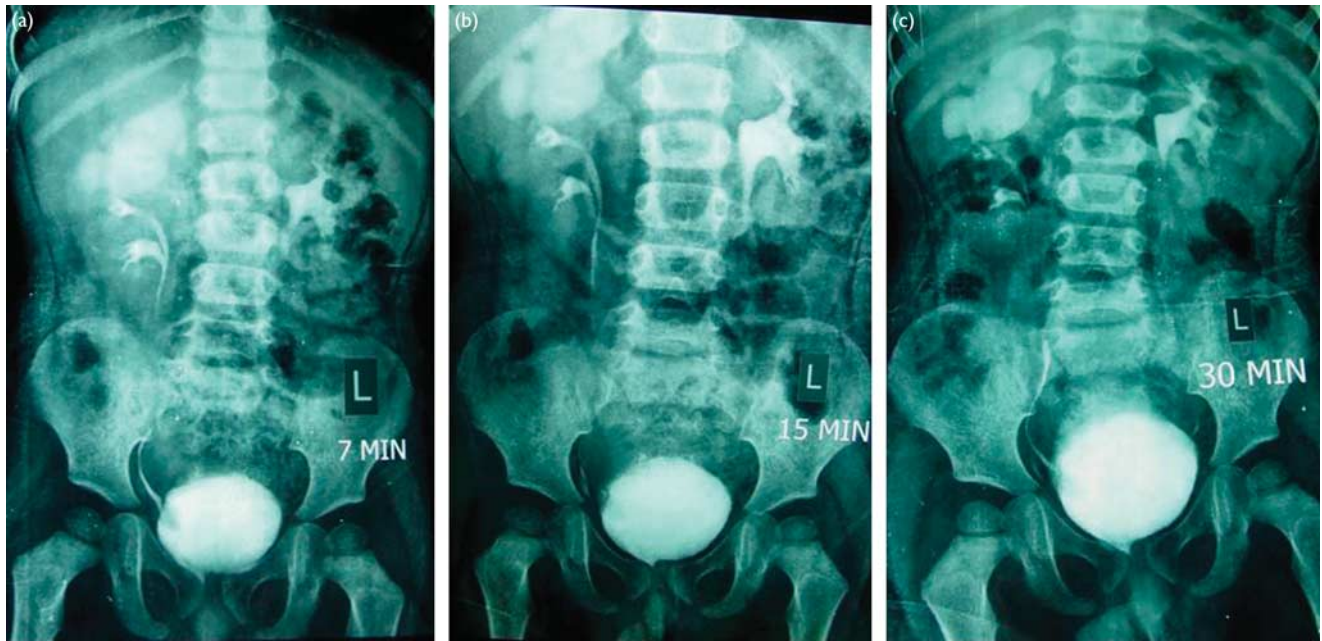
### Discussion

Ureteral budding is considered as a primary event in the formation of the renal unit. Renal development has been attributed to the induction of metanephric blastema. In triplication of the ureter, three ureteral buds could arise independently from the mesonephric duct or from early fission of one or more ureteral buds to join the metanephros [3–6].

Smith [7] described the classification of ureteral triplication back in the 1940s, and his classification of ureteral triplication has stood the test of time.

*Type I:* Complete ureteral triplication (35%); three separate ureters from the kidney with three separate draining orifices to the bladder or elsewhere in the urogenital tract.

Fig. 4



Postoperative intravenous urography showing improvement in upper moiety function. (a), 7 min film; (b), 30 min film; (c), 2 hr film.

*Type II:* Incomplete triPLICATION (21%); three ureters arise from the kidney, but two of these join, draining into two ureteric orifices.

*Type III:* Trifid ureter (31%); all three ureters join together before reaching the bladder and drain through a single orifice.

*Type IV:* Double ureter, one bifurcated (9%); two ureters arise from the kidney, one becoming an inverse Y bifurcation, draining into three orifices.

Our case represents an example of Smith type II ureteral triPLICATION. The uppermost moiety ureter was seen to open in the posterior urethra and the middle moiety ureter joined the lowermost moiety ureter to form a single stem that drained onto the trigone of the bladder. Thus, the anatomy was in accordance with the Weigert–Meyer law [8,9]. Although our case conformed with the Weigert–Meyer law, there are multiple instances in the literature of nonconformers of the Weigert–Meyer law [10]. No uniform explanation has been found for this phenomenon of nonconformation.

The embryological explanation provided for the phenomenon of ureteral triPLICATION is interesting. Smith type I can be explained on the basis of the formation of three distinct buds from the mesonephric duct. Smith type II can be attributed to late splitting of the ureteral bud before reaching the metanephros. Smith type III can be explained on the basis of tridenting of the ureteral bud before reaching the metanephros. No such splitting theory seems to explain Smith type IV. It is usually explained on the basis of fusion theory, according to which fusion of the ureteric buds leads to a single ureter in the proximal system [10]. If this fusion phenomenon is true, there is a certain point along the path of the two

ureteral buds that is common to both the buds (i.e. point of ‘cross-over’).

In Smith type I, it is notable that the course of the ureteral buds may not be the same in all the cases. The three ureteral buds may not cross at all or the two cranial buds cross before meeting the metanephros. In Smith type III also the course of the three ureters is not necessarily constant. It is the pattern of ureteral crossing that makes the anatomy peculiar, that is, if the ureteric orifices are labeled 1, 2, and 3 from the cranial to caudal direction on the trigone, ureter 1 generally meets the lowermost moiety. Ureters 2 and 3 meet the upper and the middle moiety, respectively. The perplexing question is why such an anatomy is deciphered. We attempted to find an explanation for this by understanding embryological phenomenon of ureteral crossing.

In humans, normally, a single ureteric bud arises from the mesonephric duct on each side. Occasionally, two ureteric buds develop, which would lead to ureteral duplication. It is important to note that the cranial bud induces the cranial part of metanephros and the caudal bud induces the caudal part. As the mesonephric duct undergoes exstrophy into the posterior wall of the bladder, the cranial bud is carried caudally along with the descending mesonephric duct to establish the eventual caudal position. This leads to crossing of the ureters, which is generally explained on the basis of mesonephric duct exstrophy [2]. This forms the basis of the ‘Weigert–Meyer Law’.

In the case of ureteric triPLICATION, the most caudal bud induces the caudalmost part of the metanephros but the cranialmost bud induces the middle and anterior parts of the metanephros. The middle bud can cross the cranial bud to induce the part of metanephros that is cranial

most. This crossing over of ureteric buds during the early embryonic period (before exstrophy of the mesonephric duct) may lead to a peculiar anatomy as described earlier. It has been considered as a matter of chance that the cranial and middle bud cross-over [10] but this seems to be a naïve idea and may not be just due to a chance. Our proposition in this context is that if ureteric buds cross over in a particular manner (i.e. opposite to the direction of cross-over caused by exstrophy of the mesonephric ducts), it will 'undo' the 'cross-over' and effectively the ureters shall lie without 'cross-over'.

These observations, when considered along with recent evidences of ureteral budding and induction of metanephros, raise a logical possibility of ureteral path finding. As the evidence gathers on the molecular mechanisms controlling axonal path finding, we believe the journey of ureteral bud is analogous to the process of axonal path finding. One of the similarities between the axon and the ureter is that ureters as well as axons do not generally cross the midline. Also, the observation that in the case of a triplication, the ureteral buds meet/induce the metanephros at different levels, not necessarily in a sequential manner, raises the possibility of a specific molecular orchestration of this process. We refer to this process as 'ureteral path finding'.

The role of Slit2/Robo2 in the molecular mechanisms of ureteral budding has been suggested from studies on Slit2/Robo2-deficient mice. Same molecules play a proven role in axonal path finding in invertebrates [11]. Slit2 is a secreted protein expressed by cells at the ventral midline of the nervous system, and it causes repulsion in axon guidance and neuronal migration [12,13]. The Slit receptors Robo2 and Robo3 ensure the accuracy of axonal crossing [14] and, thus, these molecules may play a similar role in tracing the path of the ureters to the respective metanephros.

Recently, a study has shown that ablation of the notochord/floor plate and specific inactivation of Shh in these structures causes kidney fusion, but not agenesis [15]. The investigators argue that loss of the axial signals, because of cell ablation or gene inactivation, results in signaling interruptions and developmental alterations in midline cell populations. A conceptual 'midline barrier' during normal development may help to prevent fusion of the kidneys. Such a barrier may consist of midline mesoderm forming a physical separation and/or repulsive signals originating from these midline cells. Thus, in a way, the effects of midline signals from axial structures, especially the notochord and the floor plate, on metanephric kidney development appear to maintain an

effective 'midline barrier' and help to determine the final mediolateral position of the kidneys. This 'midline barrier' may prevent ureters from crossing over to the other side and may thus induce same-side metanephros. It might be very interesting to speculate that the ureteric bud that tries to cross the midline is prevented from doing so by the 'midline barrier' and thus arrives at the ipsilateral metanephros slightly late. It may follow a different trajectory because of this delay.

Although we do not wish to make any further assertions without corroborative evidence, we would like to highlight these similarities. It is hoped that positive evidence in relation to this concept will help us understand these ureteral anomalies. It may also provide a better explanation as to why the Weigert-Meyer law is violated in certain instances.

## Acknowledgements

### Conflicts of interest

There are no conflicts of interest.

## References

- 1 Ander H, Ziyilan O, Çayan S, Kadioğlu TC, Beşişik A. A case of ureteral triplication (type 1) associated with vesicoureteral reflux in a solitary kidney. *Int Urol Nephrol* 1997; **29**:537-540.
- 2 Schoenwolf GC, Bleyl SB, Brauer PR, Francis West PH. Development of urogenital system. In: Schoenwolf GC, Bleyl SB, Brauer PR, Francis West PH, editors. *Larsen's human embryology*. 4th ed. Philadelphia: Churchill Livingstone. 2009. pp. 479-541.
- 3 Engelstein D, Livne PM, Cohen M, Servadio C. Type II ureteral triplication associated with ectopic ureter. *Urology* 1996; **48**:786-788.
- 4 Hassan MA. Ureteral triplication (type I) with vesicoureteral reflux. *Urology* 1990; **35**:78-80.
- 5 Sanchez de Badajoz E, Ramos J, Burgos R. Ureteral triplication with contralateral ureter duplication. *Urol Int* 1992; **48**:217-218.
- 6 Singh G, Murray K. Ureteral triplication, occasionally an isolated anomaly. *Urol Int* 1996; **56**:117-118.
- 7 Smith I. Triplicate ureter. *Br J Surg* 1946; **34**:182-185.
- 8 Meyer R. Normal and abnormal development of the ureter in the human embryo; a mechanistic consideration. *Anat Rec* 1946; **96**:355-471.
- 9 Weigert C. Über einige Bildungsfehler der Ureteren. *Virch Arch* 1877; **70**:490.
- 10 Stephens FD, Smith ED, Hutson J. Triplicate and quadruplicate ureters. In: Stephens FD, Smith ED, Hutson J, editors. *Congenital anomalies of the kidney, urinary and genital tracts*. 2nd ed. Informa Healthcare; 2002. pp. 263-274.
- 11 Araujo SJ, Tear G. Axon guidance mechanisms and molecules: lessons from invertebrates. *Nat Rev Neurosci* 2003; **4**:910-922.
- 12 Bagri A, Marin O, Plump AS, Mak J, Pleasure SJ, Rubenstein JLR, et al. Slit proteins prevent midline crossing and determine the dorsoventral position of major axonal pathways in the mammalian forebrain. *Neuron* 2002; **33**:233-248.
- 13 Brose K, Bland KS, Kuan HW, Arnott D, Henzel W, Goodman CS, et al. Slit proteins bind Robo receptors and have an evolutionarily conserved role in repulsive axon guidance. *Cell* 1999; **96**:795-806.
- 14 Rajagopalan S, Nicolas E, Vivancos V, Berger J, Dickson BJ. Crossing the midline: roles and regulation of Robo receptors. *Neuron* 2000; **28**:767-777.
- 15 Tripathi P, Guo Q, Wang Y, Coussens M, Liapis H, Jain S, et al. Midline signaling regulates kidney positioning but not nephrogenesis through Shh. *Dev Biol* 2010; **340**:518-527.